Academic Research of
Graduate School of Veterinary Medicine

January – December
2021



Graduate School of Veterinary Medicine

Rakuno Gakuen University

RAKUNO GAKUEN UNIVERSITY
酪農学園大学

Japan Institution for Higher Education Evaluation
JIHEE
since 2004
III
UNIVERSITY
2020.4-2027.3

2021年（1月～12月）の獣医学研究科英文業績集の発刊にあたって

酪農学園大学大学院
獣医学研究科長
桐澤　力雄

獣医学研究科では獣医学群教員が 1 年間に公表した英語論文を冊子体にまとめ、各教員の自己点検や研究の質保証、並びに関係各位に獣医学群教員の研究状況を紹介する目的で、2002年より業績集を刊行しています。

2021年の筆頭著者（FA）及び責任著者（CA）の論文合計は83報でした。過去5年間では、2016年：45報、2017年：48報、2018年：54報、2019年：54報、2020年：72報となっており、昨年より約10報増えました。近5年間にFA/CA論文のない教員が8名いました（教授：1名、准教授：4名、講師：3名）。代表的な競争的資金である科研費の学群教員の申請状況をみると、2017年度：38名、2018年度：34名、2019年度：36名、2020年度：40名、2021年度：43名、そして2022年度：51名でした。2022年度の申請率は応募可能な学群教員が57名でしたので約89%（昨年は約83%、一昨年約74%）となり、もう少しで100%というところまで来ました。この申請率は大学の研究基盤を映す鏡の一つですので、研究意識のレベルが相当向上してきているものと考えています。しかし、大学において、研究に必要な高額機器・備品の更新や投資がほとんどなされていない現状を見ると、今後の研究の進展が憂慮されます。

科学技術指標2021によると自然科学系の科学論文数（2017 - 2019年平均）の順位は昨年と同様、中国、アメリカ、ドイツ、そして日本となっております。日本は10年前が3位で論文シェアは6.3 %ありましたが、今回はシェアが4.1%に低下しています。Top10%補正論文数も10年前の5位から10位に後退しています（昨年は9位）。シェアも10年前の4.3%から2.3%に低下し、わが国の長期にわたる凋落傾向が読み取れます。その一方で、中国は論文数とシェアでともに米国を上回り第1位となりました。

第6期科学技術・イノベーション基本計画（2021年3月26日、閣議決定）ではSociety 5.0の実現に向けた科学技術・イノベーション政策が示され、その項目の一つとして「知のフロンティアを開拓し価値創造の源泉となる研究力の強化（大目標：多様性や卓越性を持った「知」を創出し続ける、世界最高水準の研究力を取り戻す」が挙げられており、その施策実現が期待されるところです。

2021年度の獣医学専攻博士課程の修学者総数は30 名（社会人大学院生：9名、外国人：6名［中国：2名、台湾：1名、カンボジア：1名、タイ：1名、南アフリカ：1名］）で、今年度の修了認定者は9名です。早期修了生が2名（半期短縮と1年短縮各1名）おり、いずれも日本学術振興会特別研究員DC1採用学生です。獣医保健看護学専攻修士課程の修学者総数は 2 名で、今年度の修了認定者はおりません。今年度も大学院博士課程に第一種

奨学生採用時返還免除内定候補者枠が、3 年連続で 1 名付与されました。これは、獣医学研究科の外部評価が高いことを意味しています。

2019 年度から始動した「One Health フロンティア卓越大学院」には、獣医学研究科から 2 年生 2 名と 3 年生 1 名が登録・履修しています。卓越大学院予算で一昨年導入した遠隔システム（Webex）は、質の高い授業の双方向の受講や WEB 開催の学会主宰を可能とし、教育・研究の高度化がなされています。

最後に関係各位には本業績集をご高覧いただき、教員個々の研究内容などから共同研究、さらには広範な研究体制の構築等へとご高配いただけることを願っております。今後とも、獣医学研究科の教育・研究活動がさらに発展するよう、ご指導ご鞭撻をよろしくお願い申し上げます。

Contents (January – December 2021)

■ 獣医学類 Department of Veterinary Medicine

浅川　満彦　教授（Prof. Mitsuhiko Asakawa）（Parasitology and Zoology）……1
岩野　英知　教授（Prof. Hidetomo Iwano）（Veterinary Biochemistry）……9
上野　博史　教授（Prof. Hiroshi Ueno）（Companion Animal Surgery）
内田　郁夫　教授（Prof. Ikuo Uchida）（Veterinary Bacteriology）……17
遠藤　大二　教授（Prof. Daiji Endoh）（Veterinary Basic Radiology）……21
及川　伸　教授（Prof. Shin Oikawa）（Veterinary Herd Health）……27
大杉　剛生　教授（Prof. Takeo Ohsugi）（Laboratory Animal Science）
大塚　浩通　教授（Assoc. Prof. Hiromichi Ohtsuka）
（Farm Animal Pathophysiology）……33
翁長　武紀　教授（Prof. Takenori Onaga）（Veterinary Physiology）……37
加藤　敏英　教授（Prof. Toshihide Kato）（Farm Animal Surgery）……41
北村　浩　教授（Prof. Hiroshi Kitamura）（Veterinary Physiology）……45
桐澤　力雄　教授（Prof. Rikio Kirisawa）（Veterinary Virology）……49
鈴木　一由　教授（Prof. Kazuyuki Suzuki）（Veterinary Clinicopathology）……53
田島　誉士　教授（Prof. Motoshi Tajima）（Farm Animal Internal Medicine）……63
寺岡　宏樹　教授（Prof. Hiroki Teraoka）（Veterinary Pharmacology）……67
鳥巣　至道　教授（Prof. Shido Torisu）（Companion Animal Surgery）
中田　健　教授（Prof. Ken Nakada）（Theriogenology）……75
中出　哲也　教授（Prof. Tetsuya Nakade）（Veterinary Diagnostic Imaging）……79
萩原　克郎　教授（Prof. Katsuro Hagiwara）（Veterinary Virology）……83
樋口　豪紀　教授（Prof. Hidetoshi Higuchi）（Animal Health）……93
蒔田　浩平　教授（Prof. Kohei Makita）（Veterinary Epidemiology）……101
松田　一哉　教授（Prof. Kazuya Matsuda）（Veterinary Pathology）……111
村松　康和　教授（Prof. Yasukazu Muramatsu）（Zoonotic Diseases）……119
山下　和人　教授（Prof. Kazuto Yamashita）（Veterinary Anesthesiology）……125

安藤　達哉　准教授（Assoc. Prof. Tatsuya Andoh）
（Farm Animal Internal Medicine）……131
井坂　光宏　准教授（Assoc. Prof. Mitsuhiro Isaka）（Companion Animal Surgery）135
伊丹　貴晴　准教授（Assoc. Prof. Takaharu Itami）（Veterinary Anesthesiology）……145
植田　弘美　准教授（Assoc. Prof. Hiromi Ueda）（Veterinary Anatomy）……151
臼井　優　准教授（Assoc. Prof. Masaru Usui）
（Food Microbiology and Food Safety）……157
大田　寛　准教授（Assoc. Prof. Hiroshi Ohta）
（Companion Animal Internal Medicine）……175
岡本　実　准教授（Assoc. Prof. Minoru Okamoto）（Veterinary Clinicopathology）

川本　哲　准教授（Assoc. Prof. Satoshi Kawamoto）
（Farm Animal Internal Medicine）
佐野　忠士　准教授（Assoc. Prof. Tadashi Sano）（Veterinary Anesthesiology）……185
平田　晴之　准教授（Assoc. Prof. Haruyuki Hirata）（Veterinary Clinicopathology）191
福森　理加　准教授（Assoc. Prof. Rika Fukumori）（Veterinary Herd Health）……195
安井　由美子　准教授（Assoc. Prof. Yumiko Yasui）（Veterinary Physiology）
山﨑　裕毅　准教授（Assoc. Prof. Hiroki Yamazaki）
（Companion Animal Internal Medicine）·201
渡邉　敬文　准教授（Assoc. Prof. Takafumi Watanabe）（Veterinary Anatomy）……211

内田　玲麻　講師（Lecturer Leo Uchida）(Zoonotic Diseases)……219
権平　智　講師（Asst. Prof. Satoshi Gondaira）（Animal Health）……225
佐野　悠人　講師（Lecturer Yuto Sano）（Veterinary Pathology）……233
華園　究　講師（Lecturer Kiwamu Hanazono）（Veterinary Diagnostic Imaging）239
福田　昭　講師（Lecturer Akira Fukuda）（Food Microbiology and Food Safety）·245
三好　健二郎　講師（Lecturer Kenjirou Miyoshi）（Veterinary Anesthesiology）……255
藤木　純平　講師（Lecturer Jumpei Fujiki）（Veterinary Biochemistry）……261
村田　亮　講師（Lecturer Ryo Murata）（Veterinary Bacteriology）……269

加藤　桂子　助教（Asst. Prof. Keiko Kato）（Veterinary Anesthesiology）……273
小千田　圭吾　助教（Asst. Prof. Keigo Kosenda）（Farm Animal Pathophysiology）
酒井　俊和　助教（Asst. Prof. Toshikazu Sakai）（Companion Animal Surgery）……277
佐藤　綾乃　助教（Asst. Prof. Ayano Sato）(Farm Animal Surgery)……281
杉浦　智親　助教（Asst. Prof. Tomochika Sugiura）（Theriogenology）……287
田村　昌大　助教（Asst. Prof. Masahiro Tamura）
（Companion Animal Internal Medicine）·291
細谷　実里奈　助教（Asst. Prof. Marina Hosotani）（Veterinary Anatomy）……301
堀　あい　助教（Asst. Prof. Ai Hori）（Veterinary Diagnostic Imaging）……305
守屋　大樹　助教（Asst. Prof. Daiki Moriya）（Veterinary Physiology）……309

■ **獣医保健看護学類　Department of Veterinary Science**

川添　敏弘　　教授（Prof. Toshihiro Kawazoe）（Animal Human Relations）

北澤　多喜雄　教授（Prof. Takio Kitazawa）（Animal Life Science）……315

菅野　美樹夫　教授（Prof. Mikio Sugano）（Animal Clinical Science）

林　　英明　　教授（Prof. Hideaki Hayashi）（Animal Life Science）……325

郡山　尚紀　　准教授（Assoc. Prof. Takanori Kooriyama）
（Animal Human Relations）…331

高橋　優子　　准教授（Assoc. Prof. Yuko Takahashi）（Animal Human Relations）

椿下　早絵　　准教授（Assoc. Prof. Sae Tsubakishita）（Animal Clinical Science）…341

能田　淳　　准教授（Assoc. Prof. Jun Noda）（Animal Human Relations）……345

宮庄　拓　　講師（Lecturer Taku Miyasho）（Animal Life Science）……351

八百坂　紀子　講師（Lecturer Noriko Yaosaka）（Animal Clinical Science）

医動物学（Parasitology and Zoology）

Mitsuhiko Asakawa

Professor

教授　浅川　満彦

Ⅰ．筆頭または責任著者　＜First or Corresponding Author＞

1）*Clistobothrium* sp. (Cestoda: Tetraphylidea) in oarfish (*Regalecus russelii*) stranded on the coast of Akita Prefecture, Japan.
Hirata H., Mibe Y., Ono K., Shizuno S., Suzuki K., **Asakawa M.**
J. Vet. Med. Sci. **83**: 1590-1592. 2021. doi: 10.1292/jvms.21-0317.

2）First record of chewing lice *Brueelia pyrrhularum* Eichler, 1954 (Ischnocera: Philopteridae) on a Eurasian bullfinch, *Pyrrhula pyrrhula* L in Kushiro, Hokkaido, Japan.
Yoshino, T., **Asakawa, M.**
Biogeography, **23**: 22-24. 2021. https://doi.org/10.11358/biogeo.23.22

3）A sucking louse（Insecta, Anoplura）from captive Senegal bushbaby, *Galago senegalensis,* kept in an aquarium in Japan.
Hayashi M, Aoyama A, Suzuki H, Yoshimoto Y, Inagaki K, **Asakawa M.**
Jpn. J. Vet. Parasitol., **19**: 135-137. 2021.
https://drive.google.com/file/d/1s4gYF86rp7NjznEql8OVRHoimOQAOVlp/view

4）Temporal change in the parasite fauna of the large Japanese field mouse *Apodemus speciosus* in the radioactive contaminated zone of Fukushima.
Kakiuchi, K., **Asakawa, M.**, Ishiniwa, H., Tamaoki, M. and Onuma, M.
Jpn. J. Zoo Wildl Med., **26**: 1-5. 2021.
https://www.jstage.jst.go.jp/article/jjzwm/26/1/26_1/_pdf

Ⅱ．その他＜Others＞

1）*Notocotylus ikutai* n. sp. (Digenea: Notocotylidae) from lymnaeid snails and anatid birds in Hokkaido, Japan,
Sasaki, M., Kobayashi, M., Yoshino, T., **Asakawa, M.,** Nakao, M.
Parasitol. Int., **83**: 102318. 2021. doi.org/10.1016/j.parint.2021.102318

The Journal of Veterinary Medical Science

NOTE

Wildlife Science

Clistobothrium sp. (Cestoda: Tetraphyllidea) in oarfish (*Regalecus russelii*) stranded on the coast of Akita Prefecture, Japan

Haruyuki HIRATA[1)], Yuki MIBE[1)], Koji ONO[2)], Satsuki SHIZUNO[2)], Kazuyuki SUZUKI[1)] and Mitsuhiko ASAKAWA[1)]*

[1)]School of Veterinary Medicine, Rakuno Gakuen University, Hokkaido 069-8501, Japan
[2)]Oga Aquarium GAO, Akita 010-0673, Japan

J. Vet. Med. Sci.
83(10): 1590–1592, 2021
doi: 10.1292/jvms.21-0317

Received: 3 June 2021
Accepted: 17 August 2021
Advanced Epub:
2 September 2021

ABSTRACT. Oarfish (*Regalecus russelii* Cuvier) are mesopelagic fish with little known about their life history. Oarfish live in deep water, making it difficult for researchers to collect specimens; thus, records of their parasitic helminths are limited. Two plerocercoids were found for the first time in an oarfish stranded on the coast of Akita Prefecture, Japan. These plerocercoids were identified as *Clistobothrium* sp. RR-1 using morphological and molecular analyses. It was revealed that oarfish represent one of the intermediate hosts of the genus *Clistobothrium*, and large sharks are the definitive hosts for these parasites.

KEY WORDS: deep-sea fish, first record, oarfish, phylogenetic analysis, plerocercoid

出典　doi: 10.1292/jvms.21-0317
https://www.jstage.jst.go.jp/article/jvms/83/10/83_21-0317/_article
最終責任者　Mitsuhiko Asakawa (Corresponding Author)

Biogeography 23:
22–24. Sep. 20, 2021

First record of chewing lice *Brueelia pyrrhularum* Eichler, 1954 (Ischnocera: Philopteridae) on an Eurasian bullfinch, *Pyrrhula pyrrhula* L in Kushiro, Hokkaido, Japan

Tomoo Yoshino[1,2] and Mitsuhiko Asakawa[2*]

[1] Kushiro Zoo, Kushiro, Hokkaido 085-0201, Japan
[2] School of Veterinary Medicine, Rakuno Gakuen University, Ebetsu, Hokkaido 069-8501, Japan

Abstract: A deceased male adult Eurasian bullfinch, *Pyrrhula pyrrhula*, was collected in March 2017 from Kushiro Natural Red-crowned Crane Reserve, Kushiro, Hokkaido, Japan. In the post-mortem examination, three adult chewing lice were obtained from the body surface. The present specimens were identified as *Brueelia pyrrhularum* Eichler, 1954 by morphological measurements and characteristics. This is the first record of *B. pyrrhularum* from Japan.

Key words: first geographical record in Japan, chewing lice, *Pyrrhula pyrrhula*

出典　doi: https://doi.org/10.11358/biogeo.23.22
最終責任者　Mitsuhiko Asakawa (Corresponding Author)

A sucking louse (Insecta, Anoplura) from captive Senegal bushbaby, *Galago senegalensis*, kept in an aquarium in Japan

Miho HAYASHI[1)], Asuka AOYAMA[2)], Hiroko SUZUKI[2)], Yuichi YOSHIMOTO[2)], Kurumi INAGAKI[2)], Mitsuhiko ASAKAWA[1)]*

[1)] Division of Pathobiology (Parasitology and Zoology), School of Veterinary Medicine, Rakuno Gakuen University, Ebetsu, Hokkaido, Japan

[2)] KAWASUI Kawasaki Aquarium, Kawasaki, Kanagawa, Japan

ABSTRACT. A larva of a sucking louse was obtained from the dorsal side of captive Senegal bushbaby, *Galago senegalensis*, kept in an aquarium in Kanagawa Pref., Japan. It is the first local record of the anoplura from the bushbaby was born and kept in Japan.

KEY WORDS : *Galago senegalensis* sucking louse, Japan

出典　https://drive.google.com/file/d/1s4gYF86rp7NjznEql8OVRHoimOQAOVIp/view

最終責任者　Mitsuhiko Asakawa (Corresponding Author)

Research note Parasitology

Temporal Changes in the Parasite Fauna of the Large Japanese Field Mouse *Apodemus speciosus* in the Radioactive Contaminated Zone of Fukushima

Kyoka KAKIUCHI[1)#], Mitsuhiko ASAKAWA[1)#], Hiroko ISHINIWA[2)], Masanori TAMAOKI[3)] and Manabu ONUMA[1, 4)*]

1) School of Veterinary Medicine, Rakuno Gakuen University, Ebetsu, Hokkaido 069-8501, Japan
2) Institute of Environmental Radioactivity, Fukushima University, 1 Kanayagawa, Fukushima City, Fukushima, 960-1296, Japan
3) Environmental Impact Assessment Section, Fukushima Branch, National Institute for Environmental Studies, 10-2, Fukasaku, Miharu, Fukushima 963-7700, Japan
4) Ecological Risk Assessment and Control Section, Center for Environmental Biology and Ecosystem Studies, National Institute for Environmental Studies, 16-2 Onogawa, Tsukuba, Ibaraki 305-8506, Japan

[Received 2 August 2020; accepted 29 November 2020]

ABSTRACT

We assessed the temporal changes in the parasite fauna of the large Japanese field mouse *Apodemus speciosus*, which served as a model to evaluate the biological effects of radioactive materials released upon the Fukushima Daiichi Nuclear Power Plant accident. Parasites were collected from 30 mice trapped before (1992) and after (2012 and 2014) the accident. Five species of parasites were identified; among these, *Heterakis spumosa* (Nematoda) was detected only before the accident and *Raillietina coreensis* (Cestoda) was detected only after the accident. This phenomenon may reflect accident-induced environmental changes affecting the abundance of paratenic and intermediate parasitic hosts. Regarding morphology, no malformations were observed in any of the isolated parasites.

Key words: *Apodemus speciosus*, Fukushima Daiichi Nuclear Power Plant, parasitic fauna

Jpn J Zoo Wildl Med 26(1) : 1-5, 2021

The Great East Japan Earthquake occurred at 14:46 JST on March 11, 2011. The resulting tsunami devastated the coast of Honshu. Consequently, the interruption in the power supply at the Fukushima Daiichi Nuclear Power Plant (FDNPP) disabled the reactor cooling systems. The resultant overheating compromised the reactor containment vessel, releasing a large amount of radioactive materials into the surrounding environment.

To evaluate the impact of radioactive materials on the local ecosystem, we assessed the temporal changes in the parasite fauna of the large Japanese field mouse, *Apodemus speciosus*. The species meet the criteria of reference animals for assessing the impact of radiation on wildlife as designated by the International Commission on Radiological Protection (ICRP) [1], and extensive information on its ecology, morphology, and parasite fauna is available. In addition, species that develop directly (egg infection) and species that develop indirectly (require intermediate or paratenic hosts) are known among parasites [2]. Thus, even though parasites are not designated as reference animals by the ICRP [1], temporal changes in the parasite fauna of *A. speciosus* before and after the accident might be one of the indicators of the effect of radiation on the various elements that make up the food web in the area contaminated with radioactive substances.

As the number of captured females was lesser than that of males and the reproduction status of female individuals varied (e.g. level of maturity, pregnancy or non-pregnancy, lactation or non-lactation), males with testicular descent were used to isolate parasites to minimize the effect of the reproductive cycle. In this study, 20 male mice (10 captured in 2012 and 10 in 2014) were used as specimens affected by radioactive materials. The capture site was in the area contaminated with

* Corresponding author : Manabu ONUMA
(*E-mail*: monuma@nies.go.jp)
# These authors contributed equally to the work.

emus speciosus in the Radioactive Contaminated Zone of F

Kyoka KAKIUCHI[1)#], Mitsuhiko ASAKAWA[1)#], Hiroko ISHINIWA[2)], Masanori TAMAOKI[3)] and Manabu ONUMA[1, 4)*]

the impact of radiation on wildlife as designated by the International Commission on Radiological Protection (ICRP)

(e.g. lev
or non-
isolate
cycle. In
10 in 2
materia

* Corresponding author : Manabu ONUMA
(*E-mail*: monuma@nies.go.jp)
# These authors contributed equally to the work.

出典 https://www.jstage.jst.go.jp/article/jjzwm/26/1/26_1/_pdf

共同筆頭著者　Mitsuhiko Asakawa (Co-first Author)

Parasitology International 83 (2021) 102318

Contents lists available at ScienceDirect

Parasitology International

journal homepage: www.elsevier.com/locate/parint

Notocotylus ikutai n. sp. (Digenea: Notocotylidae) from lymnaeid snails and anatid birds in Hokkaido, Japan

Mizuki Sasaki [a,*], Mari Kobayashi [b], Tomoo Yoshino [c], Mitsuhiko Asakawa [d], Minoru Nakao [a]

[a] Department of Parasitology, Asahikawa Medical University, Asahikawa, Hokkaido 078-8510, Japan
[b] Department of Aqua-Bioscience and Industry, Faculty of Bioindustry, Tokyo University of Agriculture, Abashiri, Hokkaido 099-2493, Japan
[c] Kushiro Zoo, Kushiro, Hokkaido 085-0201, Japan
[d] School of Veterinary Medicine, Rakuno Gakuen University, Ebetsu, Hokkaido 069-8501, Japan

ARTICLE INFO

Keywords:
Notocotylus ikutai n. sp.
Radix auricularia
Anatid birds
Hokkaido

ABSTRACT

An unknown species of the genus *Notocotylus* (Digenea: Notocotylidae) was found as the larval stage from the lymnaeid snail, *Radix auricularia*, in a static water area of the Chubetsu River, Hokkaido, the northernmost island of Japan. A DNA barcoding identification system was applied to detect the adult stage. Through the inspection of anatid game birds in Hokkaido, *Anas crecca*, *Anas platyrhynchos*, *Anas zonorhyncha*, and *Mareca penelope* were demonstrated to serve as the definitive hosts. The detailed morphological features of the species were characterized using adults raised experimentally in immunosuppressed mice and naturally developed larvae in *R. auricularia*. Although the species is morphologically similar to *Notocotylus attenuatus* and *Notocotylus magniovatus* in both adult and larval stages, its taxonomic independence was confirmed by a comprehensive study based on molecular phylogeny, morphology, and ecology. Here we propose *Notocotylus ikutai* n. sp. for this species. The migratory behavior of the anatid hosts and the North-Eurasian distribution of *R. auricularia* suggest that the new species is widely distributed in the northern Far East.

出典：doi.org/10.1016/j.parint.2021.102318
https://www.sciencedirect.com/science/article/abs/pii/S1383576921000374?via%3Dihub

最終責任者　Minoru Nakao　(Corresponding Author)

獣医生化学（Veterinary Biochemistry）

Hidetomo　Iwano

Professor

教授　岩野　英知

Ⅰ．筆頭または責任著者　＜First or Corresponding Author＞

1) Novel Virulent Bacteriophage ΦSG005, Which Infects *Streptococcus gordonii*, Forms a Distinct Clade among Streptococcus Viruses.
Fujiki J, Yoshida SI, Nakamura T, Nakamura K, Amano Y, Nishida K, Nishi K, Sasaki M, Iwasaki T, Sawa H, Komatsuzawa H, Hijioka H, **Iwano H**.
Viruses. 2021 Sep 29;13(10):1964. doi: 10.3390/v13101964.

Ⅱ．その他＜Others＞

1) Fluctuating Bacteriophage-induced galU Deficiency Region is Involved in Trade-off Effects on the Phage and Fluoroquinolone Sensitivity in Pseudomonas aeruginosa.
Nakamura K, Fujiki J, Nakamura T, Furusawa T, Gondaira S, Usui M, Higuchi H, Tamura Y, **Iwano H.**
Virus Res. 2021 Dec;306:198596. doi: 10.1016/j.virusres.2021.198596.

2) Complete Genome Sequence of a Veterinary Pseudomonas aeruginosa Isolate, Pa12.
Nakamura K, Fujiki J, Furusawa T, Nakamura T, Gondaira S, Sasaki M, Usui M, Higuchi H, Sawa H, Tamura Y, **Iwano H**.
Microbiol Resour Announc. 2021 Jul;10(26):e0039821. doi: 10.1128/MRA.00398-21.

3) Innate immune response in bovine neutrophils stimulated with Mycoplasma bovis.
Gondaira S, Nishi K, Fujiki J, **Iwano H**, Watanabe R, Eguchi A, Hirano Y, Higuchi H, Nagahata H.Vet Res. 2021 Apr 16;52(1):58. doi: 10.1186/s13567-021-00920-2.

4) Immune response during the onset of coliform mastitis in dairy cows vaccinated with STARTVAC®.

Kazuhiro Kawai, Yasuha Kondo, Yasunori Shinozuka, Ryusaku Kawata, Sohei Kaneko, **Hidetomo Iwano**, Masafumi Enokidani, Aiko Watanabe, Fika Yuliza-Purba, Naoki Isobe, Tomomi Kurumisawa. Animal Science Journal 2021 Jan 5. 92, Issue 1, e13502. doi: https://doi.org/10.1111/asj.13502.

viruses

MDPI

Article

Novel Virulent Bacteriophage ΦSG005, Which Infects *Streptococcus gordonii*, Forms a Distinct Clade among Streptococcus Viruses

Jumpei Fujiki [1], Shin-ichi Yoshida [1], Tomohiro Nakamura [1], Keisuke Nakamura [1], Yurika Amano [1], Keita Nishida [1], Keitaro Nishi [2], Michihito Sasaki [3], Tomohito Iwasaki [4], Hirofumi Sawa [3,5,6], Hitoshi Komatsuzawa [7], Hiroshi Hijioka [2] and Hidetomo Iwano [1,*]

1 Laboratory of Veterinary Biochemistry, Department of Veterinary Medicine, Rakuno Gakuen University, Ebetsu 069-8501, Japan; j-fujiki@rakuno.ac.jp (J.F.); Shinichi.Yoshida@kaneka.co.jp (S.-i.Y.); s21941005@stu.rakuno.ac.jp (T.N.); s21661158@stu.rakuno.ac.jp (K.N.); s21661157@stu.rakuno.ac.jp (Y.A.); nk.0418trbr@gmail.com (K.N.)
2 Department of Maxillofacial Diagnostic and Surgical Science, Field of Oral and Maxillofacial Rehabilitation, Graduate School of Medical and Dental Sciences, Kagoshima University, Kagoshima 890-8544, Japan; nsktr.248@gmail.com (K.N.); zio@dent.kagoshima-u.ac.jp (H.H.)
3 Division of Molecular Pathobiology, International Institute for Zoonosis Control, Hokkaido University, Sapporo 001-0020, Japan; m-sasaki@czc.hokudai.ac.jp (M.S.); h-sawa@czc.hokudai.ac.jp (H.S.)
4 Department of Food Science and Human Wellness, College of Agriculture, Food and Environment Science, Rakuno Gakuen University, Ebetsu 069-8501, Japan; iwasaki@rakuno.ac.jp
5 International Collaboration Unit, International Institute for Zoonosis Control, Hokkaido University, Sapporo 001-0020, Japan
6 One Health Research Center, Hokkaido University, Sapporo 001-0020, Japan
7 Department of Bacteriology, Graduate School of Biomedical and Health Sciences, Hiroshima University, Hiroshima 734-8553, Japan; komatsuz@hiroshima-u.ac.jp
* Correspondence: h-iwano@rakuno.ac.jp; Tel./Fax: +81-11-388-4885

check for updates

Citation: Fujiki, J.; Yoshida, S.-i.; Nakamura, T.; Nakamura, K.; Amano, Y.; Nishida, K.; Nishi, K.; Sasaki, M.; Iwasaki, T.; Sawa, H.; et al. Novel Virulent Bacteriophage ΦSG005, Which Infects *Streptococcus gordonii*, Forms a Distinct Clade among Streptococcus Viruses. *Viruses* **2021**, *13*, 1964. https://doi.org/10.3390/v13101964

Academic Editor: Terje Dokland

Received: 7 August 2021
Accepted: 25 September 2021
Published: 29 September 2021

Publisher's Note: MDPI stays neutral with regard to jurisdictional claims in published maps and institutional affiliations.

Copyright: © 2021 by the authors. Licensee MDPI, Basel, Switzerland. This article is an open access article distributed under the terms and conditions of the Creative Commons Attribution (CC BY) license (https://creativecommons.org/licenses/by/4.0/).

Abstract: Bacteriophages are viruses that specifically infect bacteria and are classified as either virulent phages or temperate phages. Despite virulent phages being promising antimicrobial agents due to their bactericidal effects, the implementation of phage therapy depends on the availability of virulent phages against target bacteria. Notably, virulent phages of *Streptococcus gordonii*, which resides in the oral cavity and is an opportunistic pathogen that can cause periodontitis and endocarditis have previously never been found. We thus attempted to isolate virulent phages against *S. gordonii*. In the present study, we report for the first time a virulent bacteriophage against *S. gordonii*, ΦSG005, discovered from drainage water. ΦSG005 is composed of a short, non-contractile tail and a long head, revealing *Podoviridae* characteristics via electron microscopic analysis. In turbidity reduction assays, ΦSG005 showed efficient bactericidal effects on *S. gordonii*. Whole-genome sequencing showed that the virus has a DNA genome of 16,127 bp with 21 coding sequences. We identified no prophage-related elements such as integrase in the ΦSG005 genome, demonstrating that the virus is a virulent phage. Phylogenetic analysis indicated that ΦSG005 forms a distinct clade among the streptococcus viruses and is positioned next to streptococcus virus C1. Molecular characterization revealed the presence of an anti-CRISPR (Acr) IIA5-like protein in the ΦSG005 genome. These findings facilitate our understanding of streptococcus viruses and advance the development of phage therapy against *S. gordonii* infection.

Keywords: bacteriophage; streptococcus virus; phage therapy; *Streptococcus gordonii*

1. Introduction

Bacteriophages, which are viruses that infect bacterial cells, are ubiquitous in nature. Phage lifecycles are divided into two major categories, lysogenic and lytic [1,2]. In the lysogenic cycle, temperate phages infect host bacterial cells but are usually integrated into

出典 doi: 10.3390/v13101964
https://www.mdpi.com/1999-4915/13/10/1964
最終責任者 Hidetomo Iwano (Corresponding Author)

Contents lists available at ScienceDirect

Virus Research

journal homepage: www.elsevier.com/locate/virusres

Fluctuating Bacteriophage-induced *galU* Deficiency Region is Involved in Trade-off Effects on the Phage and Fluoroquinolone Sensitivity in *Pseudomonas aeruginosa*

Keisuke Nakamura [a,#], Jumpei Fujiki [a,#,*], Tomohiro Nakamura [a], Takaaki Furusawa [a], Satoshi Gondaira [b], Masaru Usui [c], Hidetoshi Higuchi [b], Yutaka Tamura [c], Hidetomo Iwano [a]

[a] Laboratory of Veterinary Biochemistry, Department of Veterinary Medicine, Rakuno Gakuen University, Ebetsu, Hokkaido, Japan
[b] Laboratory of Animal Health, Rakuno Gakuen University School of Veterinary Medicine, Ebetsu, Hokkaido, Japan
[c] Laboratory of Food Microbiology and Food Safety, Rakuno Gakuen University School of Veterinary Medicine, Ebetsu, Hokkaido, Japan

ARTICLE INFO

Keywords:
Bacteriophage
galU
Pseudomonas aeruginosa
Phage resistance
Phage therapy
Trade-off
Fitness cost

ABSTRACT

Pseudomonas aeruginosa, which causes chronic infections, has demonstrated rapid acquisition of antimicrobial resistance (AMR). Therefore, bacteriophages have received significant attention as promising antimicrobial agents; however, previous trials have reported the occurrence of phage-resistant variants. *P. aeruginosa* has lost large chromosomal fragments via evolutionary selection by MutL. Mutants lacking *galU* and *hmgA*, located in close proximity, exhibit phage resistance and brown color phenotype since *hmgA* encodes a homogentisic acid metabolic enzyme and deletion of *galU* results in a lack of *O*-antigen polysaccharide and absence of the phage receptor. In the present study, we evaluated this mechanism for controlling phage resistance in *P. aeruginosa* veterinary isolate Pa12. Phage-resistant Pa12 brown mutants (brmts) with *galU* and *hmgA* deletions were isolated. Whole-genome sequencing of the brmts revealed that regions 148-27 kbp upstream and 261-110 kbp downstream of *galU* were largely deleted from the Pa12 parental chromosome. Furthermore, all of these fluctuating deleted sequences in Pa12 brmts, tentatively designated bacteriophage-induced *galU* deficiency (BigD) regions, harbor multi-drug efflux system genes (*mexXY*). Minimum inhibitory concentration (MIC) assays demonstrated that brmts altered sensitivity to antibiotics and exhibited increased levofloxacin sensitivity compared with the Pa12 parent. Orbifloxacin and enrofloxacin also effectively suppressed growth of the Pa12 brmts, suggesting that MexXY, which mediates quinolone efflux and is located in the BigD region, might be associated with restoration of fluoroquinolone sensitivity. Our findings indicate that AMR-related genes in the BigD region could produce trade-off effects between phages and drug sensitivity and thereby contribute to a potential strategy to control and prevent phage-resistant variants in phage therapy.

1. Introduction

Infectious diseases caused by antimicrobial-resistant bacteria have considerable negative impacts on public health. O'Neill *et al.* estimated that by 2050, 10 million people will die annually due to antimicrobial-resistant bacterial infections unless a global program to reduce antimicrobial resistance (AMR) is implemented (I.J, 2014). In this context, phage therapy has received significant attention as a promising antimicrobial strategy. In the lytic phage lifecycle, phages initially adsorb onto specific bacterial receptors, which enables the phages to enter and infect host bacterial cells and release progeny phages, resulting in bactericidal effects (Hampton et al., 2020). However, similar to the case with antibiotics, bacterial resistance to phage infection can emerge through a variety of molecular mechanisms (e.g., receptor mutations) and represents a significant concern to develop successful phage therapies (Hampton et al., 2020; Oechslin, 2018; Schooley et al., 2017). Therefore, developing strategies to control the emergence of phage-resistant bacteria are crucial.

Pseudomonas aeruginosa is considered a major multidrug-resistant (MDR) bacterium, and this organism has made antimicrobial

* Corresponding author: Jumpei FUJIKI 069-8501.
E-mail address: j-fujiki@rakuno.ac.jp (J. Fujiki).
# These authors contributed equally to this work.

https://doi.org/10.1016/j.virusres.2021.198596
Received 13 July 2021; Received in revised form 4 October 2021; Accepted 5 October 2021
Available online 12 October 2021
0168-1702/© 2021 Elsevier B.V. All rights reserved.

出典　doi: 10.1016/j.virusres.2021.198596.
https://www.sciencedirect.com/science/article/abs/pii/S0168170221003038?via%3Dihub

最終責任者 Jumpei Fujiki（Corresponding and Co-first Author）

AMERICAN SOCIETY FOR MICROBIOLOGY | Microbiology Resource Announcements

GENOME SEQUENCES

Complete Genome Sequence of a Veterinary *Pseudomonas aeruginosa* Isolate, Pa12

Keisuke Nakamura,[a] Jumpei Fujiki,[a] Takaaki Furusawa,[a] Tomohiro Nakamura,[a] Satoshi Gondaira,[b] Michihito Sasaki,[c] Masaru Usui,[d] Hidetoshi Higuchi,[b] Hirofumi Sawa,[c,e] Yutaka Tamura,[d,f] Hidetomo Iwano[a]

[a]Laboratory of Veterinary Biochemistry, Rakuno Gakuen University School of Veterinary Medicine, Ebetsu, Japan
[b]Laboratory of Animal Health, Rakuno Gakuen University School of Veterinary Medicine, Ebetsu, Japan
[c]Division of Molecular Pathobiology, International Institute for Zoonosis Control, Hokkaido University, Sapporo, Japan
[d]Laboratory of Food Microbiology and Food Safety, Rakuno Gakuen University School of Veterinary Medicine, Ebetsu, Japan
[e]International Collaboration Unit, International Institute for Zoonosis Control, Hokkaido University, Sapporo, Japan
[f]Center for Veterinary Drug Development, Rakuno Gakuen University, Ebetsu, Japan

ABSTRACT *Pseudomonas aeruginosa* causes various opportunistic infections in animals. Here, we report the complete genome sequence of *P. aeruginosa* strain Pa12, a fluoroquinolone-resistant isolate from a canine skin lesion. To expand the molecular antimicrobial characteristics of the isolate, the whole Pa12 genome was sequenced and assembled via long- and short-read platforms.

Pseudomonas aeruginosa is an opportunistic Gram-negative bacterium and an important pathogen of humans and animals. In veterinary medicine, *P. aeruginosa* typically causes skin and urinary tract infections in dogs (1–3). The recent spread of antimicrobial resistance (AMR) has become a major problem in veterinary medicine; notably, the rate of resistance to fluoroquinolones has increased rapidly (4–6).

Pseudomonas aeruginosa exhibits AMR via multiple mechanisms. Multidrug efflux (Mex) systems are associated with intrinsic fluoroquinolone resistance, and *P. aeruginosa* can also acquire fluoroquinolone resistance through mutations in genes of the quinolone resistance–determining region (QRDR) (7–10).

We previously isolated *P. aeruginosa* strain Pa12 from a canine skin lesion at a veterinary hospital in Japan (11). The specimen was cultured on sheep blood agar and MacConkey agar at 35°C for 24 to 48 h under aerobic conditions. This strain exhibited intermediate resistance to orbifloxacin in MIC assays (11, 12). In the present study, we report the complete genome sequence of *P. aeruginosa* strain Pa12 to enhance molecular understanding of the isolate with respect to AMR.

DNA was extracted from an overnight culture (grown at 37°C in LB medium) using phenol and chloroform (13) and purified using a QIAamp DNA minikit column (Qiagen, Hilden, Germany). The DNA concentration was determined using a Qubit fluorometer (Invitrogen, Carlsbad, CA, USA). Whole-genome sequencing was performed using MiSeq (Illumina, San Diego, CA, USA) and GridION X5 (Oxford Nanopore Technologies [ONT], Oxford, UK) platforms. Libraries for Illumina sequencing were prepared using a Nextera XT DNA library preparation kit (Illumina). The whole genome was then subjected to 300-bp paired-end sequencing on the MiSeq platform. The resulting 8,118,954 reads were trimmed of adaptors and low-quality bases (Q scores of <20), and short reads (<127 bp) were removed using Sickle v1.33. Libraries for GridION X5 sequencing were prepared using a native barcoding expansion kit (ONT) and a ligation sequence kit (SQK-LSK109; ONT) without DNA shearing. The resulting sample was sequenced on the GridION X5 platform using an R9.4.1 flow cell (ONT) and Guppy v3.2.10 for live base calling. The resulting 56,776 reads were trimmed and quality filtered using Porechop v0.2.3 and Filtlong v0.2.0 (minimum length, 1,000 bp; N_{50}, 25,214 bp). Hybrid *de novo* assembly,

Citation Nakamura K, Fujiki J, Furusawa T, Nakamura T, Gondaira S, Sasaki M, Usui M, Higuchi H, Sawa H, Tamura Y, Iwano H. 2021. Complete genome sequence of a veterinary *Pseudomonas aeruginosa* isolate, Pa12. Microbiol Resour Announc 10:e00398-21. https://doi.org/10.1128/MRA.00398-21.

Editor Irene L. G. Newton, Indiana University, Bloomington

Copyright © 2021 Nakamura et al. This is an open-access article distributed under the terms of the Creative Commons Attribution 4.0 International license.

Address correspondence to Jumpei Fujiki, j-fujiki@rakuno.ac.jp.

Received 18 April 2021
Accepted 31 May 2021
Published 1 July 2021

出典 doi: 10.1128/MRA.00398-21
https://journals.asm.org/doi/epub/10.1128/MRA.00398-21
最終責任者 Jumpei Fujiki（Corresponding Author）

Gondaira *et al. Vet Res* (2021) 52:58
https://doi.org/10.1186/s13567-021-00920-2

VETERINARY RESEARCH

RESEARCH ARTICLE Open Access

Innate immune response in bovine neutrophils stimulated with *Mycoplasma bovis*

Satoshi Gondaira[1], Koji Nishi[1], Jumpei Fujiki[2], Hidetomo Iwano[2], Reina Watanabe[1], Ayako Eguchi[1], Yuki Hirano[3], Hidetoshi Higuchi[1*] and Hajime Nagahata[1,4]

Abstract

Mycoplasma bovis (*M. bovis*) is a significant worldwide pathogen of cattle. Neutrophils have an important role in the innate immune response during infection with *M. bovis*. However, even though neutrophils accumulate in *M. bovis* infection, the interaction of *M. bovis* and neutrophils has not been fully elucidated. We attempted to elucidate the innate immune response of neutrophils stimulated with *M. bovis* and evaluate the transcriptome and functional analysis of bovine neutrophils stimulated with *M. bovis*. Proinflammatory cytokines, such as inducible nitric oxide (*iNOS*), which was the most increased gene in transcriptome analysis, were increased in quantitative polymerase chain reaction analysis of bovine neutrophils stimulated with live or heat-killed *M. bovis*. Nitric oxide and intracellular reactive oxygen species production of neutrophils stimulated with *M. bovis* was significantly increased. Neutrophils stimulated with *M. bovis* showed an increased ratio of nonapoptotic cell death compared to unstimulated controls. We demonstrated that neutrophil extracellular traps (NETs) formation was not recognized in neutrophils stimulated with live *M. bovis*. However, heat-killed *M. bovis* induced NETs formation. We also showed the interaction with *M. bovis* and bovine neutrophils regarding proinflammatory cytokine gene expression and functional expression related to NETs formation. Live and killed *M. bovis* induced innate immune responses in neutrophils and had the potential to induce NETs formation, but live *M. bovis* escaped NETs.

Keywords: *Mycoplasma bovis*, Bovine, Neutrophils, Innate immune, Transcriptome analysis

出典　doi:110.1186/s13567-021-00920-2.
https://veterinaryresearch.biomedcentral.com/articles/10.1186/s13567-021-00920-2

最終責任者　Hidetoshi Higuchi（Corresponding Author）

Wiley Online Library

Animal Science Journal

ORIGINAL ARTICLE

Immune response during the onset of coliform mastitis in dairy cows vaccinated with STARTVAC®

Kazuhiro Kawai, Yasuha Kondo, Yasunori Shinozuka, Ryusaku Kawata, Sohei Kaneko, Hidetomo Iwano, Masafumi Enokidani, Aiko Watanabe ... See all authors

First published: 05 January 2021 | https://doi.org/10.1111/asj.13502 | Citations: 1

Read the full text > PDF TOOLS SHARE

Abstract

The immune response during the onset of coliform mastitis in vaccinated cows was investigated by measuring lactoferrin (LF), interleukin-8 (IL-8), and interleukin-1β (IL-1β) concentrations and somatic cell counts in 28 milk samples at the onset of acute coliform mastitis (ACM) and 73 milk samples at the onset of peracute coliform mastitis (PCM). Vaccinated ACM, unvaccinated ACM, and vaccinated PCM showed significantly higher values for LF and IL-1β levels than unvaccinated PCM ($p < .01$). The IL-8 concentration was lower in vaccinated PCM than in unvaccinated PCM ($p < .05$). There was no significant difference in somatic cell counts for each parameter. There were no significant differences in the parameters between vaccinated and unvaccinated ACM cows, or vaccinated ACM and PCM cows. From the above results, it is suggested that mastitis vaccination improved the early immune response, particularly at the onset of PCM, and played a large role in host defense against the initial infection.

出典　doi: https://doi.org/10.1111/asj.13502.
https://onlinelibrary.wiley.com/doi/10.1111/asj.13502

最終責任者　Naoki Isobe (Corresponding Author)

獣医細菌学（Veterinary Bacteriology）

Ikuo Uchida

Professor

教授　内田　郁夫

Ⅰ．筆頭または責任著者　＜First or Corresponding Author＞

Ⅱ．その他＜Others＞

1) Intramammary infection caused *by* *Staphylococcus aureus* increases IgA antibodies to iron-regulated surface determinant-A, -B, and -H in bovine milk
Nagasawa Y, **Uchida, I**, Tanabe F, Hirose A, Sugawara K, Kiku Y, Iwata T, Kato C, Yamashita Y, Hayashi T.
Veterinary Immunology and Immunopathology 235:110235. 2021.
doi.org/10.1016/j.vetimm.2021.110235

Veterinary Immunology and Immunopathology 235 (2021) 110235



Contents lists available at ScienceDirect

Veterinary Immunology and Immunopathology

journal homepage: www.elsevier.com/locate/vetimm



Research paper



Intramammary infection caused by *Staphylococcus aureus* increases IgA antibodies to iron-regulated surface determinant-A, -B, and -H in bovine milk

Yuya Nagasawa [a], Ikuo Uchida [a,b], Fuyuko Tanabe [a], Aya Hirose [a], Kazue Sugawara [a], Yoshio Kiku [a], Takehito Iwata [a], Chieko Kato [c], Yusuke Yamashita [d], Tomohito Hayashi [a,*]

[a] *Dairy Hygiene Research Division, National Institute of Animal Health, National Agriculture and Food Research Organization, 4 Hitsujigaoka, Toyohira, Sapporo, Hokkaido, 062-0045, Japan*

[b] *Division of Health and Science, School of Veterinary Medicine, Rakuno Gakuen University, 582, Bunkyodai-Midorimachi, Ebetsu, Hokkaido, 069-8501, Japan*

[c] *Hokkaido Tokachi Livestock Hygiene Service Center, 59-6 Kisen, Kawanishicho, Obihiro, Hokkaido, 089-1182, Japan*

[d] *Hokkaido Chuou Agriculture and Mutual Aid Association Nayoro Large Animal Clinic, 136-47 Houei, Nayoro, Hokkaido, 096-0072, Japan*

ARTICLE INFO

Keywords:
Bovine mastitis
Iron-Regulating surface determinant
Milk antibodies
Staphylococcus aureus

ABSTRACT

The aim of this study was to identify virulence factors that have high immunogenicity. An *in vivo*-expressed *Staphylococcus aureus* antigen was identified by probing bacteriophage expression libraries of *S. aureus* with antibodies in bovine mastitis milk. Eighteen clones were isolated, and their proteins were identified as 5 characterised proteins (IsdA, Protein A, IsdB, autolysin, and imidazole glycerol phosphate dehydratase) and 13 hypothetical proteins. We focused on IsdA, IsdB, and IsdH as virulence factors that have a high immunogenicity and are capable of inducing a specific humoral immune response in *S. aureus*-infected quarters. The optical density (OD) values of IsdA and IsdB IgA and IgG antibodies in milk affected by naturally occurring mastitis caused by *S. aureus* increased significantly compared to those in healthy milk. In the experimental infection study, the OD values of IsdA- and B-specific IgA and IgG antibodies were significantly increased from 2 to 4 weeks after *S. aureus* infection compared to day 0 ($P < 0.05$). On the other hand, we demonstrated that milk from natural and experimental intramammary infections caused by *S. aureus* are associated with significantly higher IgA levels against IsdH ($P < 0.05$), but no significant change in IgG levels. Our findings facilitated our understanding of the pathogenicity of *S. aureus* in bovine mastitis, as well as the mechanisms by which specific humoral immune responses to *S. aureus* infection are induced. In addition, the results obtained could provide insight into how bovine mastitis can be controlled, for example, through vaccination.

出典　https://doi.org/10.1016/j.vetimm.2021.110235

最終責任者　Hayashi Tomohito（Corresponding Author）

放射線生物学（Veterinary Basic Radiology）

Daiji Endoh

Professor

教授　遠藤　大二

Ⅰ．筆頭または責任著者　＜First or Corresponding Author＞

1）Kayama, K., Kanno, M., Chisaki, N., Tanaka, M., Yao, R., Hanazono, K., Gerry A. & **Endoh, D.**
Prediction of PCR amplification from primer and template sequences using recurrent neural network. *Scientific reports*, 11(1), 1-24 2021. doi: 10.1038/s41598-021-86357-1.

Ⅱ．その他＜Others＞

1）Chhay, S., Hanazono, K., Kitahara, J., Hori, A., Miyoshi, K., Itami, T., **Endoh, D.** & Nakade, T. Effects of gel pad thickness on skin stiffness evaluation by ultrasonographic strain elastography in normal dogs. *Japanese Journal of Veterinary Research*, 69(2), 125-134. 2021. doi: 10.14943/jjvr.69.2.125.

2）Chhay, S., Hanazono, K., Kitahara, J., Hori, A., Miyoshi, K., Itami, T., **Endoh, D.** & Nakade, T. The effects of gel pad thickness on the evaluation of skin structures using ultrasonography in normal dogs. *Journal of Veterinary Medical Science*, 83(9), 1472-1475. 2021. doi: 10.1292/jvms.21-0086

scientific reports

Check for updates

OPEN

Prediction of PCR amplification from primer and template sequences using recurrent neural network

Kotetsu Kayama[1], Miyuki Kanno[1], Naoto Chisaki[1], Misaki Tanaka[1], Reika Yao[1], Kiwamu Hanazono[1], Gerry Amor Camer[1,2] & Daiji Endoh[1]

We have developed a novel method to predict the success of PCR amplification for a specific primer set and DNA template based on the relationship between the primer sequence and the template. To perform the prediction using a recurrent neural network, the usual double-stranded formation between the primer and template nucleotide sequences was herein expressed as a five-lettered word. The set of words (pseudo-sentences) was placed to indicate the success or failure of PCR targeted to learn recurrent neural network (RNN). After learning pseudo-sentences, RNN predicted PCR results from pseudo-sentences which were created by primer and template sequences with 70% accuracy. These results suggest that PCR results could be predicted using learned RNN and the trained RNN could be used as a replacement for preliminary PCR experimentation. This is the first report which utilized the application of neural network for primer design and prediction of PCR results.

出典　https://doi.org/10.1038/s41598-021-86357-1.
https://www.nature.com/articles/s41598-021-86357-1

最終責任者　Daiji Endoh (Corresponding Author)

Japanese Journal of Veterinary Research 69(2): 125-134, 2021

JJVR

REGULAR PAPER Experimental Research

Effects of gel pad thickness on skin stiffness evaluation by ultrasonographic strain elastography in normal dogs

Sothavy Chhay[1)], Kiwamu Hanazono[2,3,*)], Jo Kitahara[1)], Ai Hori[3)], Kenjiro Miyoshi[1,3)], Takaharu Itami[1,3)], Daiji Endoh[2)] and Tetsuya Nakade[1,3)]

[1)] Department of Small Animal Clinical Sciences, School of Veterinary Medicine, Rakuno Gakuen University, 582 Bunkyodai Midorimach, Ebetu-shi, Hokkaido 069-8501, Japan

[2)] Department of Biosciences, School of Veterinary Medicine, Rakuno Gakuen University, Ebetsu, Hokkaido 069-8501, Japan

[3)] Animal Medical Center, Rakuno Gakuen University, 582 Bunkyodai Midorimach, Ebetu-shi, Hokkaido 069-8501, Japan

Received for publication, November 8, 2020; accepted, February 25, 2021

Abstract

Gel pads are commonly used for skin ultrasound examination; however, the effect of their thickness on the measured values is unknown. We investigated the effect of pad thickness on skin stiffness measurement in healthy dogs. The skin stiffness of the dorsal neck was measured using a durometer. Ultrasonographic strain elastography was performed with 5-, 10-, and 20-mm-thick pads. Among the strain ratios, muscle/skin (5 mm) showed a significantly positive correlation with skin stiffness. In the strain histogram, AREA (20 mm), CONTRAST (20 mm), MEAN (5, 20 mm), and STANDARD DEVIATION (20 mm) were significantly correlated with skin stiffness. In conclusion, the thickness of the gel pad affects the measurements during skin ultrasonographic strain elastography.

Key Words: Gel pad, normal dog, skin ultrasonography, ultrasonographic strain elastography

出典　https://doi.org/10.14943/jjvr.69.2.125.

http://hdl.handle.net/2115/81817

最終責任者　Kiwamu Hanazono (Corresponding Author)

The Journal of Veterinary Medical Science

NOTE

Internal Medicine

The effects of gel pad thickness on the evaluation of skin structures using ultrasonography in normal dogs

Sothavy CHHAY[1)], Kiwamu HANAZONO[1,2)*], Jo KITAHARA[1)], Ai HORI[2)], Kenjiro MIYOSHI[1,2)], Takaharu ITAMI[1,2)], Daiji ENDOH[1)] and Tetsuya NAKADE[1,2)]

[1)]School of Veterinary Medicine, Rakuno Gakuen University, 582 Bunkyodai Midorimach, Ebetsu, Hokkaido 069-8501, Japan

[2)]Animal Medical Center, Rakuno Gakuen University, 582 Bunkyodai Midorimach, Ebetsu, Hokkaido 069-8501, Japan

J. Vet. Med. Sci.
83(9): 1472–1475, 2021
doi: 10.1292/jvms.21-0086

Received: 15 February 2021
Accepted: 14 July 2021
Advanced Epub:
26 July 2021

ABSTRACT. Gel pads are commonly used in skin ultrasonography; however, the effects of their thickness are unknown. This study investigated the effects of pad thickness on measurements of skin thickness in 10 beagle dogs. Sonograms to measure neck skin thickness were captured without pads and using pads with thicknesses of 3, 5, 10, and 20 mm. Without pads, acoustic shading was observed due to air bubbles in the coupling gel. With 20-mm pads, echogenic artifacts were observed on the skin surface. Entry echo with 20-mm pads was significantly higher than with 3-mm pads. This suggests that visibility of the skin structure could be affected when a gel pad is not used or when a thick gel pad is selected.

KEY WORDS: artifact, gel pad, normal dog, skin thickness, skin ultrasonography

出典　https://doi.org/10.1292/jvms.21-0086

https://www.jstage.jst.go.jp/article/jvms/83/9/83_21-0086/_pdf/-char/ja

最終責任者　Kiwamu Hanazono (Corresponding Author)

ハードヘルス学（Veterinary Herd Health）

Shin Oikawa

Professor

教授　及川　伸

Ⅰ．筆頭または責任著者　＜First or Corresponding Author＞

1) The effect of sodium butyrate supplementation on ruminal and fecal pH and serum lipopolysaccharide-binding protein after ruminal acidosis challenge in nonlactating cows.
Fukumori R, Ikeno R, Izumi K, Doi K, Otsuka M, Suzuki K, **Oikawa, S.**
Anim. Sci. J. 2021. doi: 10.1111/asj.13673.

Ⅱ．その他＜Others＞

1) Diagnostic utility of measuring serum amyloid A with a latex agglutination turbidimetric immunoassay in bovine mastitis: Comparison with haptoglobin and alpha-1 acid glycoprotein.
Otsuka M, Sugiyama M, Ito T, Tsukano K, **Oikawa S,** Suzuki K.
J. Vet. Med. Sci. 83:329-332. 2021. doi: 10.1292/jvms. 20-0550.

2) Evaluation of relationship between ruminal pH and the proportion of de novo fatty acids in milk.
Fukumori R, Weina S, **Oikawa S,** Oba M. 2021.
J. Dairy Sci. Commun. 2:123-126. 2021. doi.org/10.3168/jdsc.2020-0042.

3) Role of insulin, insulin sensitivity, and abomasal functions monitors in evaluation of the therapeutic regimen in ketotic dairy cattle using combination therapy with referring to milk yield rates.
Elmeligy E, **Oikawa S,** Mousa S. A, Bayoumi S. A, Hafez A, Mohamed R. H, Al-lethie A. A, Hassan D, Khalphallah A.
Open Vet. J. 11:228-237. 2021. doi: 10.5455/OVJ.2021.v11.i2.7.

RESEARCH ARTICLE

Animal Science Journal WILEY

The effect of sodium butyrate supplementation on ruminal and fecal pH and serum lipopolysaccharide-binding protein after ruminal acidosis challenge in nonlactating cows

Rika Fukumori[1] | Rina Ikeno[1] | Kenichi Izumi[2] | Kazuya Doi[2] | Marina Otsuka[1] | Kazuyuki Suzuki[1] | Shin Oikawa[1]

[1]Department of Veterinary Medicine, School of Veterinary Medicine, Rakuno Gakuen University, Ebetsu, Japan

[2]Department of Sutainable Agricultrure, College of Agriculture, Food and Environment Sciences, Rakuno Gakuen University, Ebetsu, Japan

Correspondence
Shin Oikawa, Department of Veterinary Medicine, School of Veterinary Medicine, Rakuno Gakuen University, Ebetsu 069-8501, Japan.
Email: oishin@rakuno.ac.jp

Funding information
Japan Society for the Promotion of Science, Grant/Award Number: #18K14593

Abstract

The objective of this study was to evaluate effects of sodium-butyrate supplementation on gastrointestinal function and the inflammatory response to ruminal acidosis (RA) challenge in cows. Four nonlactating cows with a rumen cannula were assigned to two treatments in a crossover design. Treatments were ruminal administration of sodium-butyrate (BUT) or control (CON). Sodium-butyrate was provided as Gustor BP70 and administered at a butyrate dose of 0.04% per kg body weight. The CON premix was made by replacing sodium-butyrate with wheat bran. Experimental periods were 28 days long with 21-day washout period separating the treatments. On Day 25 of each period, corn starch was ruminally administered at 0.7% per kg body weight as RA challenge. After RA challenge, ruminal pH was lower, and endotoxin concentration was higher for cows provided with BUT than those with CON, but the increase in fecal starch and the decrease in fecal pH were attenuated by BUT. The effect of butyrate supplementation on serum lipopolysaccharide-binding protein after RA challenge was not found. From these findings, butyrate supplementation mitigated rectal acidosis by reducing the flux of fermentable carbohydrate into the large intestine. An anti-inflammatory effect of butyrate was not observed, possibly due to lower pH and higher endotoxin concentration in the rumen.

KEYWORDS
butyric acid, endotoxin, lipopolysaccharide-binding protein, ruminal acidosis

出典 doi.org/10.1111/asj.13673
https://onlinelibrary.wiley.com/doi/10.1111/asj.13673
最終責任者 Shin Oikawa (Corresponding Author)

The Journal of Veterinary Medical Science

NOTE

Internal Medicine

Diagnostic utility of measuring serum amyloid A with a latex agglutination turbidimetric immunoassay in bovine mastitis: Comparison with haptoglobin and alpha 1 acid glycoprotein

Marina OTSUKA[1], Mieko SUGIYAMA[2], Takaaki ITO[3], Kenji TSUKANO[4], Shin OIKAWA[1] and Kazuyuki SUZUKI[1]*

[1]School of Veterinary Medicine, Rakuno Gakuen University, 582 Bunkyodai-Midorimachi, Ebetsu, Hokkaido 069-8501, Japan
[2]Ehime Agricultural Mutual Aid Association, 4-4-2 Nibancho, Matsuyama, Ehime 790-0002, Japan
[3]Aichi Agricultural Mutual Aid Association, 2-1-11 Marunouchi, Nakaku, Nagoya 460-0002, Japan
[4]Minami-Hokkaido Agricultural Mutual Aid Association, 74-2 Higashimae, Hokuto, Hokkaido 041-1214, Japan

J. Vet. Med. Sci.
83(2): 329–332, 2021
doi: 10.1292/jvms.20-0550

Received: 14 September 2020
Accepted: 17 December 2020
Advanced Epub:
29 December 2020

ABSTRACT. This study established the precision and accuracy of a modified latex agglutination turbidimetric immunoassay (LATIA) reagent, and evaluated the ability of the measurement of serum amyloid A (SAA) compared to haptoglobin and α1-acid glycoprotein, which are acute phase proteins (APPs), for diagnosis of clinical mastitis. Concentrations of APPs in cows with mastitis were significantly higher than those in healthy cow. Only the plasma SAA concentration in cows with clinical mastitis (44.90 mg/l; n=15) was significantly higher than that in those with subclinical mastitis (10.70 mg/l; n=16), enabling their diagnosis in contrast to other APPs. Thus, the SAA assay using a LATIA reagent is useful in assessing mastitis severity due to its higher sensitivity and specificity than other APP assays.

KEY WORDS: acute phase protein, bovine, inflammation, mastitis, serum amyloid A

出典 doi: 10.1292/jvms. 20-0550

https://www.jstage.jst.go.jp/article/jvms/83/2/83_20-0550/_pdf/-char/en

最終責任者 Kazuyuki Suzuki (Corresponding Author)

JDS Communications
2021; 2:123–126

https://doi.org/10.3168/jdsc.2020-0042
Short Communication
Animal Nutrition and Farm Systems

Evaluation of relationship between ruminal pH and the proportion of de novo fatty acids in milk

R. Fukumori,[1] W. Shi,[2] S. Oikawa,[1] and M. Oba[2]*

Graphical Abstract

Milk de novo fatty acids estimated by FTIR were related to ruminal pH and can be useful for detecting SARA

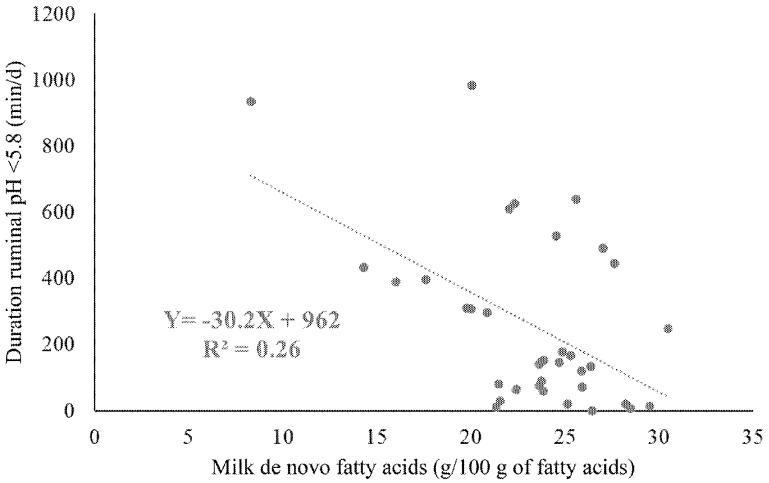

Summary

Subacute ruminal acidosis (SARA) is a serious problem in high-producing dairy cows, but its diagnosis is difficult. Recently, Fourier-transform infrared spectrometry (FTIR) was introduced to the dairy industry as a tool to estimate milk fatty acids (FA), such as de novo, mixed-origin, and preformed FA. The present study showed that milk de novo FA (g/100 g of FA) concentration was positively related to nadir and mean ruminal pH and negatively related to duration below pH 5.8. Milk fat content was not related to ruminal pH, indicating that milk de novo FA concentration is an appropriate measurement variable that relates to ruminal pH.

Highlights

- Milk de novo fatty acids (DNFA) estimated by FTIR were correlated with ruminal pH.
- Ruminal pH was correlated better with DNFA than milk fat content or yield.
- Ruminal pH was correlated better with DNFA in milk fat than with DNFA in milk.



出典　doi.org/10.3168/jdsc.2020-0042
https://www.jdscommun.org/article/S2666-9102(21)00044-2/pdf

最終責任者　Masahito Oba (Corresponding Author)

Open Veterinary Journal, (2021), Vol. 11(2): 228–237
ISSN: 2226-4485 (Print)
ISSN: 2218-6050 (Online)

Original Research
DOI: *10.5455/OVJ.2021.v11.i2.7*

Submitted: 29/01/2021 Accepted: 01/04/2021 Published: 30/04/2021

Role of insulin, insulin sensitivity, and abomasal functions monitors in evaluation of the therapeutic regimen in ketotic dairy cattle using combination therapy with referring to milk yield rates

Enas Elmeligy[1*], Shin Oikawa[2], Sabry A. Mousa[3], Sara A. Bayoumi[4], Ahmed Hafez[5], Ragab H. Mohamed[6], Al-lethie A. Al-lethie[7], Dalia Hassan[8] and Arafat Khalphallah[9]

[1]*Veterinary Teaching Hospital, Faculty of Veterinary Medicine, Assiut University, Assiut, Egypt*
[2]*Departments of Veterinary Herd Health, School of Veterinary Medicine, Rakuno Gakuen University, Ebetsu, Japan*
[3]*Division of Internal Medicine, Department of medicine and infectious disease, Faculty of Veterinary Medicine, Cairo University, Giza, Egypt*
[4]*Division of Clinical Laboratory Diagnosis, Department of Animal Medicine, Faculty of Veterinary Medicine, Assiut University, Assiut, Egypt*
[5]*Department of Pharmacology, Faculty of Veterinary, Medicine, Aswan University, Aswan, Egypt*
[6]*Theriogenology Department, Faculty of Veterinary Medicine, Aswan University, Aswan, Egypt*
[7]*Department of Surgery, Anaesthesiology and Radiology, Faculty of Veterinary Medicine, Aswan University, Aswan, Egypt*
[8]*Department of Animal & Poultry Hygiene and Environmental Sanitation, Faculty of Veterinary Medicine, Assiut University, Assiut, Egypt*
[9]*Division of Internal Medicine, Department of Animal Medicine, Faculty of Veterinary Medicine, Assiut University, Assiut, Egypt*

Abstract

Background: Ketosis is one of the most critical metabolic disorders that occur in dairy cows after parturition due to negative energy balance around calving.

Aim: The study evaluated a specific therapeutic regimen of ketosis in Holstein dairy cattle by using the combination therapy including hormones, corticosteroids, propylene glycol, and vitamin B12 as well as the use of milk yield rates, insulin, insulin sensitivity, and abomasal functions monitors as diagnostic biomarkers for the recovery of ketotic cows either pre-therapy (0 days) or post-therapy (7 and 14 days).

Methods: This study was conducted on ketotic cattle (n = 20) belonged to different dairy farms in Cairo and Giza governorates, Egypt. The diseased cows were undergoing clinical and biochemical investigations for the estimation of serum insulin. Quantitative Insulin Sensitivity Check Index (RQUICKI) and abomasal functions monitor mainly serum levels of gastrin, pepsinogen, and chloride.

Results: The milk production rates, cost: benefit analysis ratio, and benefit of the dairy farm in ketotic animals a were significnt ly increased post-treatment. An improvement of insulin sensitivity was stated as serum insulin, and RQUICKI were remarkably increased in post-therapeutic ketotic cows. Monitors of the abomasal function revealed abomasal functions improvement through ahe significnt elevation of blood gastrin and a substantial reduction in serum pepsinogen due to treatment.

Conclusion: The study revealed high afficcy of the applied therapeutic strategy regime. It led to a high recovery rate and a very low relapse rate for ketosis. An improvement in milk yield rates, insulin sensitivity, and abomasal function monitors was reported. Hypoinsulinaemia was still reported, however, serum insulin was improved.

Keywords: Abomasal functions monitors, Cattle, Insulin resistance, Ketosis, RQUICKI.

出典　doi: 10.5455/OVJ.2021.v11.i2.7.
https://www.ncbi.nlm.nih.gov/pmc/articles/PMC8288746/

最終責任者　Enas Elmeligy (Corresponding Author)

生産動物病態学（Farm Animal Pathophysiology）

Hiromichi Ohtsuka

Professor

教授　大塚　浩通

Ⅰ．筆頭または責任著者　＜First or Corresponding Author＞

1) Changes in mRNA of immune factors expressed by milk somatic cells of Holstein cows with hypocalcemia after calving. **Ohtsuka H**, Ohsawa M, Murakami K, Murata R, Kato T, Tajima M. *Can. J. Vet. Res.* 85: 72-76. 2021.

Ⅱ．その他＜Others＞

1) Effects of intra-articular inoculation with Mycoplasma bovis on immunological responses in calf joints. Nishi K, Hirano Y, Sato A, Eguchi A, Matsuda K, Toda M, Watanabe T, Iwasaki T, Takahashi N, Hosotani M, Watanabe R, Kato T, **Ohtsuka H**, Gondaira S, Higuchi H. *Vet. Immunol. Immunopathol.* 244: 110364. 2021. doi: 10.1016/j.vetimm.2021.110364.

Changes in mRNA of immune factors expressed by milk somatic cells of Holstein cows with hypocalcemia after calving

Hiromichi Ohtsuka, Misa Ohsawa, Kenji Murakami, Ryo Murata, Toshihide Kato, Motoshi Tajima

Abstract

Changes in immune factors expressed by milk somatic cells from Holstein cows with hypocalcemia after calving were investigated in this study. Fourteen multiparous Holstein cows after their 3rd or 4th calving in one farm were used. The cows were divided into 2 groups: 7 cows needing treatment due to onset of hypocalcemia (hypocalcemia group; age = 5.53 ± 0.27 years, parity = 3.14 ± 0.14) and 7 cows without health problems (control group; age = 5.88 ± 0.31 years, parity = 3.57 ± 0.26). Milk samples were collected aseptically using a cannula and mRNA of immune factors expressed by milk somatic cells were analyzed. Milk samples (50 mL) were collected from the right rear mammary gland of cows before milking at day 1 and weeks 1, 2, 4, and 8 after calving. All milk samples showed a negative reaction to the California Mastitis Test. Levels of relative interleukin (IL)-6 and cathelicidin in the hypocalcemia group were lower than those in the control group in weeks 1 to 8. A significant difference in relative IL-6 levels was found in week 4 ($P < 0.05$). These results suggest that levels of IL-6 expressed by milk somatic cells may be affected by hypocalcemia in dairy cows.

出典 PMCID: PMC7747659
https://www.ncbi.nlm.nih.gov/pmc/articles/PMC7747659/pdf/cjvr_01_72.pdf
最終責任者 Hiromichi Ohtsuka (First Author and Corresponding Author)

Contents lists available at ScienceDirect

Veterinary Immunology and Immunopathology

journal homepage: www.elsevier.com/locate/vetimm



Research paper

Effects of intra-articular inoculation with *Mycoplasma bovis* on immunological responses in calf joints

Koji Nishi [a,b], Yuki Hirano [a,c], Ayano Sato [d], Ayako Eguchi [a], Kazuya Matsuda [e], Miyuki Toda [e], Takafumi Watanabe [f], Tomohito Iwasaki [g], Naoki Takahashi [h], Marina Hosotani [f], Reina Watanabe [a], Toshihide Kato [d], Hiromichi Ohtsuka [d], Satoshi Gondaira [a,*], Hidetoshi Higuchi [a,*]

[a] *Animal Health Laboratory, Department of Veterinary Science, School of Veterinary Medicine, Rakuno Gakuen University, Ebetsu, Hokkaido, Japan*
[b] *NOSAI Okhotsk Monbetsu Veterinary Clinic, Monbetsu, Hokkaido, Japan*
[c] *Animal Research Center, Agricultural Research Department, Hokkaido Research Organization, Shintoku, Hokkaido, Japan*
[d] *Large Animal Clinical Science, Department of Veterinary Science, School of Veterinary Medicine, Rakuno Gakuen University, Ebetsu, Hokkaido, Japan*
[e] *Department of Veterinary Pathology, Department of Veterinary Science, School of Veterinary Medicine, Rakuno Gakuen University, Ebetsu, Hokkaido 069-8501, Japan*
[f] *Laboratory of Veterinary Anatomy, School of Veterinary Medicine, Rakuno Gakuen University, Ebetsu, Hokkaido, Japan*
[g] *Department of Food Science and Human Wellness, College of Agriculture, Food and Environment Science, Rakuno Gakuen University, Hokkaido, Japan*
[h] *Department of Veterinary Anatomy, College of Bioresource Sciences, Nihon University, Fujisawa, Kanagawa, Japan*

ARTICLE INFO

Keywords:
Arthritis
Inflammatory cytokines
Invasion
Matrix metalloproteinases
Mycoplasma bovis

ABSTRACT

Mycoplasma arthritis that caused by *Mycoplasma bovis* exhibit severe lameness. This disease is difficult to cure with antibiotics, but the detailed pathological mechanisms have not been fully clarified. In this study, we examined the effects of intra-articular inoculation with *M. bovis* on immunological responses in calf joints. We inoculated three calves each with *M. bovis* or phosphate buffer saline (control) into the right stifle joint and dissected them at 15 days postinoculation. *Mycoplasma bovis*–inoculated calves exhibited swelling of the stifle joint, increases in synovial fluid, fibrin deposition, and cartilage thinning. Intracellular *M. bovis* was detected in synovial tissues analyzed by immunohistochemistry and transmission electron microscopy. Messenger RNA expressions of interleukin (IL)-1β, IL-6, IL-8, IL-12p40, and IL-17A in synovial fluid cells and synovial tissues from *M. bovis*–inoculated calves were significantly higher than those from control calves. Protein levels of these cytokines in synovial fluid from *M. bovis*–inoculated calves were markedly higher than those from control calves. Our study clarified that inoculation with *M. bovis* into the stifle joint induced the production of inflammatory cytokines by synovial fluid cells and synovial tissues, causing a severe inflammatory response in joints. Additionally, *M. bovis* could invade cells in synovial tissues, which may have aided it in evading antibiotics and host immune surveillance.

出典　doi: 10.1016/j.vetimm.2021.110364.
https://www.sciencedirect.com/science/article/abs/pii/S0165242721001823
最終責任者　Hidetoshi Higuchi (Corresponding Author)

獣医生理学 (Veterinary Physiology)

Takenori Onaga

Professor

教授　翁長　武紀

Ⅰ．筆頭または責任著者　＜First or Corresponding Author＞

1) Effects of xenin-25 on insulin and glucagon secretions in healthy conscious sheep.
Onaga T, Hayashi, H, Yasui Y.
Domestic Animal Endocrinology 77:106635, 2021.
doi: 10.1016/j.domaniend.2021.106635

Ⅱ．その他＜Others＞

Domestic Animal Endocrinology 77 (2021) 106635

Contents lists available at ScienceDirect

Domestic Animal Endocrinology

journal homepage: www.journals.elsevier.com/domestic-animal-endocrinology

Effects of xenin-25 on insulin and glucagon secretions in healthy conscious sheep

Takenori Onaga*, Hideaki Hayashi, Yumiko Yasui

Veterinary Physiology, Division of Biosciences, Department of Veterinary Medicine, School of Veterinary Medicine, Rakuno Gakuen University, 582 Bunkyodai-Midorimachi, Ebetsu, Hokkaido 069-8501, Japan

ARTICLE INFO

Article history:
Received 1 December 2020
Received in revised form 3 May 2021
Accepted 4 May 2021

Keywords:
Islet hormones
Insulinotropic effect
Neurotensin
Glucose metabolism
Sheep
Ruminant

ABSTRACT

The aim of present study was to determine effect of an intravenous injection of xenin-25 on insulin and glucagon secretion in healthy conscious sheep. After feeding once at 17:00, the experiment was started from 9:00 on the next day. Xenin-25 was intravenously (i.v.) injected at a dose of 100 to 1000 pmol/kg with and without the simultaneous injection of glucose at a dose of 200 μmol/kg, and blood was withdrawn before and after the injections. A single xenin-25 injection at 100 and 300 pmol/kg significantly increased the plasma insulin concentration, whereas the 1000 pmol/kg dose did not elicit significantly enhanced insulin response. Plasma glucose and glucagon concentrations did not significantly change after a single xenin-25 injection. Xenin-25 injection significantly and dose-dependently augmented the glucose-induced insulin secretion. However, the changes in the plasma glucose and glucagon level after the glucose injection were not altered by xenin injection. A prior intravenous injection of the neurotensin receptor subtype-1 (NTR-1) antagonist SR 48692 at 100 nmol/kg did not modify the glucose-induced change in plasma insulin caused by xenin-25 at 300 pmol/kg, and intravenous injection of the NTR-2 agonist levocabastine at 1000 pmol/kg did not augment the insulin response to the glucose injection. On the other hand, no xenin-25 immunopositive cells were detected in the ovine pancreas. The mRNAs of the three NTR subtypes were highly expressed in the ovine pancreas in comparison with the expression in the abomasum. These results suggest that xenin-25 released from the upper gastrointestinal tract plays a role of an insulinotropic factor in sheep, possibly through NTRs in the pancreatic islets, but not via NTR-2.

© 2021 Elsevier Inc. All rights reserved.

出典　doi: 10.1016/j.domaniend.2021.106635
https://doi.org/10.1016/j.domaniend.2021.106635

最終責任者　Takenori Onaga　(First Author and Corresponding Author)

生産動物外科学（Farm Animal Surgery）

Toshihide Kato

Professor

教授　加藤　敏英

Ⅰ．筆頭または責任著者　＜First or Corresponding Author＞

Ⅱ．その他＜Others＞

1) Use of antimicrobial agents on a dairy farm where cefazoline-low susceptible *Mannheimia haemolytica* serotype 1 was isolated.

Misaki Akiyoshi, Minami Nouchi, Kazumi Sugiura, Ryo Murata, Noritsugu Abe, Ayano Sato, **Toshihide Kato**.
Jpn. J. Anim. Hyg. 47. 85-90. 2021. http://www.kachiku-eisei.jp/

Note

Use of antimicrobial agents on a dairy farm where cefazoline-low susceptible *Mannheimia haemolytica* serotype 1 was isolated

Misaki Akiyoshi [1], Minami Nouchi [1], Kazumi Sugiura [1], Ryo Murata [2], Noritsugu Abe [1], Ayano Sato [1] *, Toshihide Kato [1]

[1] Division of Farm Animal Clinical Science, School of Veterinary Medicine, Rakuno Gakuen University, 582-1 Bunkyodai-midorimachi, Ebetsu, Hokkaido 069-8501, Japan
[2] Division of Pathobiology, School of Veterinary Medicine, Rakuno Gakuen University, 582-1 Bunkyodai-midorimachi, Ebetsu, Hokkaido 069-8501, Japan
* Corresponding Author: Ayano Sato (e-mail: ayanok@rakuno.ac.jp)
(Received 14. May. 2021 / Accepted 29. Jul. 2021)

Summary

Mannheimia haemolytica serotype 1 was isolated from a dairy farm with frequent pneumonia in adult cattle. In order to investigate the cause of *M. haemolytica* serotype 1 strain showing low cefazolin (CEZ) susceptibility, the occurrence of mastitis prior to pneumonia and the use of antimicrobial agents were investigated and compared with a control farm in the same series with low pneumonia incidence. In addition, *M. haemolytica* isolates from the control farm were examined for drug susceptibilities. The annual incidence of mastitis was 1.29 and 0.55 in the study and control farms, respectively, and the incidence ratio between the two farms was 2.35, which was significantly higher in the study farm. The antimicrobial agents used for mastitis treatment at the study farm were cephalosporin-based, and consisted of 70.2 g of CEZ intramammary infusion and 129 g of CEZ systemic injection to the intramammary for off-label use. Only intramammary infusions were used on the control farm, and CEZ was administered at a dose of 12.9 g. Per head of the study farm enrollment, the amount of CEZ intramammary infusion and intramammary injectants used (4.6 g) was more than 5 times that of the control farm (0.89 g), and approximately 2.6 times the standard dosage of CEZ intramammary infusion for lactation (0.15 g/dose per container × 4 mammary glands × 3 days = 1.8 g) for cattle with 4 affected mammary glands. Also, the MIC values for CEZ of *M. haemolytica* isolated from the control farm were low. Thus, it can be inferred that excessive use of CEZ was one of the factors responsible for the decreased susceptibility of *M. haemolytica* in the study farm. Another factor could be the external invasion of CEZ low-susceptible *M. haemolytica*. However, it was inferred that it was unlikely to have been introduced from this farm, as only individuals raised on the control farm were introduced.

Key words : antimicrobial usage, drug susceptibility, *Mannheimia haemolytica*, intramammary therapy

Jpn. J. Anim. Hyg. 47, 85～90 (2021)

出典　http://www.kachiku-eisei.jp/
最終責任者　Ayano SATO (Corresponding Author)

獣医生理学（Veterinary Physiology）

Hiroshi Kitamura

Professor

教授　北村　浩

Ⅰ．筆頭または責任著者　＜First or Corresponding Author＞

1）USP2-related cellular signaling and consequent pathophysiological outocomes
Kitamura H, Hashimoto M.
Int. J. Mol. Sci. 22: 1209. 2021. doi: 10.3390/ijms22031209.

Ⅱ．その他＜Others＞

International Journal of
Molecular Sciences

MDPI

Review

USP2-Related Cellular Signaling and Consequent Pathophysiological Outcomes

Hiroshi Kitamura * and Mayuko Hashimoto

Laboratory of Veterinary Physiology, School of Veterinary Medicine, Rakuno Gakuen University, Ebetsu, Hokkaido 069-8501, Japan; s21841005@stu.rakuno.ac.jp
* Correspondence: kitmr@rakuno.ac.jp; Tel.: +81-11-388-4781; Fax: +81-11-387-5890

Abstract: Ubiquitin specific protease (USP) 2 is a multifunctional deubiquitinating enzyme. USP2 modulates cell cycle progression, and therefore carcinogenesis, via the deubiquitination of cyclins and Aurora-A. Other tumorigenic molecules, including epidermal growth factor and fatty acid synthase, are also targets for USP2. USP2 additionally prevents p53 signaling. On the other hand, USP2 functions as a key component of the CLOCK/BMAL1 complex and participates in rhythmic gene expression in the suprachiasmatic nucleus and liver. USP2 variants influence energy metabolism by controlling hepatic gluconeogenesis, hepatic cholesterol uptake, adipose tissue inflammation, and subsequent systemic insulin sensitivity. USP2 also has the potential to promote surface expression of ion channels in renal and intestinal epithelial cells. In addition to modifying the production of cytokines in immune cells, USP2 also modulates the signaling molecules that are involved in cytokine signaling in the target cells. *Usp2* knockout mice exhibit changes in locomotion and male fertility, which suggest roles for USP2 in the central nervous system and male genital tract, respectively. In this review, we summarize the cellular events with USP2 contributions and list the signaling molecules that are upstream or downstream of USP2. Additionally, we describe phenotypic differences found in the in vitro and in vivo experimental models.

Keywords: ubiquitin-specific protease; tumorigenesis; cell cycle; inflammation; circadian clock; metabolic disorder; brain; fertility; deubiquitination; ion balance

check for updates

Citation: Kitamura, H.; Hashimoto, M. USP2-Related Cellular Signaling and Consequent Pathophysiological Outcomes. *Int. J. Mol. Sci.* **2021**, *22*, 1209. https://doi.org/10.3390/ijms22031209

出典　doi: 10.3390/ijms22031209.
https://www.mdpi.com/1422-0067/22/3/1209/htm

最終責任者　Hiroshi Kitamura (First Author and Corresponding Author)

獣医ウイルス学（Veterinary Virology）

Rikio Kirisawa

Professor

教授　桐澤　力雄

Ⅰ．筆頭または責任著者　＜First or Corresponding Author＞

Ⅱ．その他＜Others＞

1) Yokoyama T, Nishimura T, Uwamino Y, Kosaki K, Furusaki K, Onishi R, Onodera T, Haritani M, Sugiura K, **Kirisawa R,** Hasegawa N. Virucidal Effect of the Mesoscopic Structure of CAC-717 on Severe Acute Respiratory Syndrome Coronavirus-2. *Microorganisms* 9: 2096. 2021. doi: 10.3390/microorganisms9102096.

microorganisms

MDPI

Communication

Virucidal Effect of the Mesoscopic Structure of CAC-717 on Severe Acute Respiratory Syndrome Coronavirus-2

Takashi Yokoyama [1,2,*], Tomoyasu Nishimura [2], Yoshifumi Uwamino [2], Kenjiro Kosaki [3], Koichi Furusaki [4], Rumiko Onishi [5], Takashi Onodera [1], Makoto Haritani [1,6], Katsuaki Sugiura [1,7], Rikio Kirisawa [8] and Naoki Hasegawa [2]

1 Environmental Science for Sustainable Development, Graduate School of Agricultural and Life Sciences, The University of Tokyo, Tokyo 113-8657, Japan; atonode@g.ecc.u-tokyo.ac.jp (T.O.); aharitani@g.ecc.u-tokyo.ac.jp (M.H.); aksugiur@g.ecc.u-tokyo.ac.jp (K.S.)
2 Department of Infectious Diseases, Keio University School of Medicine, Tokyo 160-8582, Japan; nishimura@keio.jp (T.N.); uwamino@keio.jp (Y.U.); n-hasegawa@z8.keio.jp (N.H.)
3 Center for Medical Genetics, Keio University School of Medicine, Tokyo 160-8582, Japan; kkosaki@keio.jp
4 Mineral Activation Technical Research Center, Kumamoto 865-0023, Japan; furusaki@ind.bbiq.jp
5 Santa Mineral Co., Ltd., Tokyo 105-0013, Japan; rumiko@santa-mineral.co.jp
6 School of Veterinary Nursing and Technology, Faculty of Veterinary Science, Nippon Veterinary and Life Science University, Tokyo 180-8602, Japan
7 Nippon Institute for Biological Science, Tokyo 198-0024, Japan
8 Laboratory of Veterinary Virology, Department of Pathobiology, School of Veterinary Medicine, Rakuno Gakuen University, Hokkaido 069-8501, Japan; r-kirisa@rakuno.ac.jp
* Correspondence: ayokoyam@g.ecc.u-tokyo.ac.jp

check for updates

Citation: Yokoyama, T.; Nishimura, T.; Uwamino, Y.; Kosaki, K.; Furusaki, K.; Onishi, R.; Onodera, T.; Haritani, M.; Sugiura, K.; Kirisawa, R.; et al. Virucidal Effect of the Mesoscopic Structure of CAC-717 on Severe Acute Respiratory Syndrome Coronavirus-2. *Microorganisms* 2021, 9, 2096. https://doi.org/10.3390/microorganisms9102096

Academic Editor: Mario Clerici

Received: 13 September 2021
Accepted: 30 September 2021
Published: 4 October 2021

Abstract: Here, the virucidal effect of calcium bicarbonate with a mesoscopic structure (CAC-717) on severe acute respiratory syndrome coronavirus-2 (SARS-CoV-2) was determined. Assays showed that CAC-717 had a strong virucidal effect on all examined SARS-CoV-2 isolates, including variant strains. The viral infectivity decreased within 15 s, and the virucidal activity of CAC-717 at a 1:49 ratio was similar to that of ethanol disinfectant. CAC-717 neutralization eliminated this virucidal effect, indicating that the alkaline condition of CAC-717 is important for virus inactivation and is an indicator of its mesoscopic structure and virucidal activity. The virucidal effect was observed in the presence of organic matter (bovine serum albumin). CAC-717 is a non-invasive and non-flammable substance with a low environmental burden, and its usefulness as a novel disinfectant has been confirmed.

Keywords: SARS-CoV-2; disinfectant; mesoscopic structure; CAC-717

出典　doi: 10.3390/microorganisms9102096.
https://www.mdpi.com/2076-2607/9/10/2096

最終責 任者　Takashi Yokoyama (First Author and Corresponding Author)

獣医臨床病理学（Veterinary Clinicopathology）

Kazuyuki Suzuki

Professor

教授　鈴木　一由

Ⅰ．筆頭または責任著者　＜First or Corresponding Author＞

1）Diagnostic utility of measuring serum amyloid A with a latex agglutination turbidimetric immunoassay in bovine mastitis: Comparison with haptoglobin and alpha 1 acid glycoprotein.
Otsuka M, Sugiyama M, Ito T, Tsukano K, Oikawa S, **Suzuki K.**
J. Vet. Med. Sci. 83(2):329-332. 2021. doi: 10.1292/jvms.20-0550.

2）Validation of the bovine blood calcium checker as a rapid and simple measuring tool for the ionized calcium concentration in cattle.
Suzuki K, Kondo N, Takagi K, Nishikawa A, Murakami Y, Otsuka M, Tsukano K, Ikeda K, Funakura H, Yasutomi I, Kawamoto S.
J. Vet. Med. Sci. 83(5):767-774. 2021. doi: 10.1292/jvms.21-0001.

3）Effects of temporary cessation of milking following intramammary cefazolin sodium infusion on residual antibiotic in lactating dairy cows.
Sato K, Ohashi E, Tsukano K, Ikeda K, Ajito T, **Suzuki K**.
J. Vet. Med. Sci. 83(5):814-818. 2021. doi: 10.1292/jvms.20-0716.

4）Serum iron concentration is candidate inflammatory marker for respiratory diseases in beef cows.
Tsukano K, Fukuda T, Ikeda K, Sato K, **Suzuki K**.
J. Vet. Med. Sci. 83(5):824-828. 2021. doi: 10.1292/jvms.21-0051.

5）Retrospective study on the outcomes and risk factors of right paramedian abomasopexy for right abomasal disorders in 47 dairy cows.
Tsukano K, Nishi Y, Sasaki N, **Suzuki K**.
J. Vet. Med. Sci. 83(10):1521-1525. 2021. doi: 10.1292/jvms.21-0123.

Ⅱ．その他＜Others＞

1) *Clistobothrium* sp. (Cestoda: Tetraphylidea) in oarfish (*Regalecus russelii*) stranded on the coast of Akita Prefecture, Japan.
Hirata H, Mibe Y, Ono K, Shizuno S, **Suzuki K**, Asakawa M.
J. Vet. Med. Sci. 83(10): 1590-1592. 2021. doi: 10.1292/jvms.21-0317.

2) The effect of sodium butyrate supplementation on ruminal and fecal pH and serum lipopolysaccharide-binding protein after ruminal acidosis challenge in nonlactating cows.
Fukumori R, Ikeno R, Izumi K, Doi K, Otsuka M, **Suzuki K**, Oikawa S.
Anim. Sci. J. 92(1):e13673. 2021. doi: 10.1111/asj.13673.

The Journal of Veterinary Medical Science

NOTE

Internal Medicine

Diagnostic utility of measuring serum amyloid A with a latex agglutination turbidimetric immunoassay in bovine mastitis: Comparison with haptoglobin and alpha 1 acid glycoprotein

Marina OTSUKA[1)], Mieko SUGIYAMA[2)], Takaaki ITO[3)], Kenji TSUKANO[4)], Shin OIKAWA[1)] and Kazuyuki SUZUKI[1)]*

[1)]School of Veterinary Medicine, Rakuno Gakuen University, 582 Bunkyodai-Midorimachi, Ebetsu, Hokkaido 069-8501, Japan
[2)]Ehime Agricultural Mutual Aid Association, 4-4-2 Nibancho, Matsuyama, Ehime 790-0002, Japan
[3)]Aichi Agricultural Mutual Aid Association, 2-1-11 Marunouchi, Nakaku, Nagoya 460-0002, Japan
[4)]Minami-Hokkaido Agricultural Mutual Aid Association, 74-2 Higashimae, Hokuto, Hokkaido 041-1214, Japan

J. Vet. Med. Sci.
83(2): 329–332, 2021
doi: 10.1292/jvms.20-0550

Received: 14 September 2020
Accepted: 17 December 2020
Advanced Epub:
29 December 2020

ABSTRACT. This study established the precision and accuracy of a modified latex agglutination turbidimetric immunoassay (LATIA) reagent, and evaluated the ability of the measurement of serum amyloid A (SAA) compared to haptoglobin and α1-acid glycoprotein, which are acute phase proteins (APPs), for diagnosis of clinical mastitis. Concentrations of APPs in cows with mastitis were significantly higher than those in healthy cow. Only the plasma SAA concentration in cows with clinical mastitis (44.90 mg/l; n=15) was significantly higher than that in those with subclinical mastitis (10.70 mg/l; n=16), enabling their diagnosis in contrast to other APPs. Thus, the SAA assay using a LATIA reagent is useful in assessing mastitis severity due to its higher sensitivity and specificity than other APP assays.

KEY WORDS: acute phase protein, bovine, inflammation, mastitis, serum amyloid A

出典　doi: 10.1292/jvms.20-0550.
https://www.jstage.jst.go.jp/article/jvms/83/2/83_20-0550/_pdf/-char/ja

最終責任者　Kazuyuki Suzuki (Corresponding Author)

The Journal of Veterinary Medical Science

FULL PAPER
Clinical Pathology

Validation of the bovine blood calcium checker as a rapid and simple measuring tool for the ionized calcium concentration in cattle

Kazuyuki SUZUKI[1)]*, Nao KONDO[2)], Kaede TAKAGI[3)], Akitoyo NISHIKAWA[4)], Yoshiki MURAKAMI[1)], Marina OTSUKA[1)], Kenji TSUKANO[1)], Keiko IKEDA[1)], Hisashi FUNAKURA[3)], Ichiro YASUTOMI[5)] and Satoshi KAWAMOTO[1)]

[1)]The School of Veterinary Medicine, Rakuno Gakuen University, 582 Midorimachi, Bunnkyoudai, Ebetsu, Hokkaido 069-8501, Japan
[2)]Arekinai Livestock Veterinary Clinic, Hokkaido Higashi Agricultural Mutual Aid Association, 177-3 Kita1senn, Aza Arekinaigenya, Shibecha-cho, Kawakami-gun, Hokkaido 088-2272, Japan
[3)]Ishigaki Bovine Hospital, Okinawa 907-0024, Japan
[4)]Hamanaka Livestock Veterinary Clinic, Hokkaido Higashi Agricultural Mutual Aid Association, 33 Chanai-Midori, Hamanaka-cho, Akkeshi-gun, Hokkaido 088-1361, Japan
[5)]Yubetsu Herd Management Service, 450-3 Baro, Yubetsu, Monbetsu-gun, Hokkaido 093-0731, Japan

ABSTRACT. Point-of-care (POC) devices that veterinary practitioners can use to easily and rapidly measure blood ionized calcium (iCa) levels in cows immediately after withdrawing a blood sample on the dairy farm are needed. Aims of present studies was to compare the commercially available ion-selective electrode handheld iCa meter (bovine blood iCa checker) with the benchtop blood gas analyzer GEM premier 3500 and handheld analyzer i-STAT 1. Sixty-two paired-point whole blood samples were obtained from three cows with hypocalcemia experimentally induced by Na_2-EDTA infusion. Whole blood samples were also obtained from the 36 cows kept on a farm in field conditions. The results using the bovine blood iCa checker correlated with those using the GEM premier 3500 and i-STAT 1. Bovine blood iCa checker was "compatible" with the GEM premier 3500 and i-STAT 1 because the frequency of differences between the measurements within ± 20% of the mean were 100% (65/65, >75%) and 90.8% (59/65, >75%), respectively. In the field trial, the blood iCa concentration measured by the bovine blood Ca checker was significantly positively correlated with that measured by the i-STAT 1 portable analyzer. Bovine blood iCa checker was "compatible" with the i-STAT 1 because the frequency of differences between the measurements within ± 20% of the mean was 100% (36/36, >75%). Results from these findings, the bovine blood iCa checker may be applied as a simplified system to measure the iCa concentration in bovine whole blood.

KEY WORDS: cattle, hypocalcemia, ion-selective electrode, ionized calcium, point-of-care

J. Vet. Med. Sci.
83(5): 767–774, 2021
doi: 10.1292/jvms.21-0001

Received: 4 January 2021
Accepted: 18 March 2021
Advanced Epub:
26 March 2021

出典　doi: 10.1292/jvms.21-0001.
https://www.jstage.jst.go.jp/article/jvms/83/5/83_21-0001/_pdf/-char/en

最終責任者　Kazuyuki Suzuki (First Author and Corresponding Author)

The Journal of Veterinary Medical Science

FULL PAPER
Internal Medicine

Effects of temporary cessation of milking following intramammary cefazolin sodium infusion on residual antibiotic in lactating dairy cows

Kaoru SATO[1,5], Eiichi OHASHI[2], Kenji TSUKANO[3], Keiko IKEDA[5], Tadaharu AJITO[4] and Kazuyuki SUZUKI[5]*

[1]Large Animal Technical Services Team, Nippon Zenyaku Kogyo Tokyo Branch Office, 1-2-5 Kandasurugadai, Chiyoda, Tokyo 101-0062, Japan
[2]Manufacturing Division, Nippon Zenyaku Kogyo, 1-1 Tairanoue, Sasagawa, Asakamachi, Koriyama, Fukushima 963-0196, Japan
[3]Minami-Hokkaido Agricultural Mutual Aid Association, 74-2 Higashimae, 14 Hokuto, Hokkaido 041-1214, Japan
[4]Faculty of Veterinary Medicine, Nippon Veterinary & Life Science University, 1-7-1 Kyonancho Musashino-shi, Tokyo 180-8602, Japan
[5]School of Veterinary Medicine, Rakuno Gakuen University, 582 Bunkyodai-Midorimachi, Ebetsu, Hokkaido 069-8501, Japan

ABSTRACT. The aims of studies were to estimate the withdrawal period of antibiotic from milk after the intramammary infusion of cefazolin sodium (CEZ) in cows with difficulties in frequent milk discharge due to disease such as teat injury. The period was compared among cows milked twice a day after 150 or 450 mg of CEZ were administered to all quarters (Study 1, 2) and the cows in which milking of front-right quarter was ceased for five days after administration of these infusions to only that quarter (Study 3). In Studies 1 and 2, the median of 17.66 µg/ml and 83.18 µg/ml of CEZ were detected in the samples of first milking after intramammary administration, respectively; however, there was no residual antibiotic by 72 hr in all cows. In Study 3, the median of 1.96 µg/ml of CEZ was detected in the sample after the resumption of milking at 120 hr, and the residual was eliminated by 174 hr. The withdrawal period may be prolonged by the cessation of milking after administration, and the period is the total time from cessation to 72 hr after the resumption of milking.

KEY WORDS: cefazolin sodium, intramammary administration, residue, temporary cessation of milking, withdrawal period

J. Vet. Med. Sci.
83(5): 814–818, 2021
doi: 10.1292/jvms.20-0716

Received: 17 December 2020
Accepted: 12 March 2021
Advanced Epub:
26 March 2021

出典　doi: 10.1292/jvms.20-0716.
https://www.jstage.jst.go.jp/article/jvms/83/5/83_20-0716/_pdf/-char/en

最終責任者　Kazuyuki Suzuki (Corresponding Author)

The Journal of Veterinary Medical Science

NOTE

Internal Medicine

Serum iron concentration is candidate inflammatory marker for respiratory diseases in beef cows

Kenji TSUKANO[1)], Tatsuya FUKUDA[2)], Keiko IKEDA[2)], Kaoru SATO[2)] and Kazuyuki SUZUKI[2)]*

[1)]Minami-Hokkaido Agricultural Mutual Aid Association, 74-2 Higashimae, Hokuto, Hokkaido 041-1214, Japan
[2)]School of Veterinary Medicine, Rakuno Gakuen University, 582 Midorimachi, Bunnkyoudai, Ebetsu, Hokkaido 069-8501, Japan

J. Vet. Med. Sci.
83(5): 824–828, 2021
doi: 10.1292/jvms.21-0051

Received: 30 January 2021
Accepted: 9 March 2021
Advanced Epub:
18 March 2021

ABSTRACT. We hypothesized that the serum iron (Fe) concentration in cows with respiratory diseases is a satisfactory substitute for major inflammatory markers such as haptoglobin (HPT) and serum amyloid A (SAA). Twenty Japanese Black cows aged 279.6 ± 120.0 days were enrolled, and divided into respiratory diseases and control groups based on the presence of clinical findings of respiratory diseases. As a result, area under the receiver operating characteristic curves for plasma HPT, SAA and serum Fe concentrations for respiratory disease-associated systemic inflammation were excellent, at 1.00, 0.96 and 0.97, respectively. Therefore we confirmed that the serum Fe concentration is a satisfactory substitute for HPT and SAA in beef cows with respiratory diseases.

KEY WORDS: beef cattle, haptoglobin, iron, respiratory disease, serum amyloid A

出典　doi: 10.1292/jvms.21-0051.
https://www.jstage.jst.go.jp/article/jvms/83/5/83_21-0051/_pdf/-char/ja

最終責任者　Kazuyuki Suzuki (Corresponding Author)

The Journal of Veterinary Medical Science

NOTE

Surgery

Retrospective study on the outcomes and risk factors of right paramedian abomasopexy for right abomasal disorders in 47 dairy cows

Kenji TSUKANO[1)], Yasunobu NISHI[2)], Naoki SASAKI[2)] and Kazuyuki SUZUKI[3)]*

[1)]Minami-Hokkaido Agricultural Mutual Aid Association, 74-2 Higashimae, Hokuto, Hokkaido 041-1214, Japan
[2)]Joint Faculty of Veterinary Medicine, Yamaguchi University, 1677-1 Yoshida, Yamaguchi, Yamaguchi 753-8515, Japan
[3)]School of Veterinary Medicine, Rakuno Gakuen University, 582 Midorimati, Bunnkyoudai, Ebetsu, Hokkaido 069-8501, Japan

J. Vet. Med. Sci.
83(10): 1521–1525, 2021
doi: 10.1292/jvms.21-0123

Received: 28 February 2021
Accepted: 27 July 2021
Advanced Epub:
18 September 2021

ABSTRACT. Very few epidemiologic studies have verified the utility of the right paramedian abomasopexy (RPA) technique in cows with right abomasal disorders. This study aimed to investigate the outcomes and risk factors for non-survival in the herd within 30 days of surgery in cows with right abomasal disorders who underwent the RPA technique. Forty-seven Holstein cows with right abomasal disorders (25 with right abomasal displacement [RDA] and 22 with right abomasal volvulus [RAV]) were included. Twenty-two cows with RDA (22/25, 88.0%) and 10 cows with RAV (10/22, 45.5%) survived at 30 days post-surgery. Multivariate logistic regression analysis indicated that hyponatremia, hypokalemia, and the presence of abomasal volvulus were the major risk factors associated with non-survival.

KEY WORDS: cow, mortality, right abomasal displacement, right abomasal volvulus, right paramedian abomasopexy

出典　doi: 10.1292/jvms.21-0123.
https://www.jstage.jst.go.jp/article/jvms/83/10/83_21-0123/_pdf/-char/ja

最終責任者　Kazuyuki Suzuki (Corresponding Author)

The Journal of Veterinary Medical Science

NOTE

Wildlife Science

Clistobothrium sp. (Cestoda: Tetraphyllidea) in oarfish (*Regalecus russelii*) stranded on the coast of Akita Prefecture, Japan

Haruyuki HIRATA[1)], Yuki MIBE[1)], Koji ONO[2)], Satsuki SHIZUNO[2)], Kazuyuki SUZUKI[1)] and Mitsuhiko ASAKAWA[1)]*

[1)]School of Veterinary Medicine, Rakuno Gakuen University, Hokkaido 069-8501, Japan
[2)]Oga Aquarium GAO, Akita 010-0673, Japan

J. Vet. Med. Sci.
83(10): 1590–1592, 2021
doi: 10.1292/jvms.21-0317

Received: 3 June 2021
Accepted: 17 August 2021
Advanced Epub:
2 September 2021

ABSTRACT. Oarfish (*Regalecus russelii* Cuvier) are mesopelagic fish with little known about their life history. Oarfish live in deep water, making it difficult for researchers to collect specimens; thus, records of their parasitic helminths are limited. Two plerocercoids were found for the first time in an oarfish stranded on the coast of Akita Prefecture, Japan. These plerocercoids were identified as *Clistobothrium* sp. RR-1 using morphological and molecular analyses. It was revealed that oarfish represent one of the intermediate hosts of the genus *Clistobothrium*, and large sharks are the definitive hosts for these parasites.

KEY WORDS: deep-sea fish, first record, oarfish, phylogenetic analysis, plerocercoid

出典　doi: 10.1292/jvms.21-0317.
https://www.jstage.jst.go.jp/article/jvms/83/10/83_21-0317/_article

最終責任者　Mitsuhiko Asakawa (Corresponding Author)

Received: 30 May 2021 | Revised: 27 September 2021 | Accepted: 22 November 2021
DOI: 10.1111/asj.13673

RESEARCH ARTICLE

Animal Science Journal WILEY

The effect of sodium butyrate supplementation on ruminal and fecal pH and serum lipopolysaccharide-binding protein after ruminal acidosis challenge in nonlactating cows

Rika Fukumori[1] | Rina Ikeno[1] | Kenichi Izumi[2] | Kazuya Doi[2] | Marina Otsuka[1] | Kazuyuki Suzuki[1] | Shin Oikawa[1]

[1]Department of Veterinary Medicine, School of Veterinary Medicine, Rakuno Gakuen University, Ebetsu, Japan

[2]Department of Sutainable Agricultrure, College of Agriculture, Food and Environment Sciences, Rakuno Gakuen University, Ebetsu, Japan

Correspondence
Shin Oikawa, Department of Veterinary Medicine, School of Veterinary Medicine, Rakuno Gakuen University, Ebetsu 069-8501, Japan.
Email: oishin@rakuno.ac.jp

Funding information
Japan Society for the Promotion of Science, Grant/Award Number: #18K14593

Abstract

The objective of this study was to evaluate effects of sodium-butyrate supplementation on gastrointestinal function and the inflammatory response to ruminal acidosis (RA) challenge in cows. Four nonlactating cows with a rumen cannula were assigned to two treatments in a crossover design. Treatments were ruminal administration of sodium-butyrate (BUT) or control (CON). Sodium-butyrate was provided as Gustor BP70 and administered at a butyrate dose of 0.04% per kg body weight. The CON premix was made by replacing sodium-butyrate with wheat bran. Experimental periods were 28 days long with 21-day washout period separating the treatments. On Day 25 of each period, corn starch was ruminally administered at 0.7% per kg body weight as RA challenge. After RA challenge, ruminal pH was lower, and endotoxin concentration was higher for cows provided with BUT than those with CON, but the increase in fecal starch and the decrease in fecal pH were attenuated by BUT. The effect of butyrate supplementation on serum lipopolysaccharide-binding protein after RA challenge was not found. From these findings, butyrate supplementation mitigated rectal acidosis by reducing the flux of fermentable carbohydrate into the large intestine. An anti-inflammatory effect of butyrate was not observed, possibly due to lower pH and higher endotoxin concentration in the rumen.

KEYWORDS
butyric acid, endotoxin, lipopolysaccharide-binding protein, ruminal acidosis

出典　doi: 10.1111/asj.13673.
https://onlinelibrary.wiley.com/doi/epdf/10.1111/asj.13673
最終責任者　Shin Oikawa (Corresponding Author)

生産動物内科学（Farm Animal Internal Medicine）

Motoshi Tajima

Professor

教授　田島　誉士

Ⅰ．筆頭または責任著者　＜First or Corresponding Author＞

1）Prevalence of bovine viral diarrhea virus infection in Japan: 2000-2019.
Tajima, M.
Front. Vet. Sci. 8, 2021.　doi: 10.3389/fvets.2021.667933

2) Comparison of distal forelimb conformations between Japanese Black and Holstein-Friesian newborn calves.
Sato, A., Kato, T. **Tajima, M.**
J. Vet. Med. Sci. 83(6); 940-946, 2021.　doi: 10.1292/jvms.20-0615

Ⅱ．その他＜Others＞

frontiers in Veterinary Science

DATA REPORT
published: 30 April 2021
doi: 10.3389/fvets.2021.667933

Prevalence of Bovine Viral Diarrhea Virus Infection in Japan: 2000–2019

*Motoshi Tajima**

Department of Large Animal Clinical Sciences, School of Veterinary Medicine, Rakuno Gakuen University, Ebetsu, Japan

Keywords: bovine viral diarrhea, BVD, control, prevalence, vaccination

OPEN ACCESS

Edited by:
Julia Francis Ridpath, Independent Researcher, Gilbert, United States

Reviewed by:
Florencia Celeste Mansilla, Instituto Nacional de Tecnologia Agropecuaria (INTA), Argentina
Chris Chase, South Dakota State University, United States

***Correspondence:**
Motoshi Tajima
motoshi@rakuno.ac.jp

Specialty section:
This article was submitted to Veterinary Epidemiology and Economics, a section of the journal Frontiers in Veterinary Science

Received: *15 February 2021*
Accepted: *07 April 2021*
Published: *30 April 2021*

Citation:
Tajima M (2021) Prevalence of Bovine Viral Diarrhea Virus Infection in Japan: 2000–2019. Front. Vet. Sci. 8:667933. doi: 10.3389/fvets.2021.667933

INTRODUCTION

Nearly 4 million cattle are fed in Japan as dairy and beef cattle. More than 50% of dairy cattle (800,000 cows) and 20% of beef cattle (500,000) are fed in Hokkaido, Japan. Young and adult cows in addition to dairy products are delivered throughout Japan from Hokkaido. Moreover, many dairy cows are brought to Hokkaido as calves, and return to their home farm when pregnant. Vaccinations for some diseases are compulsory to prevent infectious diseases when cows move feeding places and particularly when they are introduced to common grazing farms.

Twenty-seven ruminant, equine, swine, avian, and bee diseases are designated as regulated domestic animal infectious diseases (1) as is paratuberculosis (Johne's disease; JD). Another 71 diseases in domestic animals have been monitored as non-regulated diseases since 1998 (2). Bovine viral diarrhea (BVD) and enzootic bovine leukemia (EBL) are non-regulated diseases. The prevalence of JD has been periodically monitored for a long time, and eradication programs are ongoing and also being developed.

Typical clinical symptoms are exhibited by JD-affected animals, and its spread in farms is a serious issue. In Hokkaido, a compulsory examination for the antibody against *Mycobacterium avium spp. paratuberculosis*, the pathogen of JD, is performed once every 5 years by all farms including dairy and beef cattle. Surveillance for a few decades cannot eradicate JD because the pathogen may remain latent in herds for long periods of time and difficulties are associated with its detection in the early stage of the disease. Although bovine leukemia virus (BLV), the pathogen of EBL, is latent in herds, preventive management is possible.

Bovine viral diarrhea virus (BVDV) is associated with various subclinical to fatal diseases. Persistent infection (PI) has been recognized as a serious threat to the cattle industry. PI animals can then subsequently develop mucosal disease which is often fatal. The immune dysfunction associated with BVDV infection has been associated with bovine respiratory disease complex and hemorrhagic syndrome. These disease syndromes have a serious economic impact on cattle producers.

Vaccines are useful tools for the protection of infectious diseases. BVDV is the only one of the three endemic diseases (BVD, EBL, and JD) that cattle are vaccinated for in Japan. The control of PI by BVDV is a key point for its eradication; however, difficulties are associated with detecting PI animals because not all infected animals exhibit the typical clinical symptoms and fetal infection cannot be estimated. Moreover, it is difficult to discriminate whether the immunization status was achieved by vaccination or infection. An update on BVD in Japan is presented in this review.

PREVALENCE

The number of reported cases of BVD, JD, and EBL in Japan between 2000 and 2019 varied by pathogen (**Figure 1**) (1, 2). The number of cattle affected with JD has remained relatively constant every year, ranging between 405 and 1,179 cases in 2012 and 2006, respectively, with a mean of 746 cases per year. The reported number of EBL cases has increased more than those of the JD and

出典　doi: 10.3389/fvets.2021.667933
https:// doi.org/10.3389/fvets.2021.667933
最終責任者　Motoshi Tajima (First and Corresponding Author)

The Journal of Veterinary Medical Science

FULL PAPER
Surgery

Comparison of distal forelimb conformations between Japanese Black and Holstein-Friesian newborn calves

Ayano SATO[1], Toshihide KATO[1] and Motoshi TAJIMA[1]*

[1]School of Veterinary Medicine, Rakuno Gakuen University, Ebetsu, Hokkaido 069-8501, Japan

ABSTRACT. Flexural and hyperextension deformities are congenital problems in calves. We, therefore, aimed to investigate the distal limb conformation in 1 day- and 28-day-old female Holstein-Friesian (HF) calves (n=21), male Japanese Black (JB) calves (n=15), and female JB calves (n=15). The claw angle of the forelimb dorsal claw wall in a standing position and recorded other parameters, including body weight, withers height, circumference of forelimbs, and flexor tendon thickness in the forelimbs, were measured and compared these between the three groups. At 1 day old, the mean claw angles were 51.1° in female HF calves, 47.0° in male JB calves, and 41.8° in female JB calves; the 95% confidence intervals (CIs) of the claw angles showed large distributions in all three groups. One female HF and one male JB calves showed mild flexural deformity, whereas four JB calves showed hyperextension deformity. At 28 days old, the mean claw angles were 51.7° in female HF calves, 51.2° in male JB calves, and 48.4° in female JB calves; the 95% CIs of the claw angles showed smaller distributions than those at 1 day old in all groups. For all groups, the limb deformities had improved without treatment at 28 days old. As a feature of the breed, female JB calves were apt to show hyperextended deformities inversely proportional to the body weight. These limb deformities healed spontaneously and were thought to be physiological.

KEY WORDS: breed, calf, conformation, forelimb

J. Vet. Med. Sci.
83(6): 940–946, 2021
doi: 10.1292/jvms.20-0615

Received: 21 October 2020
Accepted: 12 April 2021
Advanced Epub:
30 April 2021

出典　doi: 10.1292/jvms.20-0615
https://doi.org/10.1292/jvms.20-0615

最終責任者　Motoshi Tajima (Corresponding Author)

獣医薬理学（Veterinary Pharmacology）

Hiroki Teraoka

Professor

教授　寺岡　宏樹

Ⅰ．筆頭または責任著者　＜First or Corresponding Author＞

1）Origin of a pair of red-crowned cranes (*Grus japonensis*) found in Sarobetsu Wetland, northwestern Hokkaido, Japan: a possible crossbreeding between the island and the mainland population.
Kawasaki E, Hasebe M, Hwang J-H, Kim E-Y, Lee K, Momose K, **Teraoka H.**
J Vet Med Sci. 2021. doi: 10.1292/jvms.21-0500.

2）Oxidative stress inducers potentiate 2,3,7,8-tetrachlorodibenzo-*p*-dioxin-mediated pre-cardiac edema in larval zebrafish.
Tanaka K, Adachi H, Akasaka H, Tamaoki J, Fuse Y, Kobayashi M, Kitazawa T, **Teraoka H**.
J Vet Med Sci. 2021. 83: 1050-1058. doi: 10.1292/jvms.21-0081.

3) Middle upper beak fracture in a Red-crowned crane that completely recovered with external skeletal fixation.
Iima H, **Teraoka H**.
J Vet Med Sci. 2021.83: 742-745. doi: 10.1292/jvms.20-0565.

Ⅱ．その他＜Others＞

1) Pheasant motilin, its distribution and gastrointestinal contractility-stimulating action in the pheasant.
Zhang S, Kaiya H, **Teraoka H**, Kitazawa T.
Gen Comp Endocrinol. 2021. 314:113897. doi: 10.1016/j.ygcen.2021.113897. Epub 2021 Sep 8.

2) Motilin- and ghrelin-induced contractions in isolated gastrointestinal strips from three species of frogs.
Zhang S, **Teraoka H**, Kaiya H, Kitazawa T.
Gen Comp Endocrinol. 2021. 300:113649. doi: 10.1016/j.ygcen.2020.113649.

The Journal of Veterinary Medical Science

NOTE

Wildlife Science

Origin of a pair of red-crowned cranes (*Grus japonensis*) found in Sarobetsu Wetland, northwestern Hokkaido, Japan: a possible crossbreeding between the island and the mainland population

Erika KAWASAKI[1)], Makoto HASEBE[2)], Ji-Hee HWANG[3)], Eun-Young KIM[3)], Kisup LEE[4)], Kunikazu MOMOSE[5)] and Hiroki TERAOKA[1,5)]*

[1)]School of Veterinary Medicine, Rakuno Gakuen University, Ebetsu, Hokkaio 069-8501, Japan
[2)]NPO Sarobetsu Eco Network, Toyotomi, Hokkaido 098-4100, Japan
[3)]Department of Life and Nanopharmaceutical Science, Kyung Hee University, Seoul 130-701, South Korea
[4)]Waterbird Network Korea, Seoul 110-776, South Korea
[5)]NPO Red-crowned Crane Conservancy, Kushiro, Hokkaido 085-0036, Japan

J. Vet. Med. Sci.
84(2): **–**, 2022
doi: 10.1292/jvms.21-0500

Received: 15 September 2021
Accepted: 13 December 2021
Advanced Epub:
27 December 2021

ABSTRACT. Red-crowned cranes *Grus japonensis*, which are an endangered species, have two separate populations, a mainland population in the Eurasian continent and an island population in eastern Hokkaido, Japan. Island cranes showed three haplotypes (Gj1, Gj2 and Gj13), whereas ten haplotypes (Gj3-Gj12) were confirmed in captive cranes and stray cranes. We found Gj5 haplotype in feathers of two cranes as well as four new haplotypes in seven wild crane feathers collected in South Korea. We also found feathers in the nest in Sarobetsu Wetland in northwestern Hokkaido. While the haplotype of female-derived feathers was Gj2, that of male-derived feathers was Gj5. The results suggest that there has been crossbreeding between cranes in the island population and cranes in the mainland population.

KEY WORDS: genetic diversity, *Grus japonensis*, Hokkaido, east Eurasia, Red-crowned crane

出典　doi: 10.1292/jvms.21-0500.
https://doi.org/10.1292/jvms.21-0500

最終責任者　Hiroki Teraoka (Corresponding Author)

The Journal of Veterinary Medical Science

FULL PAPER
Toxicology

Oxidative stress inducers potentiate 2,3,7,8-tetrachlorodibenzo-*p*-dioxin-mediated pre-cardiac edema in larval zebrafish

Katsuki TANAKA[1)], Hikaru ADACHI[1)], Hironobu AKASAKA[1)], Junya TAMAOKI[2)], Yuji FUSE[2)], Makoto KOBAYASHI[2)], Takio KITAZAWA[1)] and Hiroki TERAOKA[1)]*

[1)]School of Veterinary Medicine, Rakuno Gakuen University, Ebetsu, Hokkaido 069-8501, Japan
[2)]Department of Molecular and Developmental Biology, Faculty of Medicine, University of Tsukuba, Tsukuba, Ibaraki 305-8575, Japan

ABSTRACT. We reported the involvement of oxidative stress and prostaglandins including thromboxane and prostacyclin in pre-cardiac edema (early edema) caused by 2,3,7,8-tetrachlorodibenzo-*p*-dioxin (TCDD). While the involvement of oxidative stress in TCDD-induced toxicity has been frequently reported, the mechanism of its action is still unclear. In the present study, oxidative stress inducers including paraquat, hydrogen peroxide (H_2O_2) and rotenone augmented early edema (edema) induced by a low concentration of TCDD (0.1 ppb) at 55 hr post fertilization (hpf), while each of them alone did not cause edema. Edema caused by TCDD plus oxidative stress inducers was almost abolished by antioxidants, an antagonist for thromboxane receptor (ICI-192,605) and an agonist for prostacyclin receptor (beraprost), suggesting that the site of action of these inducers was in the regular signaling pathway after activation of aryl hydrocarbon receptor type 2 (AHR2) by TCDD. Oxidative stress inducers also enhanced edema caused by an agonist for the thromboxane receptor (U46619), and the enhancement was also inhibited by antioxidants. Sulforaphane and auranofin, activators of Nrf2 that is a master regulator of anti-oxidative response, did not affect U46619-evoked edema but almost abolished TCDD-induced edema and potentiation by paraquat in both TCDD- and U46619-induced edema. Taken together, the results suggest that oxidative stress augments pre-cardiac edema caused by TCDD via activation of thromboxane receptor-mediated signaling in developing zebrafish. As paraquat and other oxidative stress inducers used also are environmental pollutants, interaction between dioxin-like compounds and exogenous source of oxidative stress should also be considered.

KEY WORDS: dioxin, edema, oxidative stress, prostaglandin, zebrafish

J. Vet. Med. Sci.
83(7): 1050–1058, 2021
doi: 10.1292/jvms.21-0081

Received: 14 February 2021
Accepted: 10 May 2021
Advanced Epub:
24 May 2021

出典　doi: 10.1292/jvms.21-0081.
https://www.jstage.jst.go.jp/article/jvms/83/7/83_21-0081/_pdf/-char/en

最終責任者　Hiroki Teraoka (Corresponding Author)

The Journal of Veterinary Medical Science

NOTE

Wildlife Science

Middle upper beak fracture in a Red-crowned crane that completely recovered with external skeletal fixation

Hiroko IIMA[1)] and Hiroki TERAOKA[2,3)]*

[1)]Kushiro Zoo, Kushiro, Hokkaido 085-0204, Japan
[2)]School of Veterinary Medicine, Rakuno Gakuen University, Ebetsu, Hokkaido 069-8501, Japan
[3)]NPO Red-crowned Crane Conservancy, Kushiro, Hokkaido 085-0036, Japan

J. Vet. Med. Sci.
83(4): 742–745, 2021
doi: 10.1292/jvms.20-0565

Received: 23 September 2020
Accepted: 15 February 2021
Advanced Epub:
11 March 2021

ABSTRACT. An adult Red-crowned crane in captivity that had a displaced compound fracture of the middle upper beak caused by an accident was treated by using Type I-a external skeletal fixator (ESF). The ESF that was equipped with a unilateral epoxy putty fixator and with five half-pins was fixed on the premaxilla bone. The crane with the ESF on the beak was able to feed smoothly by itself. The ESF was removed 49 days after the first surgery. Beak malocclusion, which was observed in the latter half period of fixing, spontaneously improved within one month after removal of the ESF. This is the first successful case of repair of an upper beak fracture in a Red-crowned crane.

KEY WORDS: external skeletal fixation, *Grus japonensis*, Kushiro Zoo, red-crowned crane, upper beak fracture

出典　doi: 10.1292/jvms.20-0565.
https://www.jstage.jst.go.jp/article/jvms/83/4/83_20-0565/_pdf/-char/en

最終責任者　Hiroki Teraoka (Corresponding Author)

Contents lists available at ScienceDirect

General and Comparative Endocrinology

journal homepage: www.elsevier.com/locate/ygcen

Research paper

Pheasant motilin, its distribution and gastrointestinal contractility-stimulating action in the pheasant

Shuangyi Zhang [a], Hiroyuki Kaiya [b], Hiroki Teraoka [a], Takio Kitazawa [a,*]

[a] School of Veterinary Medicine, Rakuno Gakuen University, Ebetsu, Hokkaido 069-8501, Japan
[b] Department of Biochemistry, National Cerebral and Cardiovascular Center Research Institute, Suita, Osaka 565-8565, Japan

ARTICLE INFO

Keywords:
Pheasant
Motilin
Distribution
Gastrointestinal tract
Contraction

ABSTRACT

Previously, pheasant motilin was identified as a 22-amino acid peptide with a sequence of FVPFFTQSDI QKMQEKERIK GQ. In the present study, the distribution of pheasant motilin mRNA was determined and compared with that of ghrelin, a motilin-related peptide. The effects of pheasant motilin on the cognate gastrointestinal (GI) muscle strips were also examined in an *in vitro* contraction study. The expression of pheasant motilin mRNA was highest in the small intestine (duodenum, jejunum and ileum), moderate in the colon and very low in the brain, lung, heart, pancreas, esophagus, proventriculus, gizzard and caecum, and this distribution was in contrast with that of ghrelin mRNA. Pheasant motilin caused contraction of the cognate GI tract in a region-dependent manner, similar to chicken motilin. The contraction in the small intestine was large and was not affected by atropine. In contrast, contraction in the proventriculus was small and was decreased by atropine. The crop and colon were insensitive to pheasant motilin. Neither GM109 nor MA2029, mammalian motilin receptor antagonists inhibited the contractions of pheasant motilin. Erythromycin was ineffective in the pheasant ileum, although it caused contraction of the rabbit duodenum. These results indicate that pheasant motilin caused contraction through an action on smooth muscles in the small intestine and an action on enteric cholinergic nerves in the proventriculus. This high responsiveness of the small intestine suggests that motilin is a regulator of small intestinal motility in avians, and the characteristic of the motilin receptor in the pheasant might be different from that in mammals, as is that in chickens.

出典　doi: 10.1016/j.ygcen.2021.113897.
https://doi.org/10.1016/j.ygcen.2021.113897

最終責任者　Takio Kitazawa　(Corresponding Author)

General and Comparative Endocrinology 300 (2021) 113649

Contents lists available at ScienceDirect

General and Comparative Endocrinology

journal homepage: www.elsevier.com/locate/ygcen

Research paper

Motilin- and ghrelin-induced contractions in isolated gastrointestinal strips from three species of frogs

Shuangyi Zhang [a], Hiroki Teraoka [a], Hiroyuki Kaiya [b], Takio Kitazawa [a,*]

[a] School of Veterinary Medicine, Rakuno Gakuen University, Ebetsu, Hokkaido 069-8501, Japan
[b] Department of Biochemistry, National Cerebral and Cardiovascular Center Research Institute, Suita, Osaka 564-8565, Japan

ARTICLE INFO

Keywords:
Amphibians
Frogs
Gastrointestinal contraction
Motilin
Ghrelin

ABSTRACT

Ghrelin (GHRL) and motilin (MLN), gut peptides isolated from the mucosa of the stomach and duodenum, respectively, stimulate gastrointestinal (GI) motility in mammals and birds. However, the functions of MLN and GHRL in amphibian GI tracts have not been examined in detail. To clarify the regulation of GI motility by the two peptides, the effects of human MLN and rat GHRL on contractility of isolated GI strips from three species of frogs, the black-spotted pond frog (pond frog; *Pelophylax nigromaculata*), bullfrog (*Lithobates catesbeiana*) and Western clawed frog (Xenopus; *Xenopus tropicalis*), were examined in *in vitro* experiments. The GI tract of each frog was divided into the stomach, upper intestine, middle intestine and lower intestine. Human MLN caused contractions of the stomach in the pond frog and upper intestine in the bullfrog and Xenopus, but other GI regions were insensitive to human MLN. Erythromycin did not cause contraction of the upper intestine of the bullfrog and Xenopus. Rat GHRL did not cause contraction of the stomach and small intestines in the pond frog and bullfrog, but it caused a concentration-dependent contraction in the stomach and upper intestine of Xenopus, while desacyl rat GHRL did not cause any contraction of them. In conclusion, human MLN caused the contraction of the stomach or upper intestine in the three species of frogs, but GHRL was effective only in the stomach and upper intestine of Xenopus. On the basis of these data, MLN but not GHRL causes the GI region-dependent contractions in the frogs.

出典: doi: 10.1016/j.ygcen.2020.113649.
https://doi.org/10.1016/j.ygcen.2020.113649
最終責任者: Kitazawa T（Corresponding Author）

動物生殖学（Theriogenology）

Ken Nakada

Professor

教授　中田　健

Ⅰ．筆頭または責任著者　＜First or Corresponding Author＞

Ⅱ．その他＜Others＞

1) Fertility risk factors in transferring Japanese Black embryos into dairy heifers: An epidemiological study.
Goto, A., Hayama, K., Urakawa, M., Oono, Y., Hazano, K., Kayano, M., Haneda, S., **Nakada, K.,** Gröhn, Y. T., Matsui, M.
Vet. Anim. Sci., 13:100193. 2021. doi: 10.1016/j.vas.2021.100193

2) Clinical and Correlated Responses among Steroid Hormones and Oxidant/Antioxidant Biomarkers in Pregnant, Non-Pregnant and Lactating CIDR-Pre-Synchronized Dromedaries (Camelus dromedarius).
Mohamed,R. H., Khalphallah, A., **Nakada, K.**, Elmeligy, E., Hassan, D., Ebissy, E. A., Ghandour, R. A., Mousa, S. A. and Hassaneen A. S. A.
Veterinary sciences 8(11). 2021. doi:10.3390/vetsci8110247

Veterinary and Animal Science 13 (2021) 100193

Contents lists available at ScienceDirect

Veterinary and Animal Science

journal homepage: www.elsevier.com/locate/vas

Fertility risk factors in transferring Japanese Black embryos into dairy heifers: An epidemiological study

Akira Goto [a], Koh Hayama [b], Manami Urakawa [b], Yoshio Oono [b], Ken Hazano [a], Mitsunori Kayano [c], Shingo Haneda [a], Ken Nakada [d], Yrjö Tapio Gröhn [e], Motozumi Matsui [a,*]

[a] Department of Veterinary Medicine, Obihiro University of Agriculture and Veterinary Medicine, Obihiro, Hokkaido 080-8555, Japan
[b] Zen-noh Embryo Transfer Center, Kamishihoro, Hokkaido 080-1407, Japan
[c] Research Center for Global Agromedicine, University of Agriculture and Veterinary Medicine, Obihiro, Hokkaido 080-8555, Japan
[d] Department of Veterinary Medicine, School of Veterinary Medicine, Rakuno Gakuen University, Ebetsu, Hokkaido 069-8501, Japan
[e] Section of Epidemiology, Department of Population Medicine and Diagnostic Sciences, College of Veterinary Medicine, Cornell University, NY, United States

ARTICLE INFO

Keywords:
Beef cattle
Bloodline
Embryo transfer
Japanese black
Reproductive epidemiology

ABSTRACT

The aims of this study were 1) to summarize the current status of Japanese Black (JB) embryo transfer into Holstein heifers, which is carried out on a commercial basis in Japan, and 2) to reveal fertility risk factors, including those from the environment (year and season of transfer), recipient (age, number of transfers, clinical status of the ovaries) and embryo (quality, stage, state, genetic background). We used data from 4467 JB fresh or frozen embryo transfers into Holstein heifers conducted by Zen-noh Embryo Transfer Center during 2016–2018, and the differences in fertility risk due to factors related to the environment, recipient, and embryo were statistically evaluated. Differences in fertility risk due to each variable were observed, leading to significant differences in fertility with respect to year of transfer, embryo quality, embryo state, and embryo breed. These results suggest that the fertility of JB embryos might depend on differences in genetic background. There have been no previous reports of differences in embryo fertility due to the differences among JB's bloodline combinations. In the future, overall reproductive efficiency must be monitored, including the effects of different bloodline combinations on the success of embryo recovery and transfer.

出典　doi: 10.1016/j.vas.2021.100193
https://doi.org/10.1016/j.vas.2021.100193
最終責任者　Motozumi Matsui: mmatsui@obihiro.ac.jp

veterinary sciences

MDPI

Article

Clinical and Correlated Responses among Steroid Hormones and Oxidant/Antioxidant Biomarkers in Pregnant, Non-Pregnant and Lactating CIDR-Pre-Synchronized Dromedaries (*Camelus dromedarius*)

Ragab H. Mohamed [1], Arafat Khalphallah [2,*], Ken Nakada [3], Enas Elmeligy [4], Dalia Hassan [5], Eman A. Ebissy [6], Rehab A. Ghandour [7], Sabry A. Mousa [8,*] and Ahmed S. A. Hassaneen [9]

[1] Department of Theriogenology, Obstetrics, and Artificial Insemination, Faculty of Veterinary Medicine, Aswan University, Aswan 81528, Egypt; Ragabhasan2016@gmail.com
[2] Division of Internal Medicine, Department of Animal Medicine, Faculty of Veterinary Medicine, Assiut University, Assiut 71526, Egypt
[3] Department of Theriogenology, School of Veterinary Medicine, Rakuno Gakuen University, 582 Bunkyodai-Midorimachi, Ebetsu, Hokkaido 069-8501, Japan; kenn@rakuno.ac.jp
[4] Veterinary Teaching Hospital, Faculty of Veterinary Medicine, Assiut University, Assiut 71526, Egypt; enaselmeligy@yahoo.com
[5] Department of Animal & Poultry Hygiene and Environmental Sanitation, Faculty of Veterinary Medicine, Assiut University, Assiut 71526, Egypt; daliaomran@aun.edu.eg
[6] Department of Animal Health, Desert Research Center, Maratia, Cairo 11311, Egypt; eman.ebissy@yahoo.com
[7] Department of Physiology, Faculty of Veterinary Medicine, Cairo University, Giza P.O. Box 12211, Egypt; rehabghandour1@gmail.com
[8] Division of Internal Medicine, Department of Medicine and Infectious Disease, Faculty of Veterinary Medicine, Cairo University, Giza P.O. Box 12211, Egypt
[9] Department of Theriogenology, Obstetrics and Artificial Insemination, Faculty of Veterinary Medicine, South Valley University, Qena 83523, Egypt; ahmed.hassaneen@vet.svu.edu.eg
* Correspondence: arafatvet2003@yahoo.com (A.K.); sdiamond_201011@yahoo.com (S.A.M.)

check for updates

Citation: Mohamed, R.H.; Khalphallah, A.; Nakada, K.; Elmeligy, E.; Hassan, D.; Ebissy, E.A.; Ghandour, R.A.; Mousa, S.A.; Hassaneen, A.S.A. Clinical and Correlated Responses among Steroid Hormones and Oxidant/Antioxidant Biomarkers in Pregnant, Non-Pregnant and Lactating CIDR-Pre-Synchronized Dromedaries (*Camelus dromedarius*). *Vet. Sci.* **2021**, *8*, 247. https://doi.org/10.3390/vetsci8110247

Academic Editor: Fuller Warren Bazer

Received: 12 August 2021
Accepted: 25 September 2021
Published: 21 October 2021

Publisher's Note: MDPI stays neutral with regard to jurisdictional claims in published maps and institutional affiliations.

Copyright: © 2021 by the authors. Licensee MDPI, Basel, Switzerland. This article is an open access article distributed under the terms and conditions of the Creative Commons Attribution (CC BY) license (https://creativecommons.org/licenses/by/4.0/).

Abstract: Overproduction of free radicals is controlled by antioxidant defense mechanisms. These defense mechanisms are achieved by antioxidant enzymes such as catalase (CAT). The current study aimed to assess the changes in steroid hormones, oxidant/antioxidants biomarkers, lipid profiles/liver functions indices, renal function biomarkers and minerals metabolism in non-pregnant, lactating or pregnant one-humped she-camels (*Camelus dromedarius*) pre-synchronized with controlled internal drug releasing. The study also focused on the correlational relationships between steroid hormones and the oxidant/antioxidant biomarkers, lipid profiles and liver functions indices, renal functions and mineral metabolism in these she-camels. The study was conducted on apparently healthy dromedary she-camels ($n = 60$) during breeding season. A sexually active camel-bull was introduced to she-camels pre-synchronized with CIDR. Fifty to sixty days after natural mating, she-camels were examined for pregnancy. She-camels were divided into three main groups according to both pregnancy and lactation as following: pregnant (PREG, $n = 38$) which was kept as control one, non-pregnant and lactating (LACT, $n = 8$), and non-pregnant and non-lactating she-camels (NPREG, $n = 14$). Steroid hormones, i.e., progesterone (P_4), estradiol (E_2) and cortisol, oxidant indictors, i.e., malondialdehyde (MDA), antioxidant biomarkers, i.e., superoxide dismutase (SOD), total antioxidant capacity (TAC), CAT and reduced glutathione (GSH), lipid profiles indices, renal functions and related minerals were assessed. The present study confirmed the efficacy of using CIDR for synchronization in she-camels. Significant elevations in serum steroids hormones in PREG compare with LACT and NPREG. The highest concentrations of MDA as lipid peroxidation and oxidative stress indictors and lowest levels of antioxidant biomarkers except for SOD, i.e., TAC, CAT and GSH, were reported in PREG compared with LACT and NPREG. PREG showed the highest liver enzymes activities and lowest total protein values. Remarkable increases in serum concentrations of renal function parameters and phosphorous (P) were observed in PREG when compared with the other two groups. The investigated she-camels revealed significant correlation between steroid hormones and the oxidant biomarkers, antioxidant biomarkers, liver functions, renal functions and minerals

出典　doi:10.3390/vetsci8110247
https://doi.org/10.3390/vetsci8110247
最終責任者　Arafat Khalphallah: arafatvet2003@yahoo.com;
Ahmed S. A. Hassaneen: sdiamond_201011@yahoo.com

画像診断学（Veterinary Diagnostic Imaging）

Tetsuya Nakade

Professor

教授　中出　哲也

Ⅰ．筆頭または責任著者　＜First or Corresponding Author＞

Ⅱ．その他＜Others＞

1) Effects of gel pad thickness on skin stiffness evaluationby ultrasonographic strain elastography in normal dogs.
Chhay S, Hanazono K, Kitahara J, Hori A, Miyoshi K, Itami T, Endo D, and Nakade T.
Japanese Journal of Veterinary Research 69(2): 125-134, 2021.
doi: 10.14943/jjvr.69.2.125

2) The effects of gel pad thickness on the evaluation of skin structures using ultrasonography in normal dogs.
Chhay S, Hanazono K, Kitahara J, Hori A, Miyoshi K, Itami T, Endo D, and Nakade T.
J. Vet. Med. Sci. 83(9): 1472–1475, 2021. doi: 10.1292/jvms.21-0086

Japanese Journal of Veterinary Research 69(2): 125-134, 2021

JJVR

REGULAR PAPER Experimental Research

Effects of gel pad thickness on skin stiffness evaluation by ultrasonographic strain elastography in normal dogs

Sothavy Chhay[1)], Kiwamu Hanazono[2,3)], Jo Kitahara[1)], Ai Hori[3)], Kenjiro Miyoshi[1,3)], Takaharu Itami[1,3,*)], Daiji Endo[2)] and Tetsuya Nakade[1,3)]

[1)] Department of Small Animal Clinical Sciences, School of Veterinary Medicine, Rakuno Gakuen University, 582 Bunkyodai Midorimach, Ebetu-shi, Hokkaido 069-8501, Japan
[2)] Department of Biosciences, School of Veterinary Medicine, Rakuno Gakuen University, Ebetsu, Hokkaido 069-8501, Japan
[3)] Animal Medical Center, Rakuno Gakuen University, 582 Bunkyodai Midorimach, Ebetu-shi, Hokkaido 069-8501, Japan

Received for publication, November 8, 2020; accepted, February 25, 2021

Abstract

Gel pads are commonly used for skin ultrasound examination; however, the effect of their thickness on the measured values is unknown. We investigated the effect of pad thickness on skin stiffness measurement in healthy dogs. The skin stiffness of the dorsal neck was measured using a durometer. Ultrasonographic strain elastography was performed with 5-, 10-, and 20-mm-thick pads. Among the strain ratios, muscle/skin (5 mm) showed a significantly positive correlation with skin stiffness. In the strain histogram, AREA (20 mm), CONTRAST (20 mm), MEAN (5, 20 mm), and STANDARD DEVIATION (20 mm) were significantly correlated with skin stiffness. In conclusion, the thickness of the gel pad affects the measurements during skin ultrasonographic strain elastography.

Key Words: Gel pad, normal dog, skin ultrasonography, ultrasonographic strain elastography

Introduction

Skin ultrasonography was first used in human medicine[2)] and has been widely used since then as a non-invasive and convenient technique to diagnose cutaneous neoplasia[5,7)] and inflammatory skin diseases[8,21,26)]. This technique can also be used in veterinary medicine and has been reportededly useful for the diagnosis of cutaneous hemangiosarcoma and lymphangioma in horses[23,25)].

In human medicine, the relationship between skin stiffness and various skin diseases, such as inflammatory and neoplastic diseases, has been investigated[9,24,28,30)]. One non-invasive method for evaluating skin stiffness is the durometer[15)]. The durometer is constructed as follows: a push needle protrudes from the pressure surface of the durometer's body, which is internally connected to a spring. Measurement is performed by pressing the push needle and pressure surface against the specimen's surface, causing the push needle to

* Corresponding author: Kiwamu Hanazono DVM, PhD
Address: Department of Basic Veterinary Medicine, School of Veterinary Medicine, Rakuno Gakuen University, Ebetsu, Hokkaido 069-8501, Japan
Tel: +81-11-388-4808, Fax: +81-11-386-4808, E-mail: k-hanazono@rakuno.ac.jp
doi: 10.14943/jjvr.69.2.125

出典 doi: 10.14943/jjvr.69.2.125
https://eprints.lib.hokudai.ac.jp/dspace/bitstream/2115/81817/1/JJVR69-2_125-134_SothavyChhay.pdf
最終責任者 Kiwamu Hanazono(Corresponding Author)

The Journal of Veterinary Medical Science

NOTE

Internal Medicine

The effects of gel pad thickness on the evaluation of skin structures using ultrasonography in normal dogs

Sothavy CHHAY[1], Kiwamu HANAZONO[1,2]*, Jo KITAHARA[1], Ai HORI[2], Kenjiro MIYOSHI[1,2], Takaharu ITAMI[1,2], Daiji ENDOH[1] and Tetsuya NAKADE[1,2]

[1]School of Veterinary Medicine, Rakuno Gakuen University, 582 Bunkyodai Midorimach, Ebetsu, Hokkaido 069-8501, Japan
[2]Animal Medical Center, Rakuno Gakuen University, 582 Bunkyodai Midorimach, Ebetsu, Hokkaido 069-8501, Japan

J. Vet. Med. Sci.
83(9): 1472–1475, 2021
doi: 10.1292/jvms.21-0086

Received: 15 February 2021
Accepted: 14 July 2021
Advanced Epub:
26 July 2021

ABSTRACT. Gel pads are commonly used in skin ultrasonography; however, the effects of their thickness are unknown. This study investigated the effects of pad thickness on measurements of skin thickness in 10 beagle dogs. Sonograms to measure neck skin thickness were captured without pads and using pads with thicknesses of 3, 5, 10, and 20 mm. Without pads, acoustic shading was observed due to air bubbles in the coupling gel. With 20-mm pads, echogenic artifacts were observed on the skin surface. Entry echo with 20-mm pads was significantly higher than with 3-mm pads. This suggests that visibility of the skin structure could be affected when a gel pad is not used or when a thick gel pad is selected.

KEY WORDS: artifact, gel pad, normal dog, skin thickness, skin ultrasonography

Ultrasonography is a reliable, painless, low-risk, and consistent tool for investigating the skin, thereby allowing real-time visual characterization of its layers. The measurement of skin thickness by ultrasonography has been reported as a reproducible method in human [1, 3, 8] and veterinary medicine [4, 7, 16, 17]. For example, in a study on humans, patients with psoriasis were shown to have a skin thickness significantly higher than that of healthy people [8]. A comparative study of skin thickness was performed in dogs of small breeds, comparing normal dogs, dogs with hyperadrenocorticism, and dogs treated with prednisolone. It showed that dogs with hyperadrenocorticism and dogs treated with prednisolone had a skin thickness that was significantly lower than that of the normal group. Hence, the use of ultrasound to measure skin thickness in small dogs may provide useful clinical information to differentiate between dogs with hyperadrenocorticism and healthy dogs [7]. Furthermore, measurements of skin thickness can be potentially used to infer not only skin diseases but also general conditions. While measuring skin thickness using ultrasonography may be useful in the diagnosis of skin diseases, a high accuracy would be required.

Gel pads (i.e., stand-off pads) are often used in ultrasound examinations of the body surface. This is because gel pads do not contain scatterers and are a medium that adheres to the skin and probe while providing good delineation of body surface structures [6, 11, 13, 14]. Although gel pads are often used in skin ultrasonography, the appropriate thickness of gel pads for skin ultrasonography is currently unknown. We hypothesized that since the skin is very thin and located at the most superficial layer, the thickness of the gel pad may affect the visibility of the skin structure, especially with thicker gel pads, which would reduce the visibility.

The purpose of this study was to investigate how the thickness of gel pads affects the ultrasonographic measurement of skin thickness in dogs.

Our study was performed with 10 beagles: 4 intact females and 6 intact males. Dogs with no history of skin diseases and no shampoos, conditioners, sprays, or lotions applied for two weeks prior to the experiment were selected for this study. The dogs ranged from 5 to 9 years of age, 9.0 to 13.1 kg in body weight, and 2 to 4 for body condition score. All dogs were considered healthy based on the results of clinical examination. In addition, the dogs were confirmed to be hydrated by a skin tent test and the capillary refill time assessment.

The study design was approved by the Rakuno Gakuen University Animal Experiment Committee (approval number: VH19B8), and the study conformed to all ethical guidelines established by this institution. Before the ultrasound examination, the spinous process of the axial vertebrae was palpated, and the third cervical vertebra level just caudal to it was furrowed. For reproducibility of the examination, the skin was marked with an oil-based pen at the site of probing.

*Correspondence to: Hanazono, K.: k-hanazono@rakuno.ac.jp

©2021 The Japanese Society of Veterinary Science

This is an open-access article distributed under the terms of the Creative Commons Attribution Non-Commercial No Derivatives (by-nc-nd) License. (CC-BY-NC-ND 4.0: https://creativecommons.org/licenses/by-nc-nd/4.0/)

出典　doi: 10.1292/jvms.21-0086

https://doi.org/10.1292/jvms.21-0086

最終責任者　Kiwamu Hanazono(Corresponding Author)

獣医ウイルス学 (Veterinary Virology)

Katsuro Hagiwara

Professor

教授　萩原　克郎

Ⅰ. 筆頭または責任著者　＜First or Corresponding Author＞

1) **Hagiwara, K.**, Matsumoto, T., Tsedendamba, P., Baba, K., and Hoshino, B. Bacterial Characteristics of Dust Particle Saltation in Gobi Dust Sites, Mongolia. *Atmosphere*,2021. *12*(11), 1456.
2) Sukmak M, Okamoto M, Ando T, **Hagiwara K**. Genetic stability of the open reading frame 2 (ORF2) of borna disease virus 1 (BoDV-1) distributed in cattle in Hokkaido. J Vet Med Sci. 2021 13. doi: 10.1292/jvms.21-0155.
3) Yuko Kato-Mori, Taku Okamura, Norihito Kawashita, **Hagiwara, K.** Characterization of a variant CD4 molecule in Japanese Black cattle. Veterinary Immunology and Immunopathology. 2020 Dec. 5., DOI: 10.1016/j.vetimm. 2020.110167.

Ⅱ. その他＜Others＞

1) Kodama F., et. al. A. novel nairovirus associated with acute febrile illness in Hokkaido, Japan. Nat Commun. 2021 20;12(1):5539. doi: 10.1038/s41467-021-25857-0.
2) Daidoji T., et. al. Development of genus-specific universal primers for the detection of flaviviruses. Virol J. 2021 Sep 15;18(1):187. doi: 10.1186/s12985-021-01646-5. PMID: 34526049; PMCID: PMC8442469.
3) Uchida L., Zika Virus Potential Vectors among *Aedes* Mosquitoes from Hokkaido, Northern Japan: Implications for Potential Emergence of Zika Disease. Pathogens. 2021 Jul 24;10(8):938. doi: 10.3390/ pathogens10080938.
4) Sato H, et al. Seroprevalence of fasciolosis in Hokkaido sika deer (Cervus nippon yesoensis) from Hokkaido Prefecture, Japan revealed by ELISA using recombinant cathepsin L1. Parasitol Int. 2021. 80:102222. doi: 10.1016/j. parint. 2020. 102222.

atmosphere

MDPI

Article

Bacterial Characteristics of Dust Particle Saltation in Gobi Dust Sites, Mongolia

Katsuro Hagiwara [1,*], Tamaki Matsumoto [2], Purevsuren Tsedendamba [2], Kenji Baba [2] and Buho Hoshino [2,*]

[1] School of Veterinary Medicine, Rakuno Gakuen University, Ebetsu 069-8501, Japan
[2] Department of Environmental and Life Sciences, Rakuno Gakuen University, Ebetsu 069-8501, Japan; matumototamaki24@gmail.com (T.M.); purevsuren600@gmail.com (P.T.); kbaba@rakuno.ac.jp (K.B.)
* Correspondence: k-hagi@rakuno.ac.jp (K.H.); aosier@rakuno.ac.jp (B.H.); Tel.: +81-11-388-4826 (K.H.); +81-11-388-4913 (B.H.)

Abstract: The Gobi Desert is a major source of Asian dust events, and the resulting health hazards have increased significantly in recent years. We reported that a variety of live bacteria were distributed in the Gobi Desert in relation to land use. Bacterial distribution was confirmed in the environment and on the land used by animals; however, bacterial saltation due to dust events has not been investigated in detail. In this study, to understand the distribution of surface bacteria in the atmosphere by dust saltation, live bacteria in four dust-generating areas in the Gobi area were monitored using an artificial dust generating device. The live bacteria were detected by experimental saltation at a wind speed of 6.5–8 m/s in all areas. A certain number of live bacteria are constantly saltated by dust events, and these bacteria depend on land use. Moreover, the bacterial saltation strain depended on land use and diversity, indicating that live bacteria are lifted into the environment by dust events. These findings indicate that dust events saltate environmental bacteria on the ground, suggest the risk of animal-derived bacterial saltation affected by land use, and present cross-border public health challenges to be considered in the future.

Keywords: bacteria; Asian dust storm; dust saltation; Gobi Desert

check for updates

Citation: Hagiwara, K.; Matsumoto, T.; Tsedendamba, P.; Baba, K.; Hoshino, B. Bacterial Characteristics of Dust Particle Saltation in Gobi Dust Sites,

筆頭著者・最終責任者：萩原克郎；doi: https://doi.org/10.3390/atmos12111456

The Journal of Veterinary Medical Science

FULL PAPER
Virology

Genetic stability of the open reading frame 2 (ORF2) of borna disease virus 1 (BoDV-1) distributed in cattle in Hokkaido

Manakorn SUKMAK[1,2], Minoru OKAMOTO[3], Tatsuya ANDO[3] and Katsuro HAGIWARA[3]*

[1]Department of Farm Resources and Production Medicine, Faculty of Veterinary Medicine, Kasetseart University, Kamphaeng Saen, 73140, Thailand
[2]Kamphaengsaen Veterinary Diagnostic Center (KVDC), Faculty of Veterinary Medicine, Kasetseart University, Kamphaeng Saen, 73140, Thailand
[3]School of Veterinary Medicine, Rakuno Gakuen University, Hokkaido 069-8501, Japan

ABSTRACT. Borna disease virus (BoDV) is a neurotropic virus that causes several infections in humans and neurological diseases in a wide range of animals worldwide. BoDV-1 has been molecularly and serologically detected in many domestic and wild animals in Japan; however, the genetic diversity of this virus and the origin of its infection are not fully understood. In this study, we investigated BoDV-1 infection and genetic diversity in samples collected from animals in Hokkaido between 2006 and 2020. The analysis was performed by focusing on the P region of BoDV-1 for virus detection. The presence of BoDV-1 RNA was observed in samples of brain tissue and various organs derived from persistently infected cattle. Moreover, after inoculation, BoDV-positive brains were isolated from neonatal rats. The gene sequences of the P region of BoDV obtained from the rat brain were in the same cluster as the P region of the virus isolated from the original bovine. Thus, genetic variation in BoDV-1 was extremely low. The phylogenetic analysis revealed that BoDV-1 isolates obtained in this study were part of the same cluster, which suggested that BoDV-1 of the same cluster was widespread among animals in Hokkaido.

KEY WORDS: borna disease, genetic variation, Japan, phylogenetic analysis

J. Vet. Med. Sci.
83(10): 1526–1533, 2021
doi: 10.1292/jvms.21-0155

Received: 14 March 2021
Accepted: 30 July 2021
Advanced Epub:
13 August 2021

筆頭著者：M. Sukmak、最終責任者：萩原克郎, doi: 10.1292/jvms.21-0155

Veterinary Immunology and Immunopathology 232 (2021) 110167



Contents lists available at ScienceDirect

Veterinary Immunology and Immunopathology

journal homepage: www.elsevier.com/locate/vetimm





Characterization of a variant CD4 molecule in Japanese Black cattle

Yuko Kato-Mori [a], Taku Okamura [b], Norihito Kawashita [c], Katsuro Hagiwara [b,*]

[a] Graduated School of Science, Technology and Innovation, Kobe University, 7-1-49 Minatojimaminami-machi, Chuo-ku, Kobe, 650-0047, Japan
[b] School of Veterinary Medicine, Rakuno Gakuen University, Ebetsu, Hokkaido, 069-8501, Japan
[c] Faculty of Science and Engineering, Kindai University 3-4-1 Kowakae, Higashiosaka City, Osaka, 577-8502, Japan

ARTICLE INFO

Keywords:
CD4
Japanese Black cattle
Variant

ABSTRACT

Monoclonal antibodies (mAbs) that recognize cluster of differentiation (CD) molecules on lymphocytes are useful tools for the study of different lymphocyte subsets in flow cytometry (FCM) analysis. CD4 is a glycoprotein found on the surfaces of helper T cells, monocytes, macrophages, and dendritic cells. In this study, we describe Japanese Black (JB) calves in a farm whose peripheral blood mononuclear cells (PBMCs) did not react with a CD4-specific mAb. To identify calves with PBMCs with low mAb reactivity, PBMCs from 21 JB calves (1–12 months of age) bred at the same farm were examined using two different bovine CD4 mAbs (clones #CC8 and #CACT138A). FCM analysis indicated that the calves fell into two groups based on reactivity against the two mAbs, i.e., double-positive (DP) calves, whose PBMCs were recognized by both mAbs clones, and single-positive (SP) calves, whose PBMCs were only recognized by #CACT138A. PBMCs from seven calves were not recognized by #CC8, although they had normal reactivity with another mAb, #CACT138A. Sequencing analysis of the CD4 gene in these calves revealed four nucleotide substitutions (G918 T, A930C, G970A, and G1074A) in the coding region in the SP group when compared to the DP group. Three of the four mutations were associated with amino acid substitution (Q306H, K310 N, and A324 T). The substitution at A324 T was located in the D4 domain of CD4 gene. Homology modeling based on the amino acid sequences revealed that the surface structure of this part of the molecule was significantly different between the SP and the DP groups. Therefore, the epitope recognized by the #CC8 CD4 mAb was altered in calves with this genetic mutation, and this led to the low reactivity of the PBMCs from calves in the SP group aginst the #CC8 mAb. In conclusion, this is the first study to identify CD4 variants in JB cattle. We confirmed that the variants did not affect lymphocyte functions, such as mitogen stimulation or lipopolysaccharide-induced cytokine gene expression.

筆頭著者：萩原克郎、最終責任者：萩原克郎, doi: 10.1016/j.vetimm. 2020.110167

nature COMMUNICATIONS

ARTICLE

https://doi.org/10.1038/s41467-021-25857-0 OPEN

A novel nairovirus associated with acute febrile illness in Hokkaido, Japan

Fumihiro Kodama[1,2], Hiroki Yamaguchi[3], Eunsil Park[4], Kango Tatemoto[4], Mariko Sashika[5], Ryo Nakao[6], Yurino Terauchi[7], Keita Mizuma[8], Yasuko Orba[9,10], Hiroaki Kariwa[7], Katsuro Hagiwara[11], Katsunori Okazaki[12], Akiko Goto[3], Rika Komagome[3], Masahiro Miyoshi[3], Takuya Ito[3], Kimiaki Yamano[3], Kentaro Yoshii[13], Chiaki Funaki[9], Mariko Ishizuka[9], Asako Shigeno[14], Yukari Itakura[9], Lesley Bell-Sakyi[15], Shunji Edagawa[1], Atsushi Nagasaka[1], Yoshihiro Sakoda[8], Hirofumi Sawa[9,10,16,17], Ken Maeda[4], Masayuki Saijo[18] & Keita Matsuno[10,14,16✉]

The increasing burden of tick-borne orthonairovirus infections, such as Crimean-Congo hemorrhagic fever, is becoming a global concern for public health. In the present study, we identify a novel orthonairovirus, designated Yezo virus (YEZV), from two patients showing acute febrile illness with thrombocytopenia and leukopenia after tick bite in Hokkaido, Japan, in 2019 and 2020, respectively. YEZV is phylogenetically grouped with Sulina virus detected in *Ixodes ricinus* ticks in Romania. YEZV infection has been confirmed in seven patients from 2014–2020, four of whom were co-infected with *Borrelia* spp. Antibodies to YEZV are found in wild deer and raccoons, and YEZV RNAs have been detected in ticks from Hokkaido. In this work, we demonstrate that YEZV is highly likely to be the causative pathogen of febrile illness, representing the first report of an endemic infection associated with an orthonairovirus potentially transmitted by ticks in Japan.

筆頭著者：K. Kodama、最終責任者：K. Matsuno, doi: 10.1038/s41467-021-25857-0

Daidoji *et al. Virol J* (2021) 18:187
https://doi.org/10.1186/s12985-021-01646-5

Virology Journal

RESEARCH Open Access

Development of genus-specific universal primers for the detection of flaviviruses

Tomo Daidoji[1*], Ronald Enrique Morales Vargas[2], Katsuro Hagiwara[3], Yasuha Arai[1], Yohei Watanabe[1], Keisuke Nishioka[1], Fumi Murakoshi[1], Kotaro Garan[1], Hiroki Sadakane[1] and Takaaki Nakaya[1]

Abstract

Background: Flaviviruses are representative arboviruses carried by arthropods and/or vertebrates; these viruses can pose a public health concern in many countries. By contrast, it is known that a novel virus group called insect-specific flaviviruses (ISFs) also infects arthropods, although no such virus has yet been isolated from vertebrates. The characteristics of ISFs, which affect replication of human-pathogenic flaviviruses within co-infected mosquito cells or mosquitoes without affecting the mosquitoes themselves, mean that we should pay attention to both ISFs and human-pathogenic flaviviruses, despite the fact that ISFs appear not to be directly hazardous to human health. To assess the risk of diseases caused by flaviviruses, and to better understand their ecology, it is necessary to know the extent to which flaviviruses are harbored by arthropods.

Methods: We developed a novel universal primer for use in a PCR-based system to detect a broad range of flaviviruses. We then evaluated its performance. The utility of the novel primer pair was evaluated in a PCR assay using artificially synthesized oligonucleotides derived from a template viral genome sequence. The utility of the primer pair was also examined by reverse transcription PCR (RT-PCR) using cDNA templates prepared from virus-infected cells or crude supernatants prepared from virus-containing mosquito homogenates.

Results: The novel primer pair amplified the flavivirus NS5 sequence (artificially synthesized) in all samples tested (six species of flavivirus that can cause infectious diseases in humans, and flaviviruses harbored by insects). In addition, the novel primer pair detected viral genomes in cDNA templates prepared from mosquito cells infected with live flavivirus under different infectious conditions. Finally, the viral genome was detected with high sensitivity in crude supernatants prepared from pooled mosquito homogenates.

Conclusion: This PCR system based on a novel primer pair makes it possible to detect arthropod-borne flaviviruses worldwide (the primer pair even detected viruses belonging to different genetic subgroups). As such, an assay based on this primer pair may help to improve public health and safety, as well as increase our understanding of flavivirus ecology.

Keywords: Universal primer, Flavivirus, RT-PCR, Arthropod

筆頭著者・最終責任者：T. Daidoji, doi: 10.1186/s12985-021-01646-5

pathogens

MDPI

Article

Zika Virus Potential Vectors among *Aedes* Mosquitoes from Hokkaido, Northern Japan: Implications for Potential Emergence of Zika Disease

Leo Uchida [1,*], Miki Shibuya [1], Ronald Enrique Morales-Vargas [2], Katsuro Hagiwara [1] and Yasukazu Muramatsu [1]

[1] School of Veterinary Medicine, Rakuno Gakuen University, Ebetsu, Hokkaido 069-8501, Japan; s21361159@g.rakuno.ac.jp (M.S.); k-hagi@rakuno.ac.jp (K.H.); y-mrmt@rakuno.ac.jp (Y.M.)

[2] Department of Medical Entomology, Faculty of Tropical Medicine, Mahidol University, Ratchathewi, Bangkok 10400, Thailand; ronald.mor@mahidol.ac.th

* Correspondence: uchidaleo@rakuno.ac.jp; Tel.: +81-11-388-4828

Abstract: The Zika virus (ZIKV) is a rapidly expanding mosquito-borne virus that causes febrile illness in humans. *Aedes aegypti* and *Ae. albopictus* are the primary ZIKV vectors; however, the potential vector competence of other *Aedes* mosquitoes distributed in northern Japan (Palearctic ecozone) are not yet known. In this study, the susceptibility to Zika virus infection of three *Aedes* mosquitoes distributed in the main city of the northern Japan and their capacities as vectors for ZIKV were evaluated. Field-collected mosquitoes were fed ad libitum an infectious blood meal containing the ZIKV PRVABC59. The Zika virus was detected in the abdomen of *Ae. galloisi* and *Ae. japonicus* at 2–10 days post infection (PI), and from the thorax and head of *Ae. galloisi* at 10 days PI, resulting in 17.6% and 5.9% infection rates, respectively. The Zika virus was not detected from *Ae. punctor* at any time. Some northern Japanese *Aedes* could be suspected as vectors of ZIKV but the risk may be low when compared with major ZIKV vectors.

Keywords: Zika virus; susceptibility; *Aedes japonicus*; *Aedes galloisi*; *Aedes* mosquitoes; Palearctic ecozone

check for updates

Citation: Uchida, L.; Shibuya, M.; Morales-Vargas, R.E.; Hagiwara, K.; Muramatsu, Y. Zika Virus Potential Vectors among *Aedes* Mosquitoes from Hokkaido, Northern Japan: Implications for Potential Emergence of Zika Disease. *Pathogens* **2021**, *10*,

筆頭著者・最終責任者： L. Uchida, doi: 10.3390/ pathogens10080938

Parasitology International 80 (2021) 102222

Contents lists available at ScienceDirect

Parasitology International

journal homepage: www.elsevier.com/locate/parint

Short Communication

Seroprevalence of fasciolosis in Hokkaido sika deer (*Cervus nippon yesoensis*) from Hokkaido Prefecture, Japan revealed by ELISA using recombinant cathepsin L1

Hironobu Sato [a], Hiroki Hiraya [b], Takutoshi Sugiyama [a], Shinya Fukumoto [c], Ryota Matsuyama [d], Yojiro Yanagawa [e], Ryo Nakao [f], Takao Irie [g,h], Kensuke Taira [i], Akiko Yamazaki [b], Katsuro Hagiwara [j], Ayako Yoshida [h,k], Yoichi Kamata [b,l], Madoka Ichikawa-Seki [a,*]

[a] Laboratory of Veterinary Parasitology, Faculty of Agriculture, Iwate University, Morioka, Japan
[b] Laboratory of Veterinary Public health, Faculty of Agriculture, Iwate University, Morioka, Japan
[c] National Research Center for Protozoan Disease, Obihiro University of Agriculture and Veterinary Medicine, Obihiro, Japan
[d] Graduate School of Biomedical and Health Sciences, Hiroshima University, Hiroshima, Japan
[e] Laboratory of Theriogenology, Department of Clinical Sciences, Division of Veterinary Medicine, Faculty of Veterinary Medicine, Hokkaido University, Sapporo, Japan
[f] Laboratory of Parasitology, Graduate School of Infectious Diseases, Faculty of Veterinary Medicine, Hokkaido University, Sapporo, Japan
[g] Department of Infection Diseases, Hokkaido Institute of Public Health, Sapporo, Japan
[h] Laboratory of Veterinary Parasitic Diseases, Department of Veterinary Sciences, Faculty of Agriculture, University of Miyazaki, Miyazaki, Japan
[i] Laboratory of Parasitology, School of Veterinary Medicine, Azabu University, Sagamihara, Japan
[j] School of Veterinary Medicine, Rakuno Gakuen University, Ebetsu, Japan
[k] Centre for Animal Diseases Control (CADIC), University of Miyazaki, Miyazaki, Japan
[l] Department of Food and Nutrition, Faculty of Human Life Science, Senri Kinran University, Suita, Japan

ARTICLE INFO

Keywords:
Fasciolosis
ELISA
Cathepsin L1
Hokkaido sika deer
Seroprevalence

ABSTRACT

Fasciolosis, a zoonotic disease caused by liver flukes of the genus *Fasciola*, has been reported in Hokkaido (Yezo) sika deer (*Cervus nippon yesoensis*) in Hokkaido Prefecture, Japan; however, the actual seroprevalence in the animal has not been adequately evaluated. The objective of the present study was to analyze the seroprevalence of the disease among Hokkaido sika deer. Recombinant cathepsin L1 (rCatL1) was used as an antigen for an indirect enzyme-linked immunosorbent assay (ELISA) to detect antibodies against *Fasciola* flukes. The sensitivity and specificity of the ELISA were 84.6% and 100%, respectively. The average seroprevalence in 1109 Hokkaido sika deer from 20 locations in Hokkaido Prefecture was 43.9%. Mature deer showed higher seroprevalence than younger individuals; however, even younger animals may act as a reservoir for the disease. Monitoring infection levels in the Hokkaido sika deer population is important not only for the livestock industry, but also for preventing human fasciolosis.

筆頭著者 H. Sato, 最終責任者 M. Ichikawa-Seki, doi: 10.1016/j. parint. 2020. 102222.

獣医衛生学（Animal Health）

Hidetoshi Higuchi

Professor

教授　樋口　豪紀

Ⅰ．筆頭または責任著者　＜First or Corresponding Author＞

1) Innate immune response in bovine neutrophils stimulated with *Mycoplasma bovis*.
Gondaira S, Nishi K, Fujiki J, Iwano H, Watanabe R, Eguchi A, Hirano Y, **Higuchi H***, Nagahata H
Vet Res 52(1) 58 2021. doi: 10.1186/s13567-021-00920-2.

2) Effects of intra-articular inoculation with *Mycoplasma bovis* on immunological responses in calf joints
Nishi K, Hirano Y, Sato A, Eguchi A, Matsuda K, Toda M, Watanabe T, Iwasaki T, Takahashi N, Hosotani M, Watanabe R, Kato T, Ohtsuka H, Gondaira S*, **Higuchi H***.
Vet immunol immunopathol. in press 2021. doi: 10.1016/j.vetimm.2021.110364.

3) Inflammatory cytokine mRNA and protein levels in the synovial fluid of Mycoplasma arthritis calves.
Nishi K, Gondaira S, Okamoto M, Matsuda K, Sato A, Kato T, Sasagawa M, Tanaka T, **Higuchi H***.
J Vet Med Sci 83(1) 31-35 2021. doi: 10.1292/jvms.20-0491

Ⅱ．その他＜Others＞

1) Somatic cell and innate immune responses in mammary glands of lactating cows to intramammary infusion of *Bifidobacterium breve* atpre-drying off period.
Nagahata H, Kine M, Watanabe H, Tanaka A, Takahashi A, Gondaira S, **Higuchi H.**
J Vet Med Sci 82(12) 1845-1851. 2021. doi: 10.1292/jvms.21-0306

2) Fluctuating Bacteriophage-induced galU Deficiency Region is Involved in Trade-off Effects on the Phage and Fluoroquinolone Sensitivity in Pseudomonas aeruginosa.
Nakamura K, Fujiki J, Nakamura T, Furusawa T , Gondaira S, Usui M, **Higuchi**

H, Tamura Y, Iwano H.
Virus Res. 198596. 2021. doi: 10.1016/j.virusres.

3) Complete Genome Sequence of a Veterinary Pseudomonas aeruginosa Isolate, Pa12.
Nakamura K, Fujiki J, Furusawa T, Nakamura T, Gondaira S, Sasaki M, Usui M, **Higuchi H**, Sawa H, Tamura Y, Iwano H.
Microbiol resour announc 10(26) e0039821. 2021. doi: 10.1128/MRA.00398-21

Gondaira et al. Vet Res (2021) 52:58
https://doi.org/10.1186/s13567-021-00920-2

VETERINARY RESEARCH

RESEARCH ARTICLE Open Access

Innate immune response in bovine neutrophils stimulated with *Mycoplasma bovis*

Satoshi Gondaira[1], Koji Nishi[1], Jumpei Fujiki[2], Hidetomo Iwano[2], Reina Watanabe[1], Ayako Eguchi[1], Yuki Hirano[3], Hidetoshi Higuchi[1*] and Hajime Nagahata[1,4]

Abstract

Mycoplasma bovis (*M. bovis*) is a significant worldwide pathogen of cattle. Neutrophils have an important role in the innate immune response during infection with *M. bovis*. However, even though neutrophils accumulate in *M. bovis* infection, the interaction of *M. bovis* and neutrophils has not been fully elucidated. We attempted to elucidate the innate immune response of neutrophils stimulated with *M. bovis* and evaluate the transcriptome and functional analysis of bovine neutrophils stimulated with *M. bovis*. Proinflammatory cytokines, such as inducible nitric oxide (*iNOS*), which was the most increased gene in transcriptome analysis, were increased in quantitative polymerase chain reaction analysis of bovine neutrophils stimulated with live or heat-killed *M. bovis*. Nitric oxide and intracellular reactive oxygen species production of neutrophils stimulated with *M. bovis* was significantly increased. Neutrophils stimulated with *M. bovis* showed an increased ratio of nonapoptotic cell death compared to unstimulated controls. We demonstrated that neutrophil extracellular traps (NETs) formation was not recognized in neutrophils stimulated with live *M. bovis*. However, heat-killed *M. bovis* induced NETs formation. We also showed the interaction with *M. bovis* and bovine neutrophils regarding proinflammatory cytokine gene expression and functional expression related to NETs formation. Live and killed *M. bovis* induced innate immune responses in neutrophils and had the potential to induce NETs formation, but live *M. bovis* escaped NETs.

Keywords: *Mycoplasma bovis*, Bovine, Neutrophils, Innate immune, Transcriptome analysis

出典　doi:110.1186/s13567-021-00920-2.
https://veterinaryresearch.biomedcentral.com/articles/10.1186/s13567-021-00920-2

最終責任者　Hidetoshi Higuchi (Corresponding Author)

Contents lists available at ScienceDirect

Veterinary Immunology and Immunopathology

journal homepage: www.elsevier.com/locate/vetimm



Research paper

Effects of intra-articular inoculation with *Mycoplasma bovis* on immunological responses in calf joints

Koji Nishi [a,b], Yuki Hirano [a,c], Ayano Sato [d], Ayako Eguchi [a], Kazuya Matsuda [e], Miyuki Toda [e], Takafumi Watanabe [f], Tomohito Iwasaki [g], Naoki Takahashi [h], Marina Hosotani [f], Reina Watanabe [g], Toshihide Kato [d], Hiromichi Ohtsuka [d], Satoshi Gondaira [a,*], Hidetoshi Higuchi [a,*]

[a] *Animal Health Laboratory, Department of Veterinary Science, School of Veterinary Medicine, Rakuno Gakuen University, Ebetsu, Hokkaido, Japan*
[b] *NOSAI Okhotsk Monbetsu Veterinary Clinic, Monbetsu, Hokkaido, Japan*
[c] *Animal Research Center, Agricultural Research Department, Hokkaido Research Organization, Shintoku, Hokkaido, Japan*
[d] *Large Animal Clinical Science, Department of Veterinary Science, School of Veterinary Medicine, Rakuno Gakuen University, Ebetsu, Hokkaido, Japan*
[e] *Department of Veterinary Pathology, Department of Veterinary Science, School of Veterinary Medicine, Rakuno Gakuen University, Ebetsu, Hokkaido 069-8501, Japan*
[f] *Laboratory of Veterinary Anatomy, School of Veterinary Medicine, Rakuno Gakuen University, Ebetsu, Hokkaido, Japan*
[g] *Department of Food Science and Human Wellness, College of Agriculture, Food and Environment Science, Rakuno Gakuen University, Hokkaido, Japan*
[h] *Department of Veterinary Anatomy, College of Bioresource Sciences, Nihon University, Fujisawa, Kanagawa, Japan*

ARTICLE INFO

Keywords:
Arthritis
Inflammatory cytokines
Invasion
Matrix metalloproteinases
Mycoplasma bovis

ABSTRACT

Mycoplasma arthritis that caused by *Mycoplasma bovis* exhibit severe lameness. This disease is difficult to cure with antibiotics, but the detailed pathological mechanisms have not been fully clarified. In this study, we examined the effects of intra-articular inoculation with *M. bovis* on immunological responses in calf joints. We inoculated three calves each with *M. bovis* or phosphate buffer saline (control) into the right stifle joint and dissected them at 15 days postinoculation. *Mycoplasma bovis*–inoculated calves exhibited swelling of the stifle joint, increases in synovial fluid, fibrin deposition, and cartilage thinning. Intracellular *M. bovis* was detected in synovial tissues analyzed by immunohistochemistry and transmission electron microscopy. Messenger RNA expressions of interleukin (IL)-1β, IL-6, IL-8, IL-12p40, and IL-17A in synovial fluid cells and synovial tissues from *M. bovis*–inoculated calves were significantly higher than those from control calves. Protein levels of these cytokines in synovial fluid from *M. bovis*–inoculated calves were markedly higher than those from control calves. Our study clarified that inoculation with *M. bovis* into the stifle joint induced the production of inflammatory cytokines by synovial fluid cells and synovial tissues, causing a severe inflammatory response in joints. Additionally, *M. bovis* could invade cells in synovial tissues, which may have aided it in evading antibiotics and host immune surveillance.

出典　doi: 10.1016/j.vetimm.2021.110364.
https://doi.org/10.1016/j.vetimm.2021.110364

最終責任者　Satoshi Gondaira and Hidetoshi Higuchi (Corresponding Author)

The Journal of Veterinary Medical Science

NOTE

Internal Medicine

Inflammatory cytokine mRNA and protein levels in the synovial fluid of *Mycoplasma* arthritis calves

Koji NISHI[1)], Satoshi GONDAIRA[1)], Mariko OKAMOTO[1,4)], Kazuya MATSUDA[2)], Ayano SATO[3)], Toshihide KATO[3)], Misawo SASAGAWA[1)], Takahiro TANAKA[1)] and Hidetoshi HIGUCHI[1)]*

[1)]Animal Health Laboratory, Department of Veterinary Science, School of Veterinary Medicine, Rakuno Gakuen University, Ebetsu, Hokkaido 069-8501, Japan
[2)]Department of Veterinary Pathology, Department of Veterinary Science, School of Veterinary Medicine, Rakuno Gakuen University, Ebetsu, Hokkaido 069-8501, Japan
[3)]Large Animal Clinical Science, Department of Veterinary Science, School of Veterinary Medicine, Rakuno Gakuen University, Ebetsu, Hokkaido 069-8501, Japan
[4)]Present address: Division of Bacterial and Parasitic Disease, National Institute of Animal Health, National Agriculture and Food Research Organization, Tsukuba, Ibaraki 305-0856, Japan

J. Vet. Med. Sci.
83(1): 31–35, 2021
doi: 10.1292/jvms.20-0491

Received: 19 August 2020
Accepted: 4 November 2020
Advanced Epub:
8 January 2021

ABSTRACT. Bovine *Mycoplasma* arthritis (MA) is caused by *Mycoplasma bovis* and exhibits severe clinical symptoms. However, the pathophysiology of bovine MA is incompletely understood. In this study, we examined the cytokine mRNA expression of synovial fluid (SF) cells and cytokine concentrations in the SF of MA calves. The SF was isolated from five clinically healthy (control) and seven MA calves. mRNA and protein levels of interleukin (IL)-1β, IL-6, IL-8, IL-12, and IL-17 in the SF from MA calves were significantly higher than those from control calves. Our results indicate that SF cells produce inflammatory cytokines, which mainly contribute to the severe inflammatory response in the joints of the MA calves.

KEY WORDS: bovine bacterial arthritis, inflammatory cytokine, *Mycoplasma* arthritis, *Mycoplasma bovis*, synovial fluid

出典　doi: 10.1292/jvms.20-0491
https://www.jstage.jst.go.jp/article/jvms/83/1/83_20-0491/_article
最終責任者　Hidetoshi Higuchi (Corresponding Author)

The Journal of Veterinary Medical Science

FULL PAPER
Immunology

Somatic cell and innate immune responses in mammary glands of lactating cows to intramammary infusion of *Bifidobacterium breve* at pre-drying off period

Hajime NAGAHATA[1)]*, Mari KINE[2)], Hisato WATANABE[2)], Ai TANAKA[2)], Aoi TAKAHASHI[2)], Satoshi GONDAIRA[2)] and Hidetoshi HIGUCHI[2)]

[1)]Department of Veterinary Associated Science, Faculty of Veterinary Medicine, Okayama University of Science, Ikoinooka 1-3, Imabari, Ehime 794-8555, Japan
[2)]Animal Health Unit, Department of Health and Environmental Sciences, School of Veterinary Medicine, Rakuno Gakuen University, Bunkyodai-Midori 582, Ebetsu, Hokkaido 069-8501, Japan

ABSTRACT. Intramammary infusion of *Bifidobacterium breve (B. breve)*-induced somatic cell (SC) counts, chemiluminescent response (CL), lactoferrin (LF) concentrations and mastitis-causing pathogens from quarters with subclinical mastitis were measured to evaluate innate immune response of mammary glands in dairy cows at 3 to 4 weeks before drying off. SC counts in 7 quarters of 7 control cows and 5 quarters of 6 cows with mastitis increased markedly on day 1 and SC values in control cows were significantly ($P<0.05$) increased and returned to pre-infusion levels on day 5 after *B. breve*-infusion. CL values in both groups increased markedly on day 1 and then decreased after *B. breve*-infusion; however, CL values in cows with mastitis did not return to normal levels on day 5 and at postpartum. The CL values were highly correlated with their SC counts in milk from both groups. LF concentrations increased toward day 3 after *B. breve*-infusion and were higher in cows with mastitis. *B. breve*-infusion eliminated 16.6% (1/6) of pathogens from 6 quarters with chronic subclinical mastitis. *B. breve*-induced SC responses in quarters from 3 cows with mastitis showed characteristic patterns of recovery, persistent and new infections. *B. breve*-induced SC counts in quarters from the cows in the pre-drying off were lower (25.7–70.6%) than those of the cows in mid-lactation. The intrinsic innate immune response in cows on pre-drying off may be decreased and appears to be insufficient to eliminate pathogens from mammary gland in the pre-drying off.

KEY WORDS: *Bifidobacterium breve*, innate immune response, lactating cows, mammary gland, pre-drying off

J. Vet. Med. Sci.
83(12): 1845–1851, 2021
doi: 10.1292/jvms.21-0306

Received: 31 May 2021
Accepted: 2 October 2021
Advanced Epub:
14 October 2021

出典　doi: 10.1292/jvms.21-0306
https://www.jstage.jst.go.jp/article/jvms/83/12/83_21-0306/_article
最終責任者　Hajime Nagahata (First Author and Corresponding Author)

Contents lists available at ScienceDirect

Virus Research

journal homepage: www.elsevier.com/locate/virusres

Fluctuating Bacteriophage-induced *galU* Deficiency Region is Involved in Trade-off Effects on the Phage and Fluoroquinolone Sensitivity in *Pseudomonas aeruginosa*

Keisuke Nakamura [a, #], Jumpei Fujiki [a, #, *], Tomohiro Nakamura [a], Takaaki Furusawa [a], Satoshi Gondaira [b], Masaru Usui [c], Hidetoshi Higuchi [b], Yutaka Tamura [c], Hidetomo Iwano [a]

[a] Laboratory of Veterinary Biochemistry, Department of Veterinary Medicine, Rakuno Gakuen University, Ebetsu, Hokkaido, Japan
[b] Laboratory of Animal Health, Rakuno Gakuen University School of Veterinary Medicine, Ebetsu, Hokkaido, Japan
[c] Laboratory of Food Microbiology and Food Safety, Rakuno Gakuen University School of Veterinary Medicine, Ebetsu, Hokkaido, Japan

ARTICLE INFO

Keywords:
Bacteriophage
galU
Pseudomonas aeruginosa
Phage resistance
Phage therapy
Trade-off
Fitness cost

ABSTRACT

Pseudomonas aeruginosa, which causes chronic infections, has demonstrated rapid acquisition of antimicrobial resistance (AMR). Therefore, bacteriophages have received significant attention as promising antimicrobial agents; however, previous trials have reported the occurrence of phage-resistant variants. *P. aeruginosa* has lost large chromosomal fragments via evolutionary selection by MutL. Mutants lacking *galU* and *hmgA*, located in close proximity, exhibit phage resistance and brown color phenotype since *hmgA* encodes a homogentisic acid metabolic enzyme and deletion of *galU* results in a lack of O-antigen polysaccharide and absence of the phage receptor. In the present study, we evaluated this mechanism for controlling phage resistance in *P. aeruginosa* veterinary isolate Pa12. Phage-resistant Pa12 brown mutants (brmts) with *galU* and *hmgA* deletions were isolated. Whole-genome sequencing of the brmts revealed that regions 148-27 kbp upstream and 261-110 kbp downstream of *galU* were largely deleted from the Pa12 parental chromosome. Furthermore, all of these fluctuating deleted sequences in Pa12 brmts, tentatively designated bacteriophage-induced *galU* deficiency (BigD) regions, harbor multi-drug efflux system genes (*mexXY*). Minimum inhibitory concentration (MIC) assays demonstrated that brmts altered sensitivity to antibiotics and exhibited increased levofloxacin sensitivity compared with the Pa12 parent. Orbifloxacin and enrofloxacin also effectively suppressed growth of the Pa12 brmts, suggesting that MexXY, which mediates quinolone efflux and is located in the BigD region, might be associated with restoration of fluoroquinolone sensitivity. Our findings indicate that AMR-related genes in the BigD region could produce trade-off effects between phages and drug sensitivity and thereby contribute to a potential strategy to control and prevent phage-resistant variants in phage therapy.

出典　doi: 10.1016/j.virusres.2021.198596
https://www.sciencedirect.com/science/article/pii/S0168170221003038?via%3Dihub

最終責任者　Jumpei Fujiki (Corresponding Author)

AMERICAN SOCIETY FOR MICROBIOLOGY | Microbiology Resource Announcements
GENOME SEQUENCES
July 2021 Volume 10 Issue 26 e00398-21
https://doi.org/10.1128/MRA.00398-21

Complete Genome Sequence of a Veterinary *Pseudomonas aeruginosa* Isolate, Pa12

Keisuke Nakamura[a], Jumpei Fujiki[a], Takaaki Furusawa[a], Tomohiro Nakamura[a], Satoshi Gondaira[b], Michihito Sasaki[c], Masaru Usui[d], Hidetoshi Higuchi[b], Hirofumi Sawa[c,e], Yutaka Tamura[d,f], and Hidetomo Iwano[a]

[a]Laboratory of Veterinary Biochemistry, Rakuno Gakuen University School of Veterinary Medicine, Ebetsu, Japan
[b]Laboratory of Animal Health, Rakuno Gakuen University School of Veterinary Medicine, Ebetsu, Japan
[c]Division of Molecular Pathobiology, International Institute for Zoonosis Control, Hokkaido University, Sapporo, Japan
[d]Laboratory of Food Microbiology and Food Safety, Rakuno Gakuen University School of Veterinary Medicine, Ebetsu, Japan
[e]International Collaboration Unit, International Institute for Zoonosis Control, Hokkaido University, Sapporo, Japan
[f]Center for Veterinary Drug Development, Rakuno Gakuen University, Ebetsu, Japan

ABSTRACT *Pseudomonas aeruginosa* causes various opportunistic infections in animals. Here, we report the complete genome sequence of *P. aeruginosa* strain Pa12, a fluoroquinolone-resistant isolate from a canine skin lesion. To expand the molecular antimicrobial characteristics of the isolate, the whole Pa12 genome was sequenced and assembled via long- and short-read platforms.

出典　doi: 10.1128/MRA.00398-21
https://journals.asm.org/doi/10.1128/MRA.00398-21
最終責任者　Jumpei Fujiki (Corresponding Author)

獣医疫学（Veterinary Epidemiology）

Kohei Makita

Professor

教授　蒔田　浩平

Ⅰ．筆頭または責任著者　＜First or Corresponding Author＞

1）Quantitative evaluation of the infection dynamics of bovine brucellosis in Tanzania.
Ukita M, Hozé N, Nemoto T, Cauchemez S, Asakura S, Makingi G, Kazwala R, **Makita K.**
Prev. Vet. Med. 194: 105425. 2021.
https://doi.org/10.1016/j.prevetmed.2021.105425

2) Current status of antimicrobial drug use in Japanese companion animal clinics and the factors associated with their use.
Makita K, Sugahara N, Nakamura K, Matsuoka T, Sakai M, Tamura Y.
Front. Vet. Sci. 8: 705648. 2021. doi: 10.3389/fvets.2021.705648

3) Improving the livelihood of livestock and farmers and public health in developing countries through the provision of solutions for the various risks they face.
Makita K, Ikegami M, Matsumoto T.
Jpn. Agr. Res. Q. 55(S1): 533-541. 2021.
https://www.jircas.go.jp/sites/default/files/publication/jarq/jarq55-5_533-541.pdf

4) Analysis of the effect of feedback feeding on the farm-level occurrence of porcine epidemic diarrhea in Kagoshima and Miyazaki Prefectures, Japan.
Yamagami T, Miyama T, Toyomaki H, Sekiguchi S, Sasaki Y, Sueyoshi M, **Makita K.**
J. Vet. Med. Sci. 83(11): 1772-1781. 2021. https://doi.org/10.1292/jvms.21-0343

5) Animal health and food safety risk assessments.
Makita K.
Rev. Sci. Tech. Off. Int. Epiz. 40(2): 533-544. 2021.
https://doi.org/10.20506/rst.40.2.3243

6) Estimation of economic loss by carcass weight reduction of Japanese dairy cows due to infection with bovine leukemia virus.
Nakada S, Fujimoto Y, Kohara J, Adachi Y, **Makita K**.
Prev. Vet. Med. 198: 105528. 2022 (published on October 29, 2021).
https://doi.org/10.1016/j.prevetmed.2021.105528

Ⅱ. その他＜Others＞

1) Decreased colistin resistance and *mcr-1* prevalence in pig-derived *Escherichia coli* in Japan after banning colistin as a feed additive.
Usui M, Nozawa Y, Fukuda A, Sato T, Yamada M, **Makita K**, Tamura Y.
J. Glob. Antimicrob. Resist. 24: 383-386. 2021.
https://doi.org/10.1016/j.jgar.2021.01.016

2) Risk profile - Group B *Streptococcus* (GBS) - *Streptococcus agalactiae* sequence type (ST) 283 in freshwater fish. Bangkok.
FAO (**Makita K**, as a contributor in writing)
https://doi.org/10.4060/cb5067en

Preventive Veterinary Medicine 194 (2021) 105425

Contents lists available at ScienceDirect

Preventive Veterinary Medicine

journal homepage: www.elsevier.com/locate/prevetmed

Quantitative evaluation of the infection dynamics of bovine brucellosis in Tanzania

Makoto Ukita [a], Nathanael Hozé [b], Takahiro Nemoto [b], Simon Cauchemez [b], Shingo Asakura [a], George Makingi [c], Rudovick Kazwala [c], Kohei Makita [a,*]

[a] Veterinary Epidemiology Unit, Department of Preventive Veterinary Medicine, School of Veterinary Medicine, Rakuno Gakuen University, 582 Bunkyodai Midorimachi, Ebetsu, 069-8501, Japan
[b] Mathematical Modelling of Infectious Diseases Unit, Institut Pasteur, UMR2000, CNRS, Paris, France
[c] Sokoine University of Agriculture, Chuo Kikuu, Morogoro, P.O. Box 3000, Tanzania

ARTICLE INFO

Keywords:
Brucellosis
Infectious disease modelling
Force of infection
Basic reproductive number

ABSTRACT

Brucellosis is endemic in Tanzania. A cross-sectional study was conducted at 17 cattle farms in agro-pastoral areas in Tanzania to identify risk factors associated with the within-farm prevalence of bovine brucellosis and to quantitatively assess the infection dynamics through disease modelling. Cattle blood sampling and interviews with farmers using a structured questionnaire were conducted. A total of 673 serum samples were screened using the Rose-Bengal plate test (RBPT), and sero-positivity of RBPT-positive samples was confirmed using a competitive enzyme-linked immunosorbent assay. Zero-inflated binomial regression was performed for univariable and multivariable risk factor analyses of within-farm prevalence. Several susceptible-infectious (SI) models were compared based on deviance information criteria, and age-dependent force of infection (FOI) was measured using age-specific prevalence data for the 10 infection-positive farms. Using the diagnoses of cows on the 17 farms, the basic reproduction number, R_0, was also calculated. The farm-level prevalence and animal-level adjusted prevalence were 58.8 % (10/17, 95 % confidence interval: 33.5–80.6 %) and 7.0 % (20/673, 95 % credible interval: 5.7–8.4 %), respectively. The risk factor for high within-farm prevalence was introduction of cattle from other herds. A mathematical model with constant FOI showed the annual probability of infection as 1.4 % (95 % credible interval: 1.0 %–2.0 %). The R_0 was 1.07. The constant FOI could have been due to the predominant mode of infection being transmission of *Brucella* from contaminated aborted materials during grazing. Direct purchase of infected cattle could facilitate efficient transmission between susceptible animals through abortion.

出典　https://doi.org/10.1016/j.prevetmed.2021.105425

最終責任者　Kohei Makita (Corresponding Author)

frontiers in Veterinary Science

ORIGINAL RESEARCH
published: 24 September 2021
doi: 10.3389/fvets.2021.705648

Current Status of Antimicrobial Drug Use in Japanese Companion Animal Clinics and the Factors Associated With Their Use

Kohei Makita[1]*, *Nami Sugahara*[1], *Kazuhiro Nakamura*[2], *Takeshi Matsuoka*[3], *Masato Sakai*[3] *and Yutaka Tamura*[4]

[1] Veterinary Epidemiology Unit, School of Veterinary Medicine, Rakuno Gakuen University, Ebetsu, Japan, [2] Technical Support Department, MP Agro Co. Ltd., Tokyo, Japan, [3] Japan Veterinary Medical Association, Tokyo, Japan, [4] Center for Veterinary Drug Development, Rakuno Gakuen University, Ebetsu, Japan

OPEN ACCESS

Edited by:
Fernando O. Maldonas, Pontificia Universidad Católica de Chile, Chile

Reviewed by:
Marilia Salgado-Caxito, Pontificia Universidad Católica de Chile, Chile
Ingeborg Marianne Van Gaalen(VK, Utrecht University, Netherlands

***Correspondence:**
Kohei Makita
kmakita@rakuno.ac.jp

Specialty section:
This article was submitted to Veterinary Epidemiology and Economics, a section of the journal Frontiers in Veterinary Science

Received: *05 May 2021*
Accepted: *01 September 2021*
Published: *24 September 2021*

Citation:
Makita K, Sugahara N, Nakamura K, Matsuoka T, Sakai M and Tamura Y (2021) Current Status of Antimicrobial Drug Use in Japanese Companion Animal Clinics and the Factors Associated With Their Use. Front. Vet. Sci. 8:705648. doi: 10.3389/fvets.2021.705648

The Japanese National Action Plan on Antimicrobial Resistance (AMR) was adopted to strengthen AMR surveillance and monitoring in companion animals. The Japanese Veterinary Antimicrobial Resistance Monitoring (JVARM) system monitors the sale of veterinary antimicrobial drugs by pharmaceutical companies, and the sale of human drugs by principal wholesale companies to companion animal (dogs and cats) clinics. However, the data do not include sales by local drug suppliers and personal importation to companion animal clinics in Japan. The purposes of this study were to estimate total antimicrobial drug use by companion animal clinics in Japan and to identify the factors associated with their use. In 2018, questionnaires gathering data on attributes of the clinic and volumes of antimicrobial drugs used were sent to 212 clinics across Japan by the Japan Veterinary Medical Association. Out of the clinics, 170 valid questionnaires were returned (80.2% response rate). Antimicrobial drugs were categorized first as human, veterinary, or imported drugs and then further categorized as important drugs (critically important drugs for humans and second-choice veterinary drugs) or others. Total antimicrobial drug use was estimated based on the number of clinics reported in 2016. The relationships between antimicrobial drug use and various questionnaire items were analyzed using non-parametric regression analysis. Total antimicrobial drug use was estimated at 29.9t, which was 2.1 times higher than reported by the JVARM survey on the sales of antimicrobial drugs. In terms of total use, important drugs and human drugs accounted for 12.6 and 61.8%, respectively. Clinic income per veterinarian was associated with total antimicrobial use per veterinarian. The proportion of important drugs among all antimicrobial drugs used in a clinic was high in recently established clinics with middle-aged and older directors.

Keywords: companion animal, antimicrobial drug use, antimicrobial resistance (AMR), Japan, sociological factors

出典　doi: 10.3389/fvets.2021.705648
https://doi.org/10.3389/fvets.2021.705648

最終責任者　Kohei Makita (Corresponding Author)

JARQ 55 (SI), 533-541 (2021) https://www.jircas.go.jp

REVIEW

Improving the Livelihood of Livestock and Farmers and Public Health in Developing Countries through the Provision of Solutions for the Various Risks They Face

Kohei MAKITA[1*], Munenobu IKEGAMI[2] and Tomoya MATSUMOTO[3]

[1] Department of Veterinary Medicine, School of Veterinary Medicine, Rakuno Gakuen University, Ebetsu, Japan
[2] Department of International Economics, Faculty of Economics, Hosei University, Machida, Japan
[3] Department of Economics, Otaru University of Commerce, Otaru, Japan

Abstract

Livestock plays an important role in the livelihoods of livestock farmers of developing countries through the provision of food, income sources, and assets. The International Livestock Research Institute (ILRI) has led global efforts on livestock research in developing countries, mainly in South and Southeast Asia and sub-Saharan Africa, and contributed to poverty alleviation and improvement of the health of people. During ILRI's over 50-year history, its research priorities and orientations have evolved from animal breeding, production and health to approaches addressing various risks faced by resource-poor livestock farmers. This review highlights the research work implemented by three Japanese scientists, who respectively evaluated or proposed innovative solutions to distinctive risks faced by livestock, agricultural farmers, and consumers in developing countries. They are namely, (1) Index-Based Livestock Insurance (IBLI) to counter climate change risks, (2) mobile money to livelihood risks, and (3) participatory risk analysis to food contamination. This review then identifies and discusses areas of further research needed to improve the livelihoods of livestock farmers, then concludes by calling for international collaboration.

Discipline: Animal Science
Additional key words: ILRI, Index-Based Livestock Insurance, mobile money, participatory risk analysis

出典　https://www.jircas.go.jp/sites/default/files/publication/jarq/jarq55-5_533-541.pdf

最終責任者　Kohei Makita (Corresponding Author)

The Journal of Veterinary Medical Science

FULL PAPER
Epidemiology

Analysis of the effect of feedback feeding on the farm-level occurrence of porcine epidemic diarrhea in Kagoshima and Miyazaki Prefectures, Japan

Taiki YAMAGAMI[1)#], Takeshi MIYAMA[2)#], Haruya TOYOMAKI[1,3)], Satoshi SEKIGUCHI[4,5)], Yosuke SASAKI[5,6)], Masuo SUEYOSHI[4)] and Kohei MAKITA[1,2)*]

[1)]Veterinary Epidemiology Unit, School of Veterinary Medicine, Rakuno Gakuen University, 582 Bunkyodai-Midorimachi, Ebetsu, Hokkaido 069-8501, Japan
[2)]Veterinary Epidemiology Unit, Graduate School of Veterinary Medicine, Rakuno Gakuen University, 582 Bunkyodai-Midorimachi, Ebetsu, Hokkaido 069-8501, Japan
[3)]Laboratory of Toxicology, Department of Environmental Veterinary Sciences, Faculty of Veterinary Medicine, Hokkaido University, Kita 18, Nishi 9, Kita-ku, Sapporo, Hokkaido 060-0818, Japan
[4)]Department of Veterinary Sciences, Faculty of Agriculture, University of Miyazaki, 1-1 Gakuenkibanadai Nishi, Miyazaki 889-2192, Japan
[5)]Center for Animal Disease Control, University of Miyazaki, 1-1 Gakuenkibanadai Nishi, Miyazaki 889-2155, Japan
[6)]Department of Animal and Grassland Sciences, Faculty of Agriculture, University of Miyazaki, 1-1 Gakuenkibanadai Nishi, Miyazaki 889-2192, Japan

ABSTRACT. When a large-scale epidemic of porcine epidemic diarrhea (PED) occurred in 2013 in Japan, feedback feeding (feeding feces and gut tissues of infected piglets) was attempted to impart immunity to sows and immunize nursing piglets via breastfeeding. This study evaluated the effect of feedback feeding on PED control at 172 farms in Kagoshima and Miyazaki Prefectures. Univariable and multivariable generalized linear models were used to analyze the associations between conduct of feedback feeding and damage from the outbreak (outbreak period and the number of piglet deaths) at the farm level. The within-farm outbreak period shortened over time after the regional outbreak began on Kyushu Island (P=0.009) and was longer on large-scale farms (mean 66.0 days, P=0.003) than small-scale farms (29.4 days) and on farms that used feedback feeding (145.2 days, P=0.059) than those that did not (66.0 days). The number of dead piglets decreased over time since the first regional case (P<0.001) and was higher at farrow-to-finish farms (3.8 piglets/sow, P<0.001) than reproduction farms (0.7 piglets/sow). The effect of feedback feeding on the number of dead piglets was not significant, but its interaction term with farm style had a significant effect (5.0 more piglet deaths at reproduction farms than fallow-to-finish farms, P=0.001). These results suggest that feedback feeding made the damage from PED worse, though it was well established at a later stage of the regional PED epidemic.

KEY WORDS: feedback feeding, immunization, Japan, porcine epidemic diarrhea

J. Vet. Med. Sci.
83(11): 1772–1781, 2021
doi: 10.1292/jvms.21-0343

Received: 14 June 2021
Accepted: 5 September 2021
Advanced Epub:
6 October 2021

出典　doi: 10.1292/jvms.21-0343
https://doi.org/10.1292/jvms.21-0343
最終責任者　Kohei Makita (Corresponding Author)

Rev. Sci. Tech. Off. Int. Epiz., 2021, **40** (2), 533-544

Animal health and food safety risk assessments

K. Makita

Veterinary Epidemiology Unit, OIE Joint Collaborating Centre for Food Safety, Rakuno Gakuen University, 582 Bunkyodai Midorimachi, Ebetsu, 069-8501, Japan
E-mail: kmakita@rakuno.ac.jp

Summary

Animal health risk assessment is one of the key tasks of Veterinary Services. There are well-established protocols created by the World Organisation for Animal Health and Codex Alimentarius Commission for assessing risk. They cover terrestrial and aquatic animals and zoonotic infectious diseases, food safety, and the environment, taking into consideration the connections between them.

Significant effort has been made in developing methods to estimate the probability, and consequences, of infectious disease incursion in disease-free countries through legal or illegal trade or via the movements of insects and wildlife. Additional efforts have been made in the design of prevention strategies and contingency plans. Concerns about possible pandemics of avian influenza continue to be important motivation for monitoring viruses for selection of vaccine candidate strains. The recent COVID-19 pandemic was zoonotic in nature and caused extensive disruption throughout the world. Tools are becoming available for quantitative food safety risk assessments for bacteria, toxins, viruses, and antimicrobial resistance genes, including tools that allow simulations for the selection of effective control options. Applying participatory techniques facilitates the conduct of risk analysis in low- and middle-income countries. In internationally established frameworks, risk assessment is the first step towards elimination of important infectious diseases in endemic countries and it is an important contributor to the reduction of disease risks. Quantitative and qualitative socio-economic and behavioural studies have been developed to design risk management options that are acceptable and sustainable for actors throughout value chains.

Keywords

Animal health – Aquatic animal – Food safety – Risk analysis – Risk assessment – Terrestrial animal.

出典　https://doi.org/10.20506/rst.40.2.3243

最終責任者　Kohei Makita (Corresponding Author)

Contents lists available at ScienceDirect

Preventive Veterinary Medicine

journal homepage: www.elsevier.com/locate/prevetmed

Estimation of economic loss by carcass weight reduction of Japanese dairy cows due to infection with bovine leukemia virus

Satoshi Nakada [a,b], Yuri Fujimoto [a], Junko Kohara [c], Yasumoto Adachi [d], Kohei Makita [a,*]

[a] Veterinary Epidemiology Unit, Graduate School of Veterinary Medicine, Rakuno Gakuen University, 582 Bunkyodai Midorimachi, Ebetsu, Hokkaido, 069-8501, Japan
[b] Hokkaido Higashi Agriculture Mutual Aid Association, 109-28 Nishizyunbetsu, Betsukai, 088-2576, Japan
[c] Animal Research Center, Agricultural Research Department, Hokkaido Research Organization, Nishi 5-39, Shintoku, 081-0038, Japan
[d] Hayakita Meat Inspection Center, Iburi Sub-Prefectural Bureau, Hokkaido Prefectural Government, 695 Toasa, Abira Town, Yufutsu-Gun, Hokkaido, 059-1433, Japan

ARTICLE INFO

Keywords:
Bovine leukemia virus
Carcass weight
Mediation analysis
Dairy cow

ABSTRACT

Bovine leukemia virus (BLV) infection is endemic in Japanese dairy farms. To promote the participation of farmers in BLV infection control in Japan, it is important to provide estimates of the economic losses caused by this infection. We hypothesized that decreased immune function due to BLV infection would increase visceral abnormalities, in turn reducing carcass weight. We employed mediation analysis to estimate the annual economic loss due to carcass weight reduction caused by BLV infection.

Culled Holstein cows from 12 commercial dairy farms in the Nemuro and Kushiro regions of Hokkaido, Japan, were traced. Information on age and the last delivery day were collected. A non-infected culled cow was defined as a cow from which BLV provirus was not detected. A high-proviral-load (H-PVL) cow was defined as a cow whose PVL titer was above 2465 copies/50 ng DNA or 56,765 copies/10^5 cells. A BLV-infected cow with PVL titer lower than the thresholds was categorized as low-proviral load (L-PVL). Post-mortem examination results for culled cows were collected from a meat inspection center.

The hypothesis was tested by three models, using data from 222 culled dairy cows. Model 1, a generalized linear mixed-effects model, selected carcass weight as an outcome variable, BLV status and the potential confounders (lactation stage and age) as explanatory variables, and herd as a random effect. Model 2 additionally included the number of abnormal findings in the post-mortem examination (AFPE) as an explanatory variable. Model 3 applied a Bayesian generalized linear mixed model, which employed a mediator separately modeled for AFPE, to estimate the amount of direct, indirect, and total carcass weight loss with adjustment for known confounding factors.

Compared to the mean carcass weight for the non-infected culled cows, the carcass weight for H-PVL culled cows was significantly decreased by 30.4 kg on average. For each increase of one in the number of AFPE, the mean carcass weight was decreased by 8.6 kg. Only the indirect effect of BLV H-PVL status on carcass weight loss through AFPE was significant, accounting for 21.6 % of the total effect on carcass weight reduction. In 2017, 73,650 culled dairy cows were slaughtered in Hokkaido, and the economic loss due to carcass weight loss caused by BLV infection that year was estimated to be US $1,391,649. In summary, unlike L-PVL cows, H-PVL status was associated with carcass weight reduction, which was partially mediated by an increase in the number of visceral abnormalities.

出典　https://doi.org/10.1016/j.prevetmed.2021.105528
最終責任者　Kohei Makita (Corresponding Author)

Journal of Global Antimicrobial Resistance 24 (2021) 383–386

Contents lists available at ScienceDirect

Journal of Global Antimicrobial Resistance

journal homepage: www.elsevier.com/locate/jgar

Decreased colistin resistance and *mcr-1* prevalence in pig-derived *Escherichia coli* in Japan after banning colistin as a feed additive

Masaru Usui[a,*], Yohei Nozawa[a], Akira Fukuda[a], Tomomi Sato[a], Michi Yamada[b], Kohei Makita[c], Yutaka Tamura[a]

[a] *Laboratory of Food Microbiology and Food Safety, Department of Health and Environmental Sciences, School of Veterinary Medicine, Rakuno Gakuen University, Ebetsu, Hokkaido, Japan*
[b] *Department of Sustainable Agriculture, Rakuno Gakuen University, Ebetsu, Hokkaido, Japan*
[c] *Laboratory of Veterinary Epidemiology, Department of Health and Environmental Sciences, School of Veterinary Medicine, Rakuno Gakuen University, Ebetsu, Hokkaido, Japan*

ARTICLE INFO

Article history:
Received 10 August 2020
Received in revised form 20 December 2020
Accepted 23 January 2021
Available online 3 February 2021

Keywords:
Colistin
Feed additive
Pig
Mobilized colistin resistance-1
Antibiotic resistance

ABSTRACT

Background: Antimicrobial resistance to colistin, a widely used feed additive for farm animals across the world, has raised public health concern in recent years. Since July 2018, its use as feed additive has been banned in Japan to reduce the spread of plasmid-based mobilized colistin resistance (*mcr*) genes and the subsequent development of colistin-resistant bacteria. Evaluating the effects of these measures is required.

Methods: We evaluated the effects of colistin use, as a feed additive, on colistin resistance in pigs ($n = 5$) from birth to finishing in the farm. Moreover, to evaluate changes in colistin resistance and *mcr* gene prevalence in response to colistin withdrawal, *E. coli* samples derived from pig faeces sourced from the fields of three geographically distinct farms were characterized before and after the withdrawal of colistin as a feed additive.

Results: Colistin-resistant *Escherichia coli* in pigs ($n = 5$) increased during the colistin administration period and decreased immediately after its end. In three fields, the colistin resistance rate and prevalence of *mcr-1* decreased immediately and significantly after the ban. However, colistin-resistant and *mcr-1*-positive *E. coli* were still detected in all three farm fields 12 months after the ban on colistin use.

Conclusion: Agricultural colistin use caused selective pressure that contributed to widespread *mcr* dissemination in Japan. Colistin resistance and the presence of *mcr* genes should be continuously monitored in food-producing animals.

© 2021 The Author(s). Published by Elsevier Ltd on behalf of International Society for Antimicrobial Chemotherapy. This is an open access article under the CC BY license (http://creativecommons.org/licenses/by/4.0/).

出典　http://doi.org/10.1016/j.jgar.2021.01.016
最終責任者　Masaru Usui (Corresponding Author)



出典　https://doi.org/10.4060/cb5067en
最終責任者　Food and Agriculture Organization of the United Nations

獣医病理学 (Veterinary Pathology)

Kazuya Matsuda

Professor

教授　松田　一哉

Ⅰ．筆頭または責任著者　＜First or Corresponding Author＞

Ⅱ．その他＜Others＞

1) Nishi K, Gondaira S, Okamoto M, **Matsuda K**, Sato A, Kato T, Sasagawa M, Tanaka T, Higuchi H. Inflammatory cytokine mRNA and protein levels in the synovial fluid of Mycoplasma arthritis calves. *J Vet Med Sci*. **83**: 31-35. 2021. doi: 10.1292/jvms.20-0491.
2) Sano Y, Seki K, Miyoshi K, Sakai T, Kadosawa T, **Matsuda K**. Mediastinal basaloid carcinoma arising from thymic cysts in two dogs. *J Vet Med Sci*. **83**: 876-880. 2021. doi: 10.1292/jvms.20-0518.
3) Sano Y, Kuwajima H, Kanai H, Baba C, Azami K, **Matsuda K**. A bronchopulmonary artery fistula in a horse. *J Vet Med Sci*. **83**: 1225-1228. 2021. doi: 10.1292/jvms.21-0221.
4) Nishimori T, Hanazono K, **Matsuda K**, Kawamura Y, Kadosawa T, Endo Y, Uchide T. Prognostic role of ΔNp63 expression in canine transitional cell carcinoma of the urinary bladder. *Open Vet J*. **11**: 700-706. 2021. doi: 10.5455/OVJ.2021.v11.i4.22.
5) Nishi K, Hirano Y, Sato A, Eguchi A, **Matsuda K**, Toda M, Watanabe T, Iwasaki T, Takahashi N, Hosotani M, Watanabe R, Kato T, Ohtsuka H, Gondaira S, Higuchi H. Effects of intra-articular inoculation with *Mycoplasma bovis* on immunological responses in calf joints. *Vet Immunol Immunopathol*. **244**: 110364. 2022. doi.org/10.1016/j.vetimm.2021.110364.

The Journal of Veterinary Medical Science

NOTE

Internal Medicine

Inflammatory cytokine mRNA and protein levels in the synovial fluid of *Mycoplasma* arthritis calves

Koji NISHI[1)], Satoshi GONDAIRA[1)], Mariko OKAMOTO[1,4)], Kazuya MATSUDA[2)], Ayano SATO[3)], Toshihide KATO[3)], Misawo SASAGAWA[1)], Takahiro TANAKA[1)] and Hidetoshi HIGUCHI[1)]*

[1)]Animal Health Laboratory, Department of Veterinary Science, School of Veterinary Medicine, Rakuno Gakuen University, Ebetsu, Hokkaido 069-8501, Japan
[2)]Department of Veterinary Pathology, Department of Veterinary Science, School of Veterinary Medicine, Rakuno Gakuen University, Ebetsu, Hokkaido 069-8501, Japan
[3)]Large Animal Clinical Science, Department of Veterinary Science, School of Veterinary Medicine, Rakuno Gakuen University, Ebetsu, Hokkaido 069-8501, Japan
[4)]Present address: Division of Bacterial and Parasitic Disease, National Institute of Animal Health, National Agriculture and Food Research Organization, Tsukuba, Ibaraki 305-0856, Japan

J. Vet. Med. Sci.
83(1): 31–35, 2021
doi: 10.1292/jvms.20-0491

Received: 19 August 2020
Accepted: 4 November 2020
Advanced Epub:
8 January 2021

ABSTRACT. Bovine *Mycoplasma* arthritis (MA) is caused by *Mycoplasma bovis* and exhibits severe clinical symptoms. However, the pathophysiology of bovine MA is incompletely understood. In this study, we examined the cytokine mRNA expression of synovial fluid (SF) cells and cytokine concentrations in the SF of MA calves. The SF was isolated from five clinically healthy (control) and seven MA calves. mRNA and protein levels of interleukin (IL)-1β, IL-6, IL-8, IL-12, and IL-17 in the SF from MA calves were significantly higher than those from control calves. Our results indicate that SF cells produce inflammatory cytokines, which mainly contribute to the severe inflammatory response in the joints of the MA calves.

KEY WORDS: bovine bacterial arthritis, inflammatory cytokine, *Mycoplasma* arthritis, *Mycoplasma bovis*, synovial fluid

出典　https://doi.org/10.1292/jvms.20-0491

最終責任者　Hidetoshi Higuchi (Corresponding Author)

The Journal of Veterinary Medical Science

NOTE

Pathology

Mediastinal basaloid carcinoma arising from thymic cysts in two dogs

Yuto SANO[1)*], Kanae SEKI[1)], Kenjirou MIYOSHI[2)], Toshikazu SAKAI[2)], Tsuyoshi KADOSAWA[2)] and Kazuya MATSUDA[1)]

[1)]Department of Veterinary Pathology, School of Veterinary Medicine, Rakuno Gakuen University, Ebetsu, Hokkaido 069-8501, Japan

[2)]Department of Small Animal Clinical Sciences, School of Veterinary Medicine, Rakuno Gakuen University, Ebetsu, Hokkaido 069-8501, Japan

J. Vet. Med. Sci.
83(5): 876–880, 2021
doi: 10.1292/jvms.20-0518

Received: 1 September 2020
Accepted: 24 March 2021
Advanced Epub:
5 April 2021

ABSTRACT. Mediastinal masses in dogs were diagnosed as basaloid carcinoma associated with multiple thymic cysts (MTCs). The masses were composed of MTCs and proliferating intracystic neoplastic basaloid cells, which immunohistochemically diffusely expressed p63 and cytokeratin 19. A gradual transition from the basal cell layers lining the cysts walls to the neoplastic cells was seen, and it was indicated that the neoplastic cells had originated from the basal cell layers of the cysts. To the best of our knowledge, this is the first report of basaloid carcinoma occurring in the mediastinal cavity in dogs. Although these tumors were demonstrated to be rare origins, basaloid carcinoma should be included in the differential diagnoses for canine mediastinal tumors.

KEY WORDS: basaloid carcinoma, dog, mediastinum, thymic branchial cyst, thymic cyst

出典　https://doi.org/10.1292/jvms.20-0518

最終責任者　Yuto Sano (First and Corresponding Author)

The Journal of Veterinary Medical Science

NOTE

Pathology

A bronchopulmonary artery fistula in a horse

Yuto SANO[1)]*, Hikaru KUWAJIMA[1)], Hiroki KANAI[1)], Chiemi BABA[1)], Kohei AZAMI[1)] and Kazuya MATSUDA[1)]

[1)]Department of Veterinary Pathology, School of Veterinary Medicine, Rakuno Gakuen University, Ebetsu, Hokkaido 069-8501, Japan

J. Vet. Med. Sci.
83(8): 1225–1228, 2021
doi: 10.1292/jvms.21-0221

Received: 11 April 2021
Accepted: 24 May 2021
Advanced Epub:
10 June 2021

ABSTRACT. A 24-year-old, Thoroughbred gelding presented with difficulty breathing for a few days and intermittent nose bleeding before dying. At necropsy, the bronchoesophageal artery and the bronchial artery that flowed into the left anterior lobe were tortuous and dilated, and it was found that dilated tortuous branches of the bronchial artery ran over the dorsal and ventral surfaces of the left anterior lobe. Histopathologically, an anastomosis between a muscular artery and an elastic artery were demonstrated, which were identified as bronchial and pulmonary arteries, respectively. Based on the gross and histopathological findings, a bronchopulmonary artery fistula was diagnosed. To the best of our knowledge, this is the first case report of a pulmonary vascular anastomosis in a horse.

KEY WORDS: anastomosis, bronchial artery, horse, lung, pulmonary artery

出典　https://doi.org/10.1292/jvms.21-0221

最終責任者　Yuto Sano (First and Corresponding Author)

Open Veterinary Journal, (2021), Vol. 11(4): 700–706
ISSN: 2226-4485 (Print)
ISSN: 2218-6050 (Online)
Original Research
DOI: *10.5455/OVJ.2021.v11.i4.22*

Submitted: 06/06/2021 Accepted: 19/11/2021 Published: 15/12/2021

Prognostic role of ΔNp63 expression in canine transitional cell carcinoma of the urinary bladder

Tomohiro Nishimori[1], Kiwamu Hanazono[1*], Kazuya Matsuda[1], Yoshio Kawamura[1], Tsuyoshi Kadosawa[1], Yoshifumi Endo[1] and Tsuyoshi Uchide[2]

[1]*School of Veterinary Medicine, Rakuno Gakuen University, Ebetsu, Japan*
[2]*Laboratory of Veterinary Molecular Pathology and Therapeutics, Tokyo University of Agriculture and Technology, Fuchu, Japan*

Abstract
Background: Decreased p63 protein expression in canine transitional cell carcinoma (TCC) of the urinary bladder is associated with vascular invasion of the tumor, metastasis, and shortened survival. ΔNp63, an isoform of p63, is downregulated in high-grade invasive urothelial carcinoma in humans. However, the clinical significance of ΔNp63 expression in canine urinary bladder tumors is unknown. Therefore, it is essential to investigate ΔNp63 expression patterns in TCC, the most common urinary bladder tumor in dogs.
Aim: This study aimed to evaluate the expression and role of ΔNp63 in canine TCC of the urinary bladder.
Methods: ΔNp63 expression was compared between the normal canine urinary bladder, polypoid cystitis, and TCC. The correlation of ΔNp63 expression with histopathological and clinical findings were further evaluated, and its usefulness as a prognostic factor was examined.
Results: We observed that ΔNp63 was highly expressed in dogs' normal urinary bladder and polypoid cystitis, and its expression levels were low in TCC. Furthermore, low levels of ΔNp63 expression were associated with vascular invasion, metastasis, and shortened survival in dogs with TCC.
Conclusion: These results indicate that ΔNp63 expression could serve as a valuable biomarker for invasion, metastasis, and prognosis of canine TCC of the urinary bladder.
Keywords: ΔNp63, Metastasis, Survival, Transitional cell carcinoma, Urinary bladder.

出典 https://www.openveterinaryjournal.com/nishimori-abstract-ovj-112
DOI: 10.5455/OVJ.2021.v11.i4.22
最終責任者 Kiwamu Hanazono (Corresponding Author)

Veterinary Immunology and Immunopathology 244 (2022) 110364



Contents lists available at ScienceDirect

Veterinary Immunology and Immunopathology

journal homepage: www.elsevier.com/locate/vetimm



Research paper

Effects of intra-articular inoculation with *Mycoplasma bovis* on immunological responses in calf joints

Koji Nishi [a,b], Yuki Hirano [a,c], Ayano Sato [d], Ayako Eguchi [a], Kazuya Matsuda [e], Miyuki Toda [e], Takafumi Watanabe [f], Tomohito Iwasaki [g], Naoki Takahashi [h], Marina Hosotani [f], Reina Watanabe [a], Toshihide Kato [d], Hiromichi Ohtsuka [d], Satoshi Gondaira [a,*], Hidetoshi Higuchi [a,*]

[a] *Animal Health Laboratory, Department of Veterinary Science, School of Veterinary Medicine, Rakuno Gakuen University, Ebetsu, Hokkaido, Japan*
[b] *NOSAI Okhotsk Monbetsu Veterinary Clinic, Monbetsu, Hokkaido, Japan*
[c] *Animal Research Center, Agricultural Research Department, Hokkaido Research Organization, Shintoku, Hokkaido, Japan*
[d] *Large Animal Clinical Science, Department of Veterinary Science, School of Veterinary Medicine, Rakuno Gakuen University, Ebetsu, Hokkaido, Japan*
[e] *Department of Veterinary Pathology, Department of Veterinary Science, School of Veterinary Medicine, Rakuno Gakuen University, Ebetsu, Hokkaido 069-8501, Japan*
[f] *Laboratory of Veterinary Anatomy, School of Veterinary Medicine, Rakuno Gakuen University, Ebetsu, Hokkaido, Japan*
[g] *Department of Food Science and Human Wellness, College of Agriculture, Food and Environment Science, Rakuno Gakuen University, Hokkaido, Japan*
[h] *Department of Veterinary Anatomy, College of Bioresource Sciences, Nihon University, Fujisawa, Kanagawa, Japan*

ARTICLE INFO

Keywords:
Arthritis
Inflammatory cytokines
Invasion
Matrix metalloproteinases
Mycoplasma bovis

ABSTRACT

Mycoplasma arthritis that caused by *Mycoplasma bovis* exhibit severe lameness. This disease is difficult to cure with antibiotics, but the detailed pathological mechanisms have not been fully clarified. In this study, we examined the effects of intra-articular inoculation with *M. bovis* on immunological responses in calf joints. We inoculated three calves each with *M. bovis* or phosphate buffer saline (control) into the right stifle joint and dissected them at 15 days postinoculation. *Mycoplasma bovis*–inoculated calves exhibited swelling of the stifle joint, increases in synovial fluid, fibrin deposition, and cartilage thinning. Intracellular *M. bovis* was detected in synovial tissues analyzed by immunohistochemistry and transmission electron microscopy. Messenger RNA expressions of interleukin (IL)-1β, IL-6, IL-8, IL-12p40, and IL-17A in synovial fluid cells and synovial tissues from *M. bovis*–inoculated calves were significantly higher than those from control calves. Protein levels of these cytokines in synovial fluid from *M. bovis*–inoculated calves were markedly higher than those from control calves. Our study clarified that inoculation with *M. bovis* into the stifle joint induced the production of inflammatory cytokines by synovial fluid cells and synovial tissues, causing a severe inflammatory response in joints. Additionally, *M. bovis* could invade cells in synovial tissues, which may have aided it in evading antibiotics and host immune surveillance.

出典　https://doi.org/10.1016/j.vetimm.2021.110364
最終責任者　Hidetoshi Higuchi (Corresponding Author)

人獣共通感染症学（Zoonotic Disease）

Yasukazu Muramatsu

Professor

教授　村松　康和

Ⅰ．筆頭または責任著者　＜First or Corresponding Author＞

Ⅱ．その他＜Others＞

1) Zika Virus Potential Vectors among Aedes Mosquitoes from Hokkaido, Northern Japan: Implications for Potential Emergence of Zika Disease.
Uchida L, Shibuya M, Morales-Vargas R. E, Hagiwara K, **Muramatsu Y.**
Pathogens 10: 938. doi: 10.3390/pathogens10080938.

2) Isolation and Characterization of Mosquito-Associated *Spiroplasma cantharicola* from *Aedes japonicus* Collected in Hokkaido, Japan.
Shimooka M, Sakurai Y, **Muramatsu Y**, Leo Uchida.
Insects 2021 12: 1056. doi: 10.3390/insects12121056.

3) *Cryptosporidium* sp. Mrb001 detected from *Myodes rufocanus bedfordiae*, an indigenous vole of Hokkaido, Japan
MuramatsuY, Uchida L, Tamura Y, Asakawa M.
Bull. Rakuno Gakuen Univ. *in press*

pathogens

MDPI

Article

Zika Virus Potential Vectors among *Aedes* Mosquitoes from Hokkaido, Northern Japan: Implications for Potential Emergence of Zika Disease

Leo Uchida [1,*], Miki Shibuya [1], Ronald Enrique Morales-Vargas [2], Katsuro Hagiwara [1] and Yasukazu Muramatsu [1]

[1] School of Veterinary Medicine, Rakuno Gakuen University, Ebetsu, Hokkaido 069-8501, Japan; s21361159@g.rakuno.ac.jp (M.S.); k-hagi@rakuno.ac.jp (K.H.); y-mrmt@rakuno.ac.jp (Y.M.)
[2] Department of Medical Entomology, Faculty of Tropical Medicine, Mahidol University, Ratchathewi, Bangkok 10400, Thailand; ronald.mor@mahidol.ac.th
* Correspondence: uchidaleo@rakuno.ac.jp; Tel.: +81-11-388-4828

Abstract: The Zika virus (ZIKV) is a rapidly expanding mosquito-borne virus that causes febrile illness in humans. *Aedes aegypti* and *Ae. albopictus* are the primary ZIKV vectors; however, the potential vector competence of other *Aedes* mosquitoes distributed in northern Japan (Palearctic ecozone) are not yet known. In this study, the susceptibility to Zika virus infection of three *Aedes* mosquitoes distributed in the main city of the northern Japan and their capacities as vectors for ZIKV were evaluated. Field-collected mosquitoes were fed ad libitum an infectious blood meal containing the ZIKV PRVABC59. The Zika virus was detected in the abdomen of *Ae. galloisi* and *Ae. japonicus* at 2–10 days post infection (PI), and from the thorax and head of *Ae. galloisi* at 10 days PI, resulting in 17.6% and 5.9% infection rates, respectively. The Zika virus was not detected from *Ae. punctor* at any time. Some northern Japanese *Aedes* could be suspected as vectors of ZIKV but the risk may be low when compared with major ZIKV vectors.

Keywords: Zika virus; susceptibility; *Aedes japonicus*; *Aedes galloisi*; *Aedes* mosquitoes; Palearctic ecozone

check for updates

Citation: Uchida, L.; Shibuya, M.; Morales-Vargas, R.E.; Hagiwara, K.; Muramatsu, Y. Zika Virus Potential Vectors among *Aedes* Mosquitoes from Hokkaido, Northern Japan: Implications for Potential Emergence of Zika Disease. *Pathogens* **2021**, *10*, 938. https://doi.org/10.3390/pathogens10080938

出典　PMID: 34451402 PMCID: PMC8399329 DOI: 10.3390/pathogens10080938
https://www.mdpi.com/2076-0817/10/8/938

最終責任者　Leo Uchida (First Author and Corresponding Author)

insects

MDPI

Article

Isolation and Characterization of Mosquito-Associated *Spiroplasma cantharicola* from *Aedes japonicus* Collected in Hokkaido, Japan

Makoto Shimooka, Yoshimi Sakurai, Yasukazu Muramatsu and Leo Uchida *

School of Veterinary Medicine, Rakuno Gakuen University, Ebetsu 069-8501, Hokkaido, Japan; s21761034@stu.rakuno.ac.jp (M.S.); s21561167@g.rakuno.ac.jp (Y.S.); y-mrmt@rakuno.ac.jp (Y.M.)
* Correspondence: uchidaleo@rakuno.ac.jp; Tel.: +81-11-388-4828

Simple Summary: *Spiroplasma*, which comprises a group of the smallest known bacteria, is commonly found in insects and plants. Some species of *Spiroplasma* have shown pathogenicity against mosquitoes and are expected to be useful vector control tools. In this study, we isolated *S. cantharicola* from the mosquito *Aedes japonicus* collected in Hokkaido, northern Japan. Field surveillance implied a relatively low prevalence of the bacteria in the local mosquitoes. Phylogenetic analysis showed that our isolate is closer to a strain of *S. cantharicola* isolated from mosquitoes in previous studies. Our isolate grew well in the R2 broth medium and grew into a visible colony on R2 broth agar. Co-culturing with mosquito-derived C6/36 cells resulted in slightly more bacterial growth than culturing without cells, showing the strong cytopathogenic effect of the cells. To our knowledge, this is the third report on the isolation of *S. cantharicola* from mosquitoes.

Abstract: Species of the genus *Spiroplasma* are common within arthropods and plants worldwide. Mosquito-associated *Spiroplasma* spp. have been reported to show pathogenicity toward mosquitoes, which serve as vectors of several infectious diseases that have detrimental effects on public health. Although *Spiroplasma* spp. are expected to have potential use as biological vector-control tools, characteristics such as their distribution, host species, and cytopathogenic effects (CPEs) are not well understood. In this study, we isolated a *Spiroplasma* sp. from a female *Aedes japonicus* collected in Hokkaido, northern Japan. Phylogenetic analysis based on the 16S rRNA gene sequence indicated our isolate was closely related to *S. cantharicola*. We screened 103 mosquito pools consisting of 3 genera and 9 species, but only detected *S. cantharicola* in the first isolation. In an in vitro assay, our isolate grew well at 28 °C, but no propagation was observed at 37 °C. Furthermore, the isolate showed strong CPE on a mosquito-derived cultured cell line (C6/36), and its propagation slightly increased when co-cultured with C6/36 cells. To our knowledge, this is the third report of the isolation of *S. cantharicola* from mosquitoes and the first case in Asia. Our findings provide epidemiological data on *S. cantharicola* distribution in the region.

Keywords: *Aedes japonicus*; C6/36 cells; cytopathogenic effect; Japan; mosquito; *Spiroplasma cantharicola*

check for updates

Citation: Shimooka, M.; Sakurai, Y.; Muramatsu, Y.; Uchida, L. Isolation and Characterization of Mosquito-Associated *Spiroplasma cantharicola* from *Aedes japonicus* Collected in Hokkaido, Japan. *Insects* **2021**, *12*, 1056. https://doi.org/10.3390/insects12121056

Academic Editors: Adriano Pinter and Karin Kirchgatter

Received: 14 October 2021
Accepted: 23 November 2021
Published: 25 November 2021

Publisher's Note: MDPI stays neutral with regard to jurisdictional claims in published maps and institutional affiliations.

出典　PMID: 34940145 PMCID: PMC8703607 DOI: 10.3390/insects12121056
https://www.mdpi.com/2075-4450/12/12/1056

最終責任者　Leo Uchida (Corresponding Author)

Cryptosporidium sp. *Mrb*001 detected from *Myodes rufocanus bedfordiae,* an indigenous vole of Hokkaido, Japan

Yasukazu Muramatsu[1]*, Leo Uchida[1], Yutaka Tamura[2], and Mitsuhiko Asakawa[3]

ABSTRACT. *Cryptosporidium* oocysts were detected from five of 111 grey red-backed voles (*Myodes rufocanus bedfordiae*) in a forestry area of Hokkaido, which is the northernmost island of Japan and is zoogeographically distinct from the mainland. The number of oocysts per gram of faeces from each vole ranged from 1.5×10^6 to 1.8×10^8. A partial sequence of small subunit 18S rDNA (SSU rDNA) obtained in this study was registered as *Cryptosporidium* sp. *Mrb*001 (GenBank accession no. AB477098) and had the highest similarity to *Cryptosporidium* sp. 05.1513.Rb (GenBank accession no. HM015880.1), which originated from drinking water in the United Kingdom (98.5%). Phylogenetic tree analysis indicated that *Cryptosporidium* sp. *Mrb*001 clustered with several waterborne *Cryptosporidium* isolates and other *Cryptosporidium* spp. that originated from voles that inhabit wetlands in Hokkaido. We provided information about this cryptosporidial parasite isolated from *Myodes* vole. (139 words)

KEYWORDS: Cryptosporidial parasite, small rodent, wetland, small subunit 18S rDNA

出典　酪農学園大学紀要（*in press*）

最終責任者　Yasukazu Muramatsu (First Author and Corresponding Author)

獣医麻酔学（Veterinary Anesthesiology）

Kazuto Yamashita

Professor

教授　山下　和人

Ⅰ．筆頭または責任著者　＜First or Corresponding Author＞

1）Effects of sevoflurane, propofol or alfaxalone on neuromuscular blockade produced by a single intravenous bolus of rocuronium in dogs.
Chen IY, Tamogi H, Wei Y, Kato K, Itami T, Sano T, **Yamashita K.**
Vet. Anaesth. Analg. Online ahead of print. 2021.
doi: 10.1016/j.vaa.2021.10.002.

Ⅱ．その他＜Others＞

1）Comparison of the anesthetic effects between 5 mg/kg of alfaxalone and 10 mg/kg of propofol administered intravenously in cats.
Tamura J, Oyama N, Fukui S, **Yamashita K.**
J. Vet. Med. Sci. 83:73-77. 2021. doi: 10.1292/jvms.20-0407.

2）The anesthetic effects of intramuscular alfaxalone in dogs premedicated with low-dose medetomidine and/or butorphanol.
Kato K, Itami T, Nomoto K, Endo Y, Tamura J, Oyama N, Sano T, **Yamashita K.**
J. Vet. Med. Sci. 83:53-61. 2021. doi: 10.1292/jvms.20-0330.

ARTICLE IN PRESS
Veterinary Anaesthesia and Analgesia xxxx, xxx, xxx

RESEARCH PAPER

Effects of sevoflurane, propofol or alfaxalone on neuromuscular blockade produced by a single intravenous bolus of rocuronium in dogs

I-Ying Chen, Haruka Tamogi, Yixian Wei, Keiko Kato, Takaharu Itami, Tadashi Sano & Kazuto Yamashita

Department of Small Animal Clinical Sciences, School of Veterinary Medicine, Rakuno Gakuen University, Ebetsu, Hokkaido, Japan

Corresponding. Kazuto Yamashita, Department of Small Animal Clinical Sciences, School of Veterinary Medicine, Rakuno Gakuen University, 582, Bunkyodai-Midorimachi, Ebetsu, Hokkaido 069-8501, Japan. E-mail: yamasita@rakuno.ac.jp

Abstract

Objective To compare the effects of sevoflurane, propofol and alfaxalone on the neuromuscular blockade induced by a single intravenous bolus of rocuronium in dogs.

Study design A randomized, prospective, crossover experimental study.

Animals A total of eight adult Beagle dogs (four female, four male), weighing 8.9–15.3 kg and aged 5–7 years.

Methods The dogs were anesthetized three times with 1.25× minimum alveolar concentration of sevoflurane (SEVO treatment) and 1.25× minimum infusion rate of propofol (PROP treatment) or alfaxalone (ALFX treatment) at intervals of ≥14 days. Neuromuscular function was monitored with train-of-four (TOF) stimulation of the peroneal nerve by acceleromyography. After recording the control TOF ratio (TOFRC), a single bolus dose of rocuronium (1 mg kg^{-1}) was administered intravenously. The times from rocuronium administration to achieving TOF count 0 (onset time), from achieving TOF count 0 to the reappearance of TOF count 4 (clinical blockade period), from 25% to 75% of TOFRC (recovery index) and from achieving TOF count 0 to TOF ratio/TOFRC >0.9 (total neuromuscular blockade duration) were recorded.

Results The onset time and recovery index did not differ among the treatments. The median clinical blockade period was longer in the SEVO treatment [27.3 (26.0–30.3) minutes] than in PROP [16.6 (15.4–18.0) minutes; $p = 0.002$] and ALFX [22.4 (18.6–23.1) minutes; $p = 0.017$] treatments; and longer in the ALFX treatment than in the PROP treatment ($p = 0.020$). The mean total neuromuscular blockade duration was longer in the SEVO treatment (43.7 ± 9.9 minutes) than in PROP (25.1 ± 2.7 minutes; $p < 0.001$) and ALFX (32.5 ± 8.4 minutes; $p = 0.036$) treatments.

Conclusions and clinical relevance Compared with alfaxalone and propofol, sevoflurane prolonged rocuronium-induced neuromuscular blockade by a significantly greater extent in dogs.

Keywords alfaxalone, dogs, neuromuscular blockade, propofol, rocuronium, sevoflurane.

Introduction

Rocuronium bromide, an aminosteroid, is a nondepolarizing neuromuscular blocking agent (NMBA). It has a faster onset as compared with that of vecuronium, but the duration of action is similar between the two (Marshall et al. 1994; Larijani et al. 1995; Kansanaho et al. 1997). Currently, rocuronium has widespread clinical application in veterinary practice and has been administered to dogs through intravenous (IV) boluses, incremental IV doses or constant rate infusion (CRI) to improve skeletal muscle relaxation during surgical procedures under general anesthesia (Dugdale et al. 2002; Alderson et al. 2007; Auer et al. 2007; Briganti et al. 2015; Haga et al. 2019). However, administration of NMBAs may lead to a residual block, which is the presence of a neuromuscular blockade during the postoperative period (Jones et al. 2015). Studies in humans have shown that sex, body weight, body temperature, concentration of volatile anesthetic agents and interval between the last NMBA administration and reversal agent administration are associated with a residual block (Vanlinthout et al. 1996; Srivastava & Hunter 2009; Khamtuikrua et al. 2017; Saager et al. 2019).

出典　doi: 10.1016/j.vaa.2021.10.002.
https://www.vaajournal.org/article/S1467-2987(21)00294-4/pdf
最終責任者　Kazuto Yamashita (Corresponding Author)

The Journal of Veterinary Medical Science

NOTE

Surgery

Comparison of the anesthetic effects between 5 mg/kg of alfaxalone and 10 mg/kg of propofol administered intravenously in cats

Jun TAMURA[1,2)]*, Norihiko OYAMA[1,2)], Sho FUKUI[1)] and Kazuto YAMASHITA[1)]

[1)]Departments of Small Animal Clinical Sciences, Rakuno Gakuen University, Ebetsu, Hokkaido 069-8501, Japan
[2)]Veterinary Teaching Hospital, Graduate School of Veterinary Medicine, Hokkaido University, Sapporo, Hokkaido 060-0018, Japan

J. Vet. Med. Sci.
83(1): 73–77, 2021
doi: 10.1292/jvms.20-0407

Received: 2 July 2020
Accepted: 4 November 2020
Advanced Epub:
8 January 2021

ABSTRACT. To compare the anesthetic effects after intravenous administration of alfaxalone or propofol without premedication, either alfaxalone (5 mg/kg) or propofol (10 mg/kg) was administered intravenously over 120 sec in 6 cats. Each cat received the alternate treatment at least a 7-day interval. Anesthetic effects (tolerance of intubation, behavior changes and neurodepressive score) and physiological parameters were evaluated. Both treatments produced a rapid loss of consciousness, no apnea, and physiological parameters were maintained within clinically acceptable ranges apart from transient hypoxemia. The degree of hypoxemia was greater after the propofol treatment compared with the alfaxalone treatment. During the recovery period, more adverse events (ataxia, muscular tremors) were observed after the alfaxalone treatment compared with the propofol treatment.

KEY WORDS: alfaxalone, anesthetic induction, feline, propofol

*Correspondence to: Tamura, J.: j-tamura@vetmed.hokudai.ac.jp

©2021 The Japanese Society of Veterinary Science

This is an open-access article distributed under the terms of the Creative Commons Attribution Non-Commercial No Derivatives (by-nc-nd) License. (CC-BY-NC-ND 4.0: https://creativecommons.org/licenses/by-nc-nd/4.0/)

出典　doi: 10.1292/jvms.20-0407.
https://www.ncbi.nlm.nih.gov/pmc/articles/PMC7870395/pdf/jvms-83-073.pdf

最終責任者　Jun Tamura (First Author and Corresponding Author)

The Journal of Veterinary Medical Science

FULL PAPER
Surgery

The anesthetic effects of intramuscular alfaxalone in dogs premedicated with low-dose medetomidine and/or butorphanol

Keiko KATO[1], Takaharu ITAMI[1]*, Ken NOMOTO[1], Yusuke ENDO[1], Jun TAMURA[1], Norihiko OYAMA[1], Tadashi SANO[2] and Kazuto YAMASHITA[1]

[1]Department of Small Animal Clinical Sciences, School of Veterinary Medicine, Rakuno Gakuen University, Ebetsu, Hokkaido 069-8501, Japan
[2]Department of Veterinary Nursing Sciences, School of Veterinary Medicine, Rakuno Gakuen University, Ebetsu, Hokkaido 069-8501, Japan

ABSTRACT. We aimed to evaluate the induction, anesthesia, and cardiorespiratory effects of intramuscular (IM) anesthetic protocol with alfaxalone following premedication with low-dose medetomidine, butorphanol, or a combination of both (medetomidine–butorphanol) in dogs. Six healthy beagles were administered 1, 2.5, or 5 mg/kg alfaxalone IM following premedication with low-dose medetomidine (5 µg/kg; MA-IM), butorphanol (0.3 mg/kg; BA-IM), or medetomidine-butorphanol (5 µg/kg and 0.3 mg/kg, respectively; MBA-IM). Each dog received 9 treatments with minimum 7-day washout period between treatments. Dogs were allowed to breath room air during anesthetic induction. We attempted endotracheal intubation after alfaxalone administration. Alfaxalone produced a dose-dependent anesthetic effect in each anesthetic protocol. Intubation was achieved in 4 out of 6 dogs that received MA-IM and BA-IM with 2.5 mg/kg alfaxalone and in all dogs that received MBA-IM with 1, 2.5, and 5 mg/kg alfaxalone. The median durations [minimum–maximum] of accepting intubation were 79 [0–89], 97 [84–120], and 117 [84–217] min, respectively. Hypotension (mean arterial blood pressure <60 mmHg) did not develop, but bradycardia (heart rate <60 beats/min) was observed in all dogs that received the MA-IM and MBA-IM protocols. Severe hypoxemia (percutaneous arterial oxygen saturation <90%) developed in 2 dogs that received MBA-IM with 5 mg/kg alfaxalone. We consider that the MA-IM and BA-IM protocols with ≥2.5 mg/kg alfaxalone and the MBA-IM protocol with 1–2.5 mg/kg alfaxalone could provide clinically useful and effective anesthesia without causing severe cardiorespiratory depression in healthy dogs.

KEY WORDS: alfaxalone, butorphanol, dog, intramuscular anesthesia, medetomidine

J. Vet. Med. Sci.
83(1): 53–61, 2021
doi: 10.1292/jvms.20-0330

Received: 1 June 2020
Accepted: 28 October 2020
Advanced Epub:
13 November 2020

*Correspondence to: Itami, T.: t-itami@rakuno.ac.jp
(Supplementary material: refer to PMC https://www.ncbi.nlm.nih.gov/pmc/journals/2350/)

©2021 The Japanese Society of Veterinary Science

This is an open-access article distributed under the terms of the Creative Commons Attribution Non-Commercial No Derivatives (by-nc-nd) License. (CC-BY-NC-ND 4.0: https://creativecommons.org/licenses/by-nc-nd/4.0/)

出典　doi: 10.1292/jvms.20-0330.
https://www.ncbi.nlm.nih.gov/pmc/articles/PMC7870407/pdf/jvms-83-053.pdf

最終責任者　Takaharu Itami (Corresponding Author)

生産動物内科学 (Farm Animal Internal Medicine)

Tatsuya Ando

Associate Professor

准教授　安藤　達哉

Ⅰ．筆頭または責任著者　＜First or Corresponding Author＞

Ⅱ．その他＜Others＞

1) Genetic stability of the open reading frame 2 (ORF2) of borna disease virus 1 (BoDV-1) distributed in cattle in Hokkaido
Sukmak M, Okamoto M, **Ando T,** Hagiwara K.
J. Vet.Med.Sci. 83(10) : 1526-1533 , 2021. doi: 10.1292/jvms.21-0115

The Journal of Veterinary Medical Science

FULL PAPER
Virology

Genetic stability of the open reading frame 2 (ORF2) of borna disease virus 1 (BoDV-1) distributed in cattle in Hokkaido

Manakorn SUKMAK[1,2], Minoru OKAMOTO[3], Tatsuya ANDO[3] and Katsuro HAGIWARA[3]*

[1]Department of Farm Resources and Production Medicine, Faculty of Veterinary Medicine, Kasetseart University, Kamphaeng Saen, 73140, Thailand
[2]Kamphaengsaen Veterinary Diagnostic Center (KVDC), Faculty of Veterinary Medicine, Kasetseart University, Kamphaeng Saen, 73140, Thailand
[3]School of Veterinary Medicine, Rakuno Gakuen University, Hokkaido 069-8501, Japan

ABSTRACT. Borna disease virus (BoDV) is a neurotropic virus that causes several infections in humans and neurological diseases in a wide range of animals worldwide. BoDV-1 has been molecularly and serologically detected in many domestic and wild animals in Japan; however, the genetic diversity of this virus and the origin of its infection are not fully understood. In this study, we investigated BoDV-1 infection and genetic diversity in samples collected from animals in Hokkaido between 2006 and 2020. The analysis was performed by focusing on the P region of BoDV-1 for virus detection. The presence of BoDV-1 RNA was observed in samples of brain tissue and various organs derived from persistently infected cattle. Moreover, after inoculation, BoDV-positive brains were isolated from neonatal rats. The gene sequences of the P region of BoDV obtained from the rat brain were in the same cluster as the P region of the virus isolated from the original bovine. Thus, genetic variation in BoDV-1 was extremely low. The phylogenetic analysis revealed that BoDV-1 isolates obtained in this study were part of the same cluster, which suggested that BoDV-1 of the same cluster was widespread among animals in Hokkaido.

KEY WORDS: borna disease, genetic variation, Japan, phylogenetic analysis

J. Vet. Med. Sci.
83(10): 1526–1533, 2021
doi: 10.1292/jvms.21-0155

Received: 14 March 2021
Accepted: 30 July 2021
Advanced Epub:
13 August 2021

出典　doi: 10.1292/jvms.21-0115
https://www.ncbi.nlm.nih.gov/pmc/articles/PMC8569879/

最終責任者　Katsuro Hagiwara (Corresponding Author)

伴侶動物外科学 (Companion Animal Surgery)

Mitsuhiro Isaka

Associate Professor

准教授　井坂　光宏

I. 筆頭または責任著者　＜First or Corresponding Author＞

1) Intestinal Complication with Myxomatous Mitral Valve Diseases in Chihuahuas.
Araki R, Iwanaga K, Ueda K, **Isaka M**
Front Vet Sci. 2021 Nov 23; 8 :777579. doi: 10.3389/fvets.2021.777579.

2) Intestinal fatty acid-binding protein and osteoprotegerin in anthracycline-induced rabbit models of dilated cardiomyopathy.
Isaka M, Araki R, Ueno H, Okamoto M.
Res Vet Sci. 2021 Nov; 140: 185-189. doi: 10.1016/j.rvsc.2021.09.007.

3) Effects of timolol maleate eye drops on experimentally dilated cardiomyopathy and healthy rabbits.
Isaka M, Hayashida R, Tamashima Y, Araki R.
Open Vet J. 2021 Jul-Sep;11(3):390-393. doi: 10.5455/OVJ.2021.v11.i3.9.

4) A retrospective study of 14 dogs with advanced heart failure treated with loop and hydrochlorothiazide.
Iwanaga K, Araki R, **Isaka M.**
Open Vet J. 2021 Jul-Sep;11(3):342-345. doi: 10.5455/OVJ.2021.v11.i3.2.

5) Surgical ventricular restoration for rabbit dilated cardiomyopathy model: Preliminary study.
Isaka M, Hayashida R, Tamashima Y, Araki R.
Res Vet Sci. 2021 May; 136: 373-376. doi: 10.1016/j.rvsc.2021.03.023.

6) Diagnosis of Isolated Cleft of the Anterior Mitral Leaflet in a Dog: A Case Study Using Real-Time Three-Dimensional Echocardiography.
Araki R, Iwanaga K, Ueda K, **Isaka M.**
Case Rep Vet Med. 2021 Jan 26; 2021: 6610526. doi: 10.1155/2021/6610526.

7) Vasoactive intestinal peptide in canine portosystemic shunt in the absence of portal hypertension.
Isaka M, Ueno H.

Open Vet J. 2021 Jan-Mar;11(1):39-41. doi: 10.4314/ovj.v11i1.7.

8) The Occurrence of Osteosarcoma after Tibial Fracture Repair in a Dog.
Isaka M, Kokubo D, Sakai T.
Open. Vet. J. 2021; 11(1): 11-13. doi: http://dx.doi.org/10.4314/ovj.v11i1.3

Ⅱ. その他＜Others＞

frontiers in Veterinary Science

ORIGINAL RESEARCH
published: 23 November 2021
doi: 10.3389/fvets.2021.777579

Intestinal Complication With Myxomatous Mitral Valve Diseases in Chihuahuas

R. Araki[1,2,3], *K. Iwanaga*[2], *Kazunori Ueda*[1] *and M. Isaka*[3]*

[1] Yokohama Namiki Dog & Cat Medical Center, Yokohama, Japan, [2] Tokyo Veterinary Cardiology Center, Fukasawa, Japan, [3] Department of Small Animal Clinical Sciences, School of Veterinary Medicine, Rakuno Gakuen University, Ebetsu, Japan

The effects of cardiac disease on the intestine have been reported in humans but not in dogs. We investigated the effects of myxomatous mitral valve disease (MMVD), which is capable of causing congestion and tissue hypoperfusion, on the intestine in Chihuahuas, a breed frequently encountered in clinical practice as the preferred breed for MMVD. In this study, 69 Chihuahuas were divided into four groups based on echocardiography and chest radiography: 19 healthy Chihuahuas (H) and 50 Chihuahuas with MMVD classified according to the ACVIM consensus (stage B1, B2, C/D). In all the cases, serum intestinal fatty acid-binding protein (I-FABP) and D/L-lactate concentrations, markers of intestinal mucosal injury, were measured. I-FABP was significantly higher in stage C/D Chihuahuas than in other groups ($p < 0.05$), and stage B2 was significantly higher than H ($p < 0.05$). D-lactate was significantly increased in stages B2 and C/D compared to H and stage B1 ($p < 0.05$). L-lactate was significantly higher in stage C/D Chihuahuas than in any other group ($p < 0.05$), and stage B2 was significantly higher than that in H and stage B1 ($p < 0.05$). Intestinal mucosal injury risk was significantly higher in Chihuahuas with heart failure due to MMVD, suggesting that the risk could increase with worsening heart disease. This is the first study to investigate the intestinal complications of MMVD, and further investigations a needed in the future.

Keywords: Chihuahuas, D-lactate, intestinal complication, intestinal fatty acid-binding protein, intestinal mucosal injury markers, myxomatous mitral valve disease

OPEN ACCESS

Edited by:
Ryou Tanaka,
Tokyo University of Agriculture and Technology, Japan

Reviewed by:
Corrin John Boyd,
Murdoch University, Australia
Luis Gustavo Cal Pereyra,
Universidad de la República, Uruguay

***Correspondence:**
M. Isaka
m-isaka@rakuno.ac.jp

Specialty section:
This article was submitted to Comparative and Clinical Medicine, a section of the journal Frontiers in Veterinary Science

出典　doi: 10.3389/fvets.2021.777579.
https://www.frontiersin.org/articles/10.3389/fvets.2021.777579/full

最終責任者　Mitsuhiro Isaka (Corresponding Author)

Research in Veterinary Science 140 (2021) 185–189

Contents lists available at ScienceDirect

Research in Veterinary Science

journal homepage: www.elsevier.com/locate/rvsc

Intestinal fatty acid-binding protein and osteoprotegerin in anthracycline-induced rabbit models of dilated cardiomyopathy

Mitsuhiro Isaka [a,*], Ryuji Araki [a], Hiroshi Ueno [a], Minoru Okamoto [b]

[a] Department of Small Animal Clinical Sciences, School of Veterinary Medicine, Rakuno Gakuen University, 582 Bunkyodai Midorimachi, Ebetsu, Hokkaido 069-8501, Japan

[b] Department of Veterinary Pathology, School of Veterinary Medicine, Rakuno Gakuen University, 582 Bunkyodai Midorimachi, Ebetsu, Hokkaido 069-8501, Japan

ARTICLE INFO

Keywords:
Daunorubicin
Intestinal fatty acid protein
Lactate
Liver
Osteoprotegerin
Rabbits

ABSTRACT

Anthracyclines are used for chemotherapy in small animal cancer patients. However, cardiotoxic complications are very common with anthracycline use and induce multi-organ complications. The purpose of this study was to investigate the associations between multi-organ complications, focusing on the liver and intestine, and the serum concentrations of intestinal fatty acid-binding protein (I-FABP) and osteoprotegerin (OPG) in rabbits with daunorubicin-induced dilated cardiomyopathy (DCM). Sixteen New Zealand white male rabbits (16–20 weeks old), weighing 2.4–3.65 kg, were randomly divided into the control ($n = 8$) and daunorubicin-induced DCM ($n = 8$) groups. The concentration of serum I-FABP was significantly elevated in the DCM group (201.9 ± 16.6 pg/mL) compared to the control group (152.2 ± 19.9 g/mL). Additionally, the concentration of serum lactate was markedly increased in the DCM group (0.16 ± 0.01 mM) compared to that in the control group (0.02 ± 0.01 mmol/mL). In addition, the OPG concentration was significantly higher in the DCM group (2.44 ± 0.14 ng/mL) than in the control group (0.1 ± 0.08 ng/mL). Although the histopathology of the ileum did not significantly differ between groups, pathological changes were observed in the livers of the DCM group animals. In conclusion, multi-organ complications were recognized in DCM models and were accompanied by elevated serum I-FABP and OPG concentrations.

出典　　doi: 10.1016/j.rvsc.2021.09.007.

https://www.sciencedirect.com/science/article/abs/pii/S0034528821002782?via%3Dihub

最終責任者　Mitsuhiro Isaka (First Author and Corresponding Author)

Open Veterinary Journal, (2021), Vol. 11(3): 390–393
ISSN: 2226-4485 (Print)
ISSN: 2218-6050 (Online)

Short Communication
DOI: *10.5455/OVJ.2021.v11.i3.9*

Submitted: 05/04/2021 Accepted: 21/06/2021 Published: 05/08/2021

Effects of timolol maleate eye drops on experimentally dilated cardiomyopathy and healthy rabbits

Mitsuhiro Isaka*, Reimi Hayashida, Yuumi Tamashima and Ryuji Araki

Department of Small Animal Clinical Sciences, School of Veterinary Medicine, Rakuno Gakuen University, Ebetsu, Japan

Abstract

Background: Dilated cardiomyopathy (DCM) is the most frequently diagnosed cardiomyopathy in rabbits. Timolol maleate (nonselective beta-blockers), which reduces the heart rate (HR) and blood pressure, has been used for glaucoma. However, this effect has not been assessed in a rabbit DCM model.

Aim: This study aimed to evaluate the circulatory effects of 0.5% timolol maleate eye drops on rabbit DCM models.

Methods: Rabbits were randomly divided into healthy (n = 8) and DCM rabbits (n = 8). Rabbit DCM models were established through intravenous administration of daunorubicin (4 mg/kg/week), an anthracycline anticancer drug, for 6 weeks. We measured the HR, mean arterial pressure (MAP), and echocardiography before (pre) and at 10, 30, 60, and 120 minutes after timolol maleate administration.

Results: Timolol maleate 0.5% eye drops significantly reduced the HR at 10, 30, and 60 minutes in DCM models and 10 minutes in healthy rabbits; however, there were no alterations in MAP. There was a significant fraction shortening elevation at 10 and 120 minutes in DCM models; moreover, there were marked ejection fraction elevations at all measurement points in only DCM models.

Conclusion: Timolol maleate eye drops exert several effects on the circulatory system in rabbit DCM models and healthy rabbits.

Keywords: Dilated cardiomyopathy, Eye drops, Rabbit, Timolol.

出典 doi: 10.5455/OVJ.2021.v11.i3.9.
https://www.ncbi.nlm.nih.gov/pmc/articles/PMC8541723/

最終責任者 Mitsuhiro Isaka (First Author and Corresponding Author)

Open Veterinary Journal, (2021), Vol. 11(3): 342–345
ISSN: 2226-4485 (Print)
ISSN: 2218-6050 (Online)
Short Communication
DOI: *10.5455/OVJ.2021.v11.i3.2*

Submitted: 01/04/2021 Accepted: 10/06/2021 Published: 10/07/2021

A retrospective study of 14 dogs with advanced heart failure treated with loop diuretics and hydrochlorothiazide

Koji Iwanaga[1], Ryuji Araki[1,2,3] and Mitsuhiro Isaka[3]*

[1]*Tokyo Veterinary Cardiology Center, Tokyo, Japan*
[2]*Yokohama Yamate Dog & Cat Medical Center, Kanagawaken, Japan*
[3]*Department of Small Animal Clinical Sciences, School of Veterinary Medicine, Rakuno Gakuen University, Ebetsu, Japan*

Abstract

Background: The use of thiazide diuretics is recommended in the American College of Veterinary Internal Medicine guidelines for advanced heart failure due to mitral insufficiency (MI) in dogs. However, there are no large-scale reports of the use of thiazide diuretics in dogs with advanced heart failure.

Aim: This retrospective study evaluated the therapeutic effect of concomitant hydrochlorothiazide (HTCZ) with loop diuretics in dogs with heart failure.

Methods: The study included 14 dogs diagnosed with advanced pulmonary edema with MI at two facilities. In all cases, high-dose loop diuretics (torsemide; 0.78–4 mg/kg/day) did not improve pulmonary edema. The results of the echocardiography and renal function tests before and after the administration of HTCZ (0.2–0.84 mg/kg/day) in addition to torsemide were statistically compared.

Results: The echocardiographic data demonstrated significant improvement in relation to cardiac stress; left atrium to the aorta ratio, normalized left ventricular internal dimension in diastole, and E wave velocity (*m/s*) after HTCZ administration. However, blood urea nitrogen and creatinine levels increased, and potassium levels decreased, indicating a decline in renal function following HTCZ administration.

Conclusion: This study suggests that the administration of HTCZ in combination with loop diuretics may be beneficial during advanced heart failure due to MI in dogs. The results can also be extended to patients who are resistant to loop diuretics, resulting in the improvement of cardiac function. However, as the combination of HTCZ and loop diuretics can deteriorate renal function, caution should be exercised prior to making recommendations regarding its use, and renal function should be monitored.

Keywords: Echocardiology, Hydrochlorothiazide, Loop diuretic, Mitral insufficiency, Pulmonary edema.

出典　　doi: 10.5455/OVJ.2021.v11.i3.2.
https://www.ncbi.nlm.nih.gov/pmc/articles/PMC8541716/

最終責任者　Mitsuhiro Isaka (Corresponding Author)

Research in Veterinary Science 136 (2021) 373–376

Contents lists available at ScienceDirect

Research in Veterinary Science

journal homepage: www.elsevier.com/locate/rvsc

Surgical ventricular restoration for rabbit dilated cardiomyopathy model: Preliminary study

Mitsuhiro Isaka [a,*], Reimi Hayashida [a], Yumi Tamashima [a], Ryuji Araki [a,b]

[a] Department of Small Animal Clinical Sciences, School of Veterinary Medicine, Rakuno Gakuen University, 582 Bunkyodai Midorimachi, Ebetsu, Hokkaido 069-8501, Japan

[b] Yokohama Yamate Dog & Cat Medical Center, 27-4 Kasiwaba Nakaku, Yokohamasi, Kanagawaken 231-0866, Japan

ARTICLE INFO

Keywords:
Daunorubicin
Dilated cardiomyopathy
Left ventricular reconstruction
Rabbit model
Surgery

ABSTRACT

Dilated cardiomyopathy (DCM) is a common cardiovascular disease in dogs. It is primarily treated with beta-blockers. The aim of this preliminary study was to evaluate the efficacy of surgical ventricular restoration on daunorubicin-induced DCM in rabbits. The DCM model was generated in six rabbits by intravenous administration of daunorubicin (4 mg/kg/week) for 6 weeks. Echocardiography was performed before and after left ventricular (LV) reconstruction surgery to evaluate the LV function. The surgery was performed using non-absorbent prosthetic sheets and 5–0 polypropylene sutures, between the left anterior descending branch and the circumflex branch of the left coronary artery. We measured LV function 3 weeks postoperatively and collected the hearts for histopathological examination. We observed significant improvements in the LV internal dimension volume at both end-diastole and end-systole compared to the preoperative values. Fraction shortening showed a substantial improvement from 23.8 ± 1.4% to 30.9 ± 1.3%. In addition, the ejection fraction increased from 35.3% to 51.9%. On histological examination, the left ventricular wall was markedly thin. Furthermore, we observed fibrosis between the myocardial cells around the sutured site. The LV volume and LV functions significantly improved postoperatively. However, further investigation is required to determine the long-term effects of surgical ventricular restoration.

出典　　doi: 10.1016/j.rvsc.2021.03.023.
https://www.sciencedirect.com/science/article/abs/pii/S0034528821000941?via%3Dihub

最終責任者　Mitsuhiro Isaka (First Author and Corresponding Author)

Hindawi
Case Reports in Veterinary Medicine
Volume 2021, Article ID 6610526, 3 pages
https://doi.org/10.1155/2021/6610526

Case Report

Diagnosis of Isolated Cleft of the Anterior Mitral Leaflet in a Dog: A Case Study Using Real-Time Three-Dimensional Echocardiography

Ryuji Araki,[1,2,3] Koji Iwanaga,[2] Kazunori Ueda,[1] and Mitsuhiro Isaka[2]

[1]*Yokohama Yamate Dog & Cat Medical Center, 27-4 Kashiwaba Naka-ku Yokohama, Kanagawa, Japan 231-0866*
[2]*Tokyo Veterinary Cardiology Center, 8-9-12 Izumi Building 2F, Fukazawa, Setagaya, Tokyo 158-0081, Japan*
[3]*Department of Small Animal Clinical Sciences, School of Veterinary Medicine, Rakuno Gakuen University, 582 Bunkyodai-Midorimachi, Ebetsu, Hokkaido 069-8501, Japan*

Correspondence should be addressed to Mitsuhiro Isaka; m-isaka@rakuno.ac.jp

Received 9 November 2020; Revised 23 December 2020; Accepted 19 January 2021; Published 27 January 2021

Academic Editor: Isabel Pires

Copyright © 2021 Ryuji Araki et al. This is an open access article distributed under the Creative Commons Attribution License, which permits unrestricted use, distribution, and reproduction in any medium, provided the original work is properly cited.

Isolated cleft of the anterior mitral leaflet (ICAML) in dogs without a septal defect is a rare pathological condition. Until now, only one paper has contributed to the detailed understanding of canine ICAML. Reports have confirmed that 3-dimensional echocardiography (3-DE) is a simple and fast imaging technique that is useful for the diagnosis of ICAML and morphological evaluation of the mitral valve in humans. However, to our knowledge, no studies have provided details about the effectiveness of 3-DE in ICAML diagnosis in dogs. Thus, we aimed to determine the usefulness of a diagnostic technique using 3-DE in a 2-year-old Cavalier King Charles Spaniel with ICAML that exhibited mild mitral valve regurgitation. ICAML was initially assessed by transthoracic two-dimensional echocardiography. A diagnosis of congenital mitral regurgitation due to ICAML and understanding of the morphological structure of the valve was established based on the 3-DE findings.

出典　　doi: 10.1155/2021/6610526.
https://www.ncbi.nlm.nih.gov/pmc/articles/PMC7857914/

最終責任者　Mitsuhiro Isaka (Corresponding Author)

Open Veterinary Journal, (2021), Vol. 11(1): 39–41
ISSN: 2226-4485 (Print)
ISSN: 2218-6050 (Online)

Short Communication
DOI: *http://dx.doi.org/10.4314/ovj.v11i1.7*

Submitted: 11/11/2020 Accepted: 07/01/2021 Published: 20/01/2021

Vasoactive intestinal peptide in canine portosystemic shunt in the absence of portal hypertension

Mitsuhiro Isaka* and Hiroshi Ueno

Department of Small Animal Clinical Sciences, School of Veterinary Medicine, Rakuno Gakuen University, Ebetsu, Japan

Abstract

Background: The congenital portosystemic shunt (PSS) is a common vascular anomaly in dogs. Vasoactive intestinal peptide (VIP) is produced in various organs (including the small intestine, large intestine, and pancreas), leading to abdominal vasodilation, increased blood flow, increased pancreatic blood flow, and promotion of pancreatic endocrine and exocrine secretions. However, there have been no reports on the concentration of VIP in the portal and peripheral veins in canine PSS.

Aim: The aim of this pilot study was to evaluate whether dogs with PSS have a different VIP concentration in their portal system in general.

Methods: Six dogs with an extrahepatic portosplenic shunt were included in the study. Blood samples were taken from the saphenous and portal veins during PSS ligation surgery with an amerid constrictor, to evaluate and compare the VIP concentration in both samples. VIP was measured using a commercial canine enzyme-linked immunosorbent assay kit.

Results: The breeds included Mongrels (n = 2), Norfolk Terriers (n = 1), Miniature Dachshunds (n = 1), and Maltese (n = 2), and their ages were 9.3 ± 6.5 months; the bodyweight was 3.3 ± 0.8 kg. The concentration of VIP in the saphenous vein was 17.75 ± 13.88 pg/ml; on the contrary, the concentration of VIP in the portal vein was 29.7 ± 20.29 pg/ml. There was no significant difference in the VIP concentration between veins.

Conclusion: There was no difference in the VIP concentration between the portal and saphenous veins, suggesting a non-association between VIP and the PSS, in the absence of portal hypertension.

Keywords: Dogs, Portosystemic shunt, Vasoactive intestinal peptide.

出典 doi: 10.4314/ovj.v11i1.7.

https://www.ncbi.nlm.nih.gov/pmc/articles/PMC8057220/

最終責任者 Mitsuhiro Isaka (First Author and Corresponding Author)

Open Veterinary Journal, (2021), Vol. 11(1): 11–13
ISSN: 2226-4485 (Print)
ISSN: 2218-6050 (Online)
Case Report
DOI: *http://dx.doi.org/10.4314/ovj.v11i1.3*

Submitted: 11/11/2020 Accepted: 18/12/2020 Published: 08/01/2021

The occurrence of osteosarcoma after tibial fracture repair in a dog

Mitsuhiro Isaka*, Daiki Kokubo and Toshikazu Sakai

Department of Small Animal Clinical Sciences, School of Veterinary Medicine, Rakuno Gakuen University, Ebetsu, Japan

Abstract

Background: There are few detailed reports on implant-associated sarcoma in dogs; however, loose implants, metal type, and infection have not been shown as specific risk factors for this condition.

Case Description: A 14-year-old spayed female Labrador retriever was referred to our hospital with a main complaint of chronic right hind lameness after previous tibial fracture repair. On radiographs, rupture of the bone plate and screws with swelling of the surrounding soft tissue was observed, and osteosarcoma (OSA) was diagnosed after histopathological examinations. During amputation surgery, a plastic band was found associated with the implant.

Conclusion: Veterinary surgeons should be aware of implant-associated OSA and refrain from using non-medical materials in the implants. Furthermore, they should recommend the removal of orthopedic implants after fracture repair.

Keywords: Dogs, Fracture, Implant, Osteosarcoma, Repair.

出典　doi: http://dx.doi.org/10.4314/ovj.v11i1.3

https://www.ncbi.nlm.nih.gov/pmc/articles/PMC8057204/

最終責任者　Mitsuhiro Isaka (First Author and Corresponding Author)

獣医麻酔学（Veterinary Anesthesiology）

Takaharu Itami

Associate Professor

准教授　伊丹　貴晴

Ⅰ．筆頭または責任著者　＜First or Corresponding Author＞

3）The anesthetic effects of intramuscular alfaxalone in dogs premedicated with low-dose medetomidine and/or butorphanol.
Kato K, **Itami T**, Nomoto K, Endo Y, Tamura J, Oyama N, Sano T, Yamashita K.
J. Vet. Med. Sci. 83:53-61. 2021. doi: 10.1292/jvms.20-0330.

Ⅱ．その他＜Others＞

2）Effects of sevoflurane, propofol or alfaxalone on neuromuscular blockade produced by a single intravenous bolus of rocuronium in dogs.
Chen IY, Tamogi H, Wei Y, Kato K, **Itami T**, Sano T, Yamashita K.
Vet. Anaesth. Analg. Online ahead of print. 2021.
doi: 10.1016/j.vaa.2021.10.002.

4）Postoperative improvement of megaesophagus and esophageal motility in a 19-day-old puppy with gastroesophageal intussusception.
Takeuchi R, Takagi S, Hosoya K, Ohta H, **Itami T**, Okumura M.
J. Vet. Med. Sci. 83:1740-1744. 2021. doi: 10.1292/jvms.21-0384.

5）The effects of gel pad thickness on the evaluation of skin structures using ultrasonography in normal dogs.
Chhay S, Hanazono K, Kitahara J, Hori A, Miyoshi K, **Itami T**, Endoh D, Nakade T.
J. Vet. Med. Sci. 83:1472-1475. 2021. doi: 10.1292/jvms.21-0086.

The Journal of Veterinary Medical Science

FULL PAPER
Surgery

The anesthetic effects of intramuscular alfaxalone in dogs premedicated with low-dose medetomidine and/or butorphanol

Keiko KATO[1], Takaharu ITAMI[1]*, Ken NOMOTO[1], Yusuke ENDO[1], Jun TAMURA[1], Norihiko OYAMA[1], Tadashi SANO[2] and Kazuto YAMASHITA[1]

[1]Department of Small Animal Clinical Sciences, School of Veterinary Medicine, Rakuno Gakuen University, Ebetsu, Hokkaido 069-8501, Japan
[2]Department of Veterinary Nursing Sciences, School of Veterinary Medicine, Rakuno Gakuen University, Ebetsu, Hokkaido 069-8501, Japan

ABSTRACT. We aimed to evaluate the induction, anesthesia, and cardiorespiratory effects of intramuscular (IM) anesthetic protocol with alfaxalone following premedication with low-dose medetomidine, butorphanol, or a combination of both (medetomidine–butorphanol) in dogs. Six healthy beagles were administered 1, 2.5, or 5 mg/kg alfaxalone IM following premedication with low-dose medetomidine (5 µg/kg; MA-IM), butorphanol (0.3 mg/kg; BA-IM), or medetomidine-butorphanol (5 µg/kg and 0.3 mg/kg, respectively; MBA-IM). Each dog received 9 treatments with minimum 7-day washout period between treatments. Dogs were allowed to breath room air during anesthetic induction. We attempted endotracheal intubation after alfaxalone administration. Alfaxalone produced a dose-dependent anesthetic effect in each anesthetic protocol. Intubation was achieved in 4 out of 6 dogs that received MA-IM and BA-IM with 2.5 mg/kg alfaxalone and in all dogs that received MBA-IM with 1, 2.5, and 5 mg/kg alfaxalone. The median durations [minimum–maximum] of accepting intubation were 79 [0–89], 97 [84–120], and 117 [84–217] min, respectively. Hypotension (mean arterial blood pressure <60 mmHg) did not develop, but bradycardia (heart rate <60 beats/min) was observed in all dogs that received the MA-IM and MBA-IM protocols. Severe hypoxemia (percutaneous arterial oxygen saturation <90%) developed in 2 dogs that received MBA-IM with 5 mg/kg alfaxalone. We consider that the MA-IM and BA-IM protocols with ≥2.5 mg/kg alfaxalone and the MBA-IM protocol with 1–2.5 mg/kg alfaxalone could provide clinically useful and effective anesthesia without causing severe cardiorespiratory depression in healthy dogs.

KEY WORDS: alfaxalone, butorphanol, dog, intramuscular anesthesia, medetomidine

J. Vet. Med. Sci.
83(1): 53–61, 2021
doi: 10.1292/jvms.20-0330

Received: 1 June 2020
Accepted: 28 October 2020
Advanced Epub:
13 November 2020

*Correspondence to: Itami, T.: t-itami@rakuno.ac.jp
(Supplementary material: refer to PMC https://www.ncbi.nlm.nih.gov/pmc/journals/2350/)

©2021 The Japanese Society of Veterinary Science

This is an open-access article distributed under the terms of the Creative Commons Attribution Non-Commercial No Derivatives (by-nc-nd) License. (CC-BY-NC-ND 4.0: https://creativecommons.org/licenses/by-nc-nd/4.0/)

出典　doi: 10.1292/jvms.20-0330.
https://www.ncbi.nlm.nih.gov/pmc/articles/PMC7870407/pdf/jvms-83-053.pdf

最終責任者　Takaharu Itami (Corresponding Author)

ARTICLE IN PRESS
Veterinary Anaesthesia and Analgesia xxxx, xxx, xxx

RESEARCH PAPER

Effects of sevoflurane, propofol or alfaxalone on neuromuscular blockade produced by a single intravenous bolus of rocuronium in dogs

I-Ying Chen, Haruka Tamogi, Yixian Wei, Keiko Kato, Takaharu Itami, Tadashi Sano & Kazuto Yamashita

Department of Small Animal Clinical Sciences, School of Veterinary Medicine, Rakuno Gakuen University, Ebetsu, Hokkaido, Japan

Corresponding. Kazuto Yamashita, Department of Small Animal Clinical Sciences, School of Veterinary Medicine, Rakuno Gakuen University, 582, Bunkyodai-Midorimachi, Ebetsu, Hokkaido 069-8501, Japan. E-mail: yamasita@rakuno.ac.jp

Abstract

Objective To compare the effects of sevoflurane, propofol and alfaxalone on the neuromuscular blockade induced by a single intravenous bolus of rocuronium in dogs.

Study design A randomized, prospective, crossover experimental study.

Animals A total of eight adult Beagle dogs (four female, four male), weighing 8.9−15.3 kg and aged 5−7 years.

Methods The dogs were anesthetized three times with 1.25× minimum alveolar concentration of sevoflurane (SEVO treatment) and 1.25× minimum infusion rate of propofol (PROP treatment) or alfaxalone (ALFX treatment) at intervals of ≥14 days. Neuromuscular function was monitored with train-of-four (TOF) stimulation of the peroneal nerve by acceleromyography. After recording the control TOF ratio (TOFRC), a single bolus dose of rocuronium (1 mg kg^{-1}) was administered intravenously. The times from rocuronium administration to achieving TOF count 0 (onset time), from achieving TOF count 0 to the reappearance of TOF count 4 (clinical blockade period), from 25% to 75% of TOFRC (recovery index) and from achieving TOF count 0 to TOF ratio/TOFRC >0.9 (total neuromuscular blockade duration) were recorded.

Results The onset time and recovery index did not differ among the treatments. The median clinical blockade period was longer in the SEVO treatment [27.3 (26.0−30.3) minutes] than in PROP [16.6 (15.4−18.0) minutes; $p = 0.002$] and ALFX [22.4 (18.6−23.1) minutes; $p = 0.017$] treatments; and longer in the ALFX treatment than in the PROP treatment ($p = 0.020$). The mean total neuromuscular blockade duration was longer in the SEVO treatment (43.7 ± 9.9 minutes) than in PROP (25.1 ± 2.7 minutes; $p < 0.001$) and ALFX (32.5 ± 8.4 minutes; $p = 0.036$) treatments.

Conclusions and clinical relevance Compared with alfaxalone and propofol, sevoflurane prolonged rocuronium-induced neuromuscular blockade by a significantly greater extent in dogs.

Keywords alfaxalone, dogs, neuromuscular blockade, propofol, rocuronium, sevoflurane.

Introduction

Rocuronium bromide, an aminosteroid, is a nondepolarizing neuromuscular blocking agent (NMBA). It has a faster onset as compared with that of vecuronium, but the duration of action is similar between the two (Marshall et al. 1994; Larijani et al. 1995; Kansanaho et al. 1997). Currently, rocuronium has widespread clinical application in veterinary practice and has been administered to dogs through intravenous (IV) boluses, incremental IV doses or constant rate infusion (CRI) to improve skeletal muscle relaxation during surgical procedures under general anesthesia (Dugdale et al. 2002; Alderson et al. 2007; Auer et al. 2007; Briganti et al. 2015; Haga et al. 2019). However, administration of NMBAs may lead to a residual block, which is the presence of a neuromuscular blockade during the postoperative period (Jones et al. 2015). Studies in humans have shown that sex, body weight, body temperature, concentration of volatile anesthetic agents and interval between the last NMBA administration and reversal agent administration are associated with a residual block (Vanlinthout et al. 1996; Srivastava & Hunter 2009; Khamtuikrua et al. 2017; Saager et al. 2019).

出典　doi: 10.1016/j.vaa.2021.10.002.
https://www.vaajournal.org/article/S1467-2987(21)00294-4/pdf
最終責任者　Kazuto Yamashita (Corresponding Author)

The Journal of Veterinary Medical Science

NOTE
Surgery

Postoperative improvement of megaesophagus and esophageal motility in a 19-day-old puppy with gastroesophageal intussusception

Ryo TAKEUCHI[1)#*], Satoshi TAKAGI[1)#], Kenji HOSOYA[2)], Hiroshi OHTA[3)], Takaharu ITAMI[1)] and Masahiro OKUMURA[2)]

[1)]Veterinary Teaching Hospital, Graduate School of Veterinary Medicine, Hokkaido University, Sapporo, Hokkaido 060-0018, Japan
[2)]Laboratory of Veterinary Surgery, Department of Veterinary Clinical Sciences, Graduate School of Veterinary Medicine, Hokkaido University, Sapporo, Hokkaido 060-0818, Japan
[3)]Laboratory of Veterinary Internal Medicine, Department of Veterinary Clinical Sciences, Graduate School of Veterinary Medicine, Hokkaido University, Sapporo, Hokkaido 060-0818, Japan

J. Vet. Med. Sci.
83(11): 1740–1744, 2021
doi: 10.1292/jvms.21-0384

Received: 6 July 2021
Accepted: 11 September 2021
Advanced Epub:
21 September 2021

ABSTRACT. Canine gastroesophageal intussusception (GEI) is a rare and life-threatening condition that requires prompt diagnosis and treatment. A 19-day-old Siberian Husky with a 4-day history of regurgitation was diagnosed with GEI based on the findings of computed tomography (CT) performed without anesthesia. Endoscopic reduction of intussusception was impossible; thus, surgical reduction by traction of the duodenum was performed. CT revealed improvement of megaesophagus 82 days postoperatively. Eleven months postoperatively, fluoroscopy showed recovery to nearly normal esophageal motility. Two years postoperatively, no clinical signs were reported. CT is useful to diagnose GEI in neonate puppies with poor abdominal fat and to assess the gastric edema and the anatomical association of stomach with other organs. Fluoroscopy is helpful for evaluating postoperative esophageal motility.

KEY WORDS: canine, computed tomography, fluoroscopy, gastroesophageal intussusception, megaesophagus

*Correspondence to: Takeuchi, R.: r.takeuchi@vetmed.hokudai.ac.jp
#These authors contributed equally to this work.

©2021 The Japanese Society of Veterinary Science

This is an open-access article distributed under the terms of the Creative Commons Attribution Non-Commercial No Derivatives (by-nc-nd) License. (CC-BY-NC-ND 4.0: https://creativecommons.org/licenses/by-nc-nd/4.0/)

出典　doi: 10.1292/jvms.21-0384.
https://www.ncbi.nlm.nih.gov/pmc/articles/PMC8636889/pdf/jvms-83-1740.pdf

最終責任者　Ryo Takeuchi (First Author and Corresponding Author)

The Journal of Veterinary Medical Science

NOTE

Internal Medicine

The effects of gel pad thickness on the evaluation of skin structures using ultrasonography in normal dogs

Sothavy CHHAY[1)], Kiwamu HANAZONO[1,2)]*, Jo KITAHARA[1)], Ai HORI[2)], Kenjiro MIYOSHI[1,2)], Takaharu ITAMI[1,2)], Daiji ENDOH[1)] and Tetsuya NAKADE[1,2)]

[1)]School of Veterinary Medicine, Rakuno Gakuen University, 582 Bunkyodai Midorimach, Ebetsu, Hokkaido 069-8501, Japan

[2)]Animal Medical Center, Rakuno Gakuen University, 582 Bunkyodai Midorimach, Ebetsu, Hokkaido 069-8501, Japan

J. Vet. Med. Sci.
83(9): 1472–1475, 2021
doi: 10.1292/jvms.21-0086

Received: 15 February 2021
Accepted: 14 July 2021
Advanced Epub:
26 July 2021

ABSTRACT. Gel pads are commonly used in skin ultrasonography; however, the effects of their thickness are unknown. This study investigated the effects of pad thickness on measurements of skin thickness in 10 beagle dogs. Sonograms to measure neck skin thickness were captured without pads and using pads with thicknesses of 3, 5, 10, and 20 mm. Without pads, acoustic shading was observed due to air bubbles in the coupling gel. With 20-mm pads, echogenic artifacts were observed on the skin surface. Entry echo with 20-mm pads was significantly higher than with 3-mm pads. This suggests that visibility of the skin structure could be affected when a gel pad is not used or when a thick gel pad is selected.

KEY WORDS: artifact, gel pad, normal dog, skin thickness, skin ultrasonography

*Correspondence to: Hanazono, K.: k-hanazono@rakuno.ac.jp

©2021 The Japanese Society of Veterinary Science

This is an open-access article distributed under the terms of the Creative Commons Attribution Non-Commercial No Derivatives (by-nc-nd) License. (CC-BY-NC-ND 4.0: https://creativecommons.org/licenses/by-nc-nd/4.0/)

出典　doi: 10.1292/jvms.21-0086.
https://www.ncbi.nlm.nih.gov/pmc/articles/PMC8498840/pdf/jvms-83-1472.pdf

最終責任者　Kiwamu Hanazono (Corresponding Author)

獣医解剖学（Veterinary Anatomy）

Hiromi Ueda

Associate Professor

准教授　植田　弘美

Ⅰ．筆頭または責任著者　＜First or Corresponding Author＞

1）Enhancement effect of hepatocellular mitochondrial activity in diabetic rats with orally administered Kampo medicine.
Ueda H, Ito Y, Nozaki T, Takahashi N, Hosotani M, Watanabe T.
The journal of comparative integrative medicine/ Japan. 27: 5-12. 2021.
https://iss.ndl.go.jp/books/R100000002-I027425812-00

Ⅱ．その他＜Others＞

1) Unique histological features of the tail skin of cotton rat (Sigmodon hispidus) related to caudal autotomy.
Hosotani M, Nakamura T, Ichii O, Irie T, Sunden Y, Hosny Ali Elewa Y, Watanabe T, **Ueda H**, Mishima T, Kon Y.
Biology open. 10. 2021. doi: 10.1242/bio.058230

2) Three-dimensional ultrastructure reconstruction of tendinous components at the bifurcation of the bovine superficial digital flexor tendon using array and STEM tomographies.
Takahashi N, Kametani K, Ota R, Tangkawattana P, Iwasaki T, Hasegawa Y, **Ueda H**, Hosotani M, Watanabe T.
Journal of Anatomy. 238: 63-72. 2021. doi: 10.1111/joa.13294

3) Anatomy and histology of the foramen of ovarian bursa opening to the peritoneal cavity and its changes in autoimmune disease-prone mice.
Hosotani M, Ichii O, Nakamura T, Nanba T, Islam R, Hosny Ali Elewa Y, Watanabe T, **Ueda H**, Kon Y.
Journal of Anatomy. 238: 73-85. 2021. doi: 10.1111/joa.13299

Original Article

Enhancement Effect of Hepatocellular Mitochondrial Activity in Diabetic Rats with Orally Administered Kampo Medicine

Hiromi Ueda, Yuta Ito, Tomoko Nozaki, Naoki Takahashi, Marina Hosotani, and Takafumi Watanabe

Laboratory of Anatomy, School of Veterinary Medicine, Rakuno Gakuen University,Ebetsu, Hokkaido 069-8501, Japan

(Received June 3, 2020／Accepted July 2, 2020)

Running head: Kampo Medicinal Effect in Diabetic Rat

Correspondence to: Ueda, H., Laboratory of Anatomy, School of Veterinary Medicine, Rakuno Gakuen University, 582 Bunkyodai-Midorimachi, Ebetsu, Hokkaido 069-8501, Japan.

Keywords: diabetes, liver, mitochondria, streptozotocin, Kampo medicines

Abstract

Zhen Qi hypoglycemic capsule (ZQHC) formulation is an anti-diabetic Kampo medication. We previously suggested that its anti-diabetic activity resulted from improvement in liver metabolism. However, the underlying pharmacological mechanism remains unknown. In this study, we investigated the efficacy of orally administered ZQHC in diabetes. Streptozotocin-induced diabetic Wistar male rats fed *ad libitum* a normal diet containing 4 % ZQHC for 30days were used. Collected rat blood and liver tissues were subjected to serobiochemical and morphological analyses. Blood aspartate aminotransferase (AST) and alanine transaminase (ALT) levels were lower in rats that were treated orally with ZQHC (ZQHC-rats) as compared to control - untreated diabetic rats. Similar to normal non-diabetic rats, hepatocellular fat-droplet accumulation was only rarely seen in ZQHC- treated rats. Moreover, the appearance and microscopic structure of mitochondria in ZQHC-rats were similar to the mitochondria of non-diabetic rats. ZQHC-rats showed significantly decreased swollen hepatocellular mitochondria as compared with untreated diabetic rats. Hepatocellular cytochrome c oxidase activity in ZQHC-rats was significantly higher than that in diabetic rats. These results suggest that orally administered ZQHC helps to sustain liver metabolism through the suppression of fat-droplet accumulation and maintenance of mitochondrial activities in diabetic conditions.

Introduction

Orally administered diabetic medicines provide beneficial effects but can have serious side-effects [1-3]. Consequently, the development of orally administered herbal treatment of diabetes has received considerable attention[4].

Zhen Qi hypoglycemic capsules (ZQHC) are a traditional Chinese herbal medicine that has been utilized as an anti-diabetic treatment in China despite the lack of supporting evidence

出典　https://iss.ndl.go.jp/books/R100000002-I027425812-00

最終責任者　Hiromi Ueda (First Author and Corresponding Author)

© 2021. Published by The Company of Biologists Ltd | Biology Open (2021) 10, bio058230. doi:10.1242/bio.058230

RESEARCH ARTICLE

Unique histological features of the tail skin of cotton rat (*Sigmodon hispidus*) related to caudal autotomy

Marina Hosotani[1,*], Teppei Nakamura[2,3,*,‡], Osamu Ichii[2,4], Takao Irie[5,6], Yuji Sunden[7], Yaser Hosny Ali Elewa[2,8], Takafumi Watanabe[1], Hiromi Ueda[1], Takashi Mishima[3] and Yasuhiro Kon[2]

ABSTRACT

Caudal autotomy in rodents is an evolutionarily acquired phenomenon enabling escape from predators, by discarding the tail skin after traumatic injuries. The histological mechanisms underlying caudal autotomy seem to differ among species. Cotton rats (*Sigmodon hispidus*), which are important laboratory rodents for human infectious diseases, possess a fragile tail. In this study, we compared the tail histology of cotton rats with that of laboratory rats (*Rattus norvegicus*), which have no fragility on their tail, to elucidate the process of rodent caudal autotomy. First, the cotton rats developed a false autotomy characterized by loss of the tail sheath with the caudal vertebrae remaining without tail regeneration. Second, we found the fracture plane was continuous from the interscale of the tail epidermis to the dermis, which was lined with an alignment of E-cadherin* cells. Third, we found an obvious cleavage plane between the dermis and subjacent tissues of the cotton-rat tail, where the subcutis was composed of looser, finer, and fragmented collagen fibers compared with those of the rat. Additionally, the cotton-rat tail was easily torn, with minimum bleeding. The median coccygeal artery of the cotton rat had a thick smooth muscle layer, and its lumen was filled with the peeled intima with fibrin coagulation, which might be associated with reduced bleeding following caudal autotomy. Taken together, we reveal the unique histological features of the tail relating to the caudal autotomy process in the cotton rat, and provide novel insights to help clarify the rodent caudal autotomy mechanism.

KEY WORDS: Cotton rat, Rat, Caudal autotomy, Tail histology, Collagen

[1]Laboratory of Veterinary Anatomy, Department of Veterinary Medicine, School of Veterinary Medicine, Rakuno Gakuen University, Ebetsu, Hokkaido 069-8501, Japan. [2]Laboratory of Anatomy, Department of Basic Veterinary Science, Faculty of Veterinary Medicine, Hokkaido University, Sapporo, Hokkaido, Japan. [3]Department of Biological Safety Research, Chitose Laboratory, Japan Food Research Laboratories, Chitose, Hokkaido, Japan. [4]Laboratory of Agrobiomedical Science, Faculty of Agriculture, Hokkaido University, Sapporo, Hokkaido, Japan. [5]Medical Zoology Group, Department of Infectious Diseases, Hokkaido Institute of Public Health, Sapporo, Hokkaido, Japan. [6]Laboratory of Veterinary Parasitic Diseases, Department of Veterinary Sciences, Faculty of Agriculture, Center for Animal Disease Control, University of Miyazaki, Miyazaki, Japan. [7]Laboratory of Veterinary Pathology, Faculty of Agriculture, Tottori University, Tottori 680-8550, Japan. [8]Department of Histology and Cytology, Faculty of Veterinary Medicine, Zagazig University, Zagazig, Egypt.
*These authors contributed equally to this work

‡Author for correspondence (nakamurate@vetmed.hokudai.ac.jp)

M.H., 0000-0003-0360-3380; T.N., 0000-0003-3204-0245; O.I., 0000-0002-6643-1554; T.I., 0000-0002-8733-0832; Y.K., 0000-0002-9859-6122

This is an Open Access article distributed under the terms of the Creative Commons Attribution License (https://creativecommons.org/licenses/by/4.0), which permits unrestricted use, distribution and reproduction in any medium provided that the original work is properly attributed.

Received 27 November 2020; Accepted 15 January 2021

INTRODUCTION

Autotomy, the phenomenon of discarding or shedding a part of the body, is preserved in some animal species and is generally considered a self-defense mechanism to escape from predators (Emberts et al., 2019). In vertebrates, many lizards are well known as species that can undergo autotomy of the tail, which is followed by subsequent regeneration (Zani, 1996). In mammals, several species of rodents have been reported to possess autotomy of the tail related to predator avoidance as well (Shargal et al., 1999). For example, spiny mice (*Acomys cahirinus*), eastern chipmunks (*Tamias striatus*), and degu (*Octodon degus*) shed their tail skin easily in response to traumatic injuries (Shargal et al., 1999). In contrast with the true autotomy in reptiles, where the entire tail including the caudal vertebra is lost, most instances of autotomy in rodents have been considered a false autotomy, where the tail skin is lost but the vertebra remains (Dubost and Gasc, 1987).

Autotomy in rodents has been reported in five families and at least 27 species, although the precise histology related to the autotomy mechanism varies among species (Shargal et al., 1999). The autotomy process in rodents includes two stages: rupture, and healing of tissue. Specifically for the former, in spiny mice, greater space occupied by hair follicles in the dermis and less absolute connective tissue have been associated with decreased skin elasticity (Seifert et al., 2012). However, the autotomy mechanism has been poorly understood in rodents, except for the spiny mouse, which has been well investigated because of their unique systemic regenerative ability of the injured skin (Shargal et al., 1999; Seifert et al., 2012). In particular, the lack of histological observations on the tail skin in rodents has made it difficult to understand the rupture process of tissue and the variety and/or similarity of mechanisms underlying caudal autotomy among species.

The cotton rat (*Sigmodon hispidus*) is a rodent that is distributed over most of the southern USA. They are classified in the family Cricetidae (with hamsters and gerbils) and belong to a different family from the laboratory rat (*Rattus norvegicus*) and the laboratory mouse (*Mus musculus*), which are classified as Muridae (Coe and Prince, 1996). The cotton rat has been selected as a laboratory animal model in the field of infectious research because it can faithfully reproduce human infectious diseases (Boukhvalova et al., 2009). In addition to its utility in infectious disease research, to date we have reported interesting systemic pathological phenotypes of cotton rats, including chronic kidney disease, chronic anemia, and metabolic disorders (Ichii et al., 2016, 2018, 2020; Nakamura et al., 2019). In addition, the interesting characteristics of cotton rats include a fragile tail (i.e. autotomy); they therefore should not be captured by the tail, as they may spin and shed the tail skin to run away (Faith et al., 1977). Hence, cotton rats can be a useful laboratory animal not only to explore several human diseases but also to investigate the mechanisms underlying the expression of biological characteristics in animals, such as caudal autotomy.

出典　doi: 10.1242/bio.058230
https://onlinelibrary.wiley.com/doi/10.1111/joa.13299.

最終責任者　Teppei Nakamura (Corresponding Author)

FULL TEXT LINKS

WILEY Full Text Articles

J Anat. 2021 Jan;238(1):63-72. doi: 10.1111/joa.13294. Epub 2020 Aug 14.

Three-dimensional ultrastructure reconstruction of tendinous components at the bifurcation of the bovine superficial digital flexor tendon using array and STEM tomographies

Naoki Takahashi [1], Kiyokazu Kametani [1], Ryo Ota [2], Prasarn Tangkawattana [1 3], Tomohito Iwasaki [4], Yasuhiro Hasegawa [4], Hiromi Ueda [1], Marina Hosotani [1], Takafumi Watanabe [1]

Affiliations

PMID: 32794178 PMCID: PMC7754896 (available on 2023-01-01) DOI: 10.1111/joa.13294

Abstract

Tendons transmit force from muscle to bone for joint movement. Tenocytes are a specialized type of fibroblast that produces collagen fibrils in tendons. Their cytoplasmic processes form a network surrounding collagen fibrils to define a collagen fibre. Glycosaminoglycan (GAG) chains link collagen fibrils and adhere at the D-band of the collagen fibril. In this study, we used array and scanning transmission electron microscope (STEM) tomographies to reconstruct the three-dimensional ultrastructure of tenocytes, collagen fibres, collagen fibrils and GAG chains at the bifurcation of the bovine hindlimb superficial digital flexor tendon (SDFT). Collagen fibrils comprising a collagen fibre were not aligned uniformly and had at least two running directions. Spindle-shaped tenocytes were arranged along the long axis of a plurality of collagen fibres, where two groups of collagen fibrils with oblique directions to each other exhibited an oblique overlap of the two collagen fibril layers. Collagen fibrils with different running directions were observed in separating layers of about 300 nm in thickness and had diameters of 0-200 nm. About 40% of all collagen fibrils had a peak in the range of 20-40 nm. STEM analysis of the same site where the crossing of collagen fibres was observed by transmission electron microscopy demonstrated the outline of collagen fibrils with a clear D-banding pattern at a regular interval. Collagen fibrils were reconstructed three-dimensionally using continuous images acquired by STEM tomography, which confirmed that the collagen fibrils at the crossing sites did not orientate in layers, but were woven one by one. Higher magnification observation of GAG chains attached between the crossing collagen fibrils revealed numerous GAG chains arranged either vertically or obliquely on collagen fibrils. Furthermore, GAG chains at the cross of collagen fibrils connected the closest D-bands. GAG chains are thought to be universally present between collagen fibrils of the tendon. These observations by array and STEM tomographies increase our knowledge of the anatomy in the bifurcation of the bovine hindlimb SDFT and demonstrate the utility of these new imaging technologies.

Keywords: array tomography; bifurcation; bovine; collagen fibre; collagen fibril; glycosaminoglycan chain; scanning transmission electron microscopy; superficial digital flexor tendon; tenocyte; tomography.

© 2020 Anatomical Society.

出典　doi: 10.1111/joa.13294.
https://onlinelibrary.wiley.com/doi/epdf/10.1111/joa.13294

最終責任者　Takafumi Watanabe (Corresponding Author)

Journal of Anatomy / Volume 238, Issue 1 / p. 73-85

ORIGINAL PAPER

Anatomy and histology of the foramen of ovarian bursa opening to the peritoneal cavity and its changes in autoimmune disease-prone mice

Marina Hosotani ✉, Osamu Ichii, Teppei Nakamura, Takashi Namba, Md. Rashedul Islam, Yaser Hosny Ali Elewa, Takafumi Watanabe, Hiromi Ueda, Yasuhiro Kon

First published: 01 September 2020
https://doi.org/10.1111/joa.13299

Abstract

The ovarian bursa is a small peritoneal cavity enclosed by the mesovarium and mesosalpinx, which surrounds the ovaries and oviductal infundibulum in mammals. The ovarian bursa is considered as the structure facilitating the transport of ovulated oocytes into the oviduct. Our previous study revealed reduced oocyte pick-up function in the oviduct of lupus-prone MRL/MpJ-Fas$^{lpr/lpr}$ mouse, suggesting the possibility of an escape of ovulated oocytes into the peritoneal cavity, despite the presence of an almost complete ovarian bursa in the mouse. In this study, we revealed anatomical and histological characteristics of the ovarian bursa in C57BL/6 N, MRL/MpJ, and MRL/MpJ-Fas$^{lpr/lpr}$ mice. All strains had the foramen of ovarian bursa (FOB), with a size of approximately 0.04 to 0.12 cm^2, surrounded by the ligament of ovarian bursa (LOB), which is part of the mesosalpinx. The LOB was partially lined with the cuboidal mesothelial cells and consisted of a thick smooth muscle layer in all strains. In 6-month-old MRL/MpJ-Fas$^{lpr/lpr}$ mice, in which the systemic autoimmune abnormality deteriorated and oocyte pick-up function was impaired, the size of the FOB tended to be larger than that of other strains. Additionally, in MRL/MpJ-Fas$^{lpr/lpr}$ mice at 6 months of age, there was infiltration by numerous immune cells in the mesosalpinx suspending the isthmus; however, the LOB prevented severe inflammation and showed deposition of collagen fibers. These results not only indicate that the FOB is a common structure within mice, but also imply the physiological function of the LOB and its role in maintaining the microenvironment around the ovary, as well as regulating healthy reproduction.

出典　doi: 10.1111/joa.13299
https://onlinelibrary.wiley.com/doi/10.1111/joa.13299
最終責任者　Marina Hosotani (First Author and Corresponding Author)

食品衛生学 (Food Microbiology and Food Safety)

Masaru Usui

Associate Professor

准教授　臼井　優

Ⅰ．筆頭または責任著者　＜First or Corresponding Author＞

1）Rapid and Simultaneous Detection of Fluoroquinolone- and Macrolide-resistant Campylobacter jejuni/coli in Retail Chicken Meat using CAMpylobacter Express Resistance Array (CAMERA).
Usui M*, Tateno S, Onozaki M, Misawa N, Suzuki Y, Tamura Y, Nakajima C*
Food Control. 123, 107815. 2021. doi:10.1016/j.foodcont.2020.107815

2）Genetic characterization of coliform bacterial isolates from environmental water in Thailand.
Tsunoda R, **Usui M***, Tagaki C, Fukuda A, Boonla C, Anomasiri W, Sukpanyatham N, Akapelwa ML, Nakajima C, Tamura Y, Suzuki Y*.
J Infect Chemother. 27, 722-728. 2021. DOI: 10.1016/j.jiac.2020.12.023

3）Decreased colistin resistance and mcr-1 prevalence in pig-derived Escherichia coli in Japan after banning colistin as a feed additive.
Usui M*, Nozawa Y, Fukuda A, Sato T, Yamada M, Makita K, Tamura Y.
J Glob Antimicrob Resist. 24. 383-386. 2021.
DOI: 10.1016/j.jgar.2021.01.016

4）Prevalence of antimicrobial-resistant Escherichia coli in the migratory bird (Anser albifrons) and their habitat in Miyajimanuma, Japan
Fukuda A, **Usui M***, Ushiyama K, Shrestha D, Hashimoto N, Sakata M, Minamoto T, Yoshida O, Murakami K, Tamura Y, Asai T.
Journal of Wildlife Diseases. 57:954-958. 2021. DOI: 10.7589/JWD-D-21-00006

5）Aerobic composting and anaerobic digestion decrease the copy numbers of antibiotic-resistant genes and the levels of lactose-degrading Enterobacteriaceae in dairy farms in Hokkaido, Japan
Katada S, Fukuda A, Nakajima C, Suzuki Y, Azuma T, Takei A, Takada H, Okamoto E, Kato T, Tamura Y, **Usui M***.

Front Microbiol. 12. 737420. 2021. DOI: 10.3389/fmicb.2021.737420

6) Characterization of reproductive microbiota of primiparous cows during early postpartum periods in the presence and absence of endometritis
Kudo H, Sugiura T, Higashi S, Oka K, Takahashi T, Kamiya S, Tamura Y, **Usui M***.
Front Vet. 8:736996. 2021. DOI: 10.3389/fvets.2021.736996

7) Campylobacter Express Resistance Array for detecting the presence of fluorqouinolone- and macrolide-resistant Campylobacter jejuni and Cammpylobacter coli in broiler farms.
Usui M*, Tase J, Onozaki M, Suzuki Y, Tamura Y, Nakajima C.
J Appl Microbiol. 2021. in press. DOI: 10.1111/jam.15390

8) Broad-host-range IncW plasmid harbouring tet(X) in Escherichia coli isolated from pigs in Japan.
Usui M*, Fukuda A, Suzuki Y, Nakajima C, Tamura Y.
J Glob Antimicrob Resist. 2021. in press. DOI: 10.1016/j.jgar.2021.12.012

II. その他＜Others＞

1) Seven-year surveillance of the prevalence of antimicrobial-resistant Escherichia coli isolates, with a focus on ST131 clones, among healthy people in Osaka, Japan.
Fukuda A, Nakamura H, Umeda K, Yamamoto K, Hirai Y, **Usui M**, Ogasawara J.
Int J Antimicrob Agent. 57, 106298. 2021.
DOI: 10.1016/j.ijantimicag.2021.106298

2) Prevalence of Colistin-Resistant Bacteria from Retail Meats in Japan.
Odoi J, Takayanagi S, Sugiyama M, **Usui M**, Tamura Y, Asai T.
Food Safety, 9, 48-56. 2021. DOI: 10.14252/foodsafetyfscj.D-21-00002

3) Complete genome sequence of Pseudomonas aeruginosa veterinary isolate, Pa12.
Nakamura K, Fujiki J, Furusawa T, Nakamura T, Gondaira S, Sasaki M, **Usui M,** Higuchi H, Sawa H, Tamura H, Iwano H.
Microbiol Resour Announc. 10, e0039821. 2021. DOI: 10.1128/MRA.00398-21

4) Complete genome sequence of a mcr-9 possessing Enterobacter asburiae isolated from a cat in Japan
Sato T, **Usui M**, Harada K, Fukushima Y, Nakajima C, Szuki Y, Yokota S.
Microbiol Resour Announc. 10, e0028121. 2021. DOI: 10.1128/MRA.00281-21

5) Complete genome sequence of a mcr-10-possessing Enterobacater roggenkampii isolated from a dog in Japan
Sato T, **Usui M**, Harada K, Fukushima Y, Nakajima C, Szuki Y, Yokota S.
Microbiol Resour Announc. 10:e0042621.2021. DOI: 10.1128/MRA.00426-21

6) Bacteriophage-induced galU deficienty region is involved in trade-off effects on the phage and fluoroquinolone sensitivity in Pseudomonas aeruginosa
Nakamura K, Fujiki J, Nakamura T, Furusawa T, Gondaira S, **Usui M**, Higuchi H, Tamura Y, Iwano H.
Virus Res. 306:198596. 2021.

Food Control 123 (2021) 107815

Contents lists available at ScienceDirect

Food Control

journal homepage: www.elsevier.com/locate/foodcont

Rapid and simultaneous detection of fluoroquinolone- and macrolide-resistant *Campylobacter jejuni/coli* in retail chicken meat using CAMpylobacter Express Resistance Array (CAMERA)

Masaru Usui [a,*], Sho Tateno [a], Masanobu Onozaki [b], Naoaki Misawa [c], Yasuhiko Suzuki [d,e], Yutaka Tamura [a], Chie Nakajima [d,e,**]

[a] School of Veterinary Medicine, Rakuno Gakuen University, Ebetsu, Hokkaido, Japan
[b] Kanto Chemical Co.Ltd., Tokyo, Japan
[c] Center for Animal Disease Control, University of Miyazaki, Miyazaki, Japan
[d] Division of Bioresources, Hokkaido University Research Center for Zoonosis Control, Sapporo, Hokkaido, Japan
[e] International Collaboration Unit, Research Center for Zoonosis Control, Hokkaido University, Hokkaido, Japan

ARTICLE INFO

Keywords:
Antimicrobial resistance
Campylobacter jejuni
Campylobacter coli
DNA microarray
Fluoroquinolones
Macrolides

ABSTRACT

A rapid method for the simultaneous detection of fluoroquinolone- and macrolide-resistant *Campylobacter jejuni/coli* in food products is long-awaited. In this study, we developed a DNA microarray-based method with primer extension, named CAMpylobacter Express Resistance Array (CAMERA). A series of oligonucleotide probes corresponding to each mutation in *gyrA* and *rrl* for fluoroquinolone and macrolide resistance, respectively, were selected and fixed on a membrane as capture probes for identifying *C. jejuni/coli* and detecting mutations conferring fluoroquinolone- and macrolide-resistance. The specificity was confirmed using 152 strains from livestock feces. Spiking of chicken meat samples revealed that CAMERA can detect 1–9 CFU/g *C. jejuni/coli*. Seventeen *Campylobacter* strains (16 *C. jejuni* and 1 *C. coli*) were isolated from 100 retail chicken meat samples via microbial culture. Using CAMERA, 16 of these 17 samples were positive for *C. jejuni/coli*, and the susceptibility to fluoroquinolone/macrolide could be determined (94% sensitivity and 100% specificity). The culture method requires more than 5–6 days for isolating *C. jejuni/coli* and determining antimicrobial susceptibility. In contrast, CAMERA requires <30 h from the beginning of the enrichment culture to the final determination of fluoroquinolone- and macrolide-resistant *C. jejuni/coli*. These results suggest that CAMERA is a rapid method for detecting *C. jejuni/coli* and is suitable for simultaneously determining the susceptibility to the two front-line drugs. This method may facilitate surveillance and control of fluoroquinolone- and macrolide-resistant *C. jejuni/coli* contamination in retail chicken meat.

出典　doi:10.1016/j.foodcont.2020.107815
https://doi.org/10.1016/j.foodcont.2020.107815
最終責任者　Masaru Usui and Chie Nakajima (Corresponding Author)

Contents lists available at ScienceDirect

Journal of Infection and Chemotherapy

journal homepage: http://www.elsevier.com/locate/jic

Original Article

Genetic characterization of coliform bacterial isolates from environmental water in Thailand

Risa Tsunoda [a], Masaru Usui [b, **], Chie Tagaki [b], Akira Fukuda [b], Chanchai Boonla [c], Wilai Anomasiri [c], Nop Sukpanyatham [d], Mwangala Lonah Akapelwa [a], Chie Nakajima [a, e], Yutaka Tamura [b, ***], Yasuhiko Suzuki [a, e, *]

[a] Division of Bioresources, Research Center for Zoonosis Control, Hokkaido University, Sapporo, Japan
[b] Laboratory of Food Microbiology and Food Safety, School of Veterinary Medicine, Rakuno Gakuen University, Ebetsu, Japan
[c] Department of Biochemistry, Chulalongkorn University, Bangkok, Thailand
[d] Quality Vet Product Co., Ltd, Klongsamwa District, Bangkok, Thailand
[e] International Collaboration Unit, Research Center for Zoonosis Control, Hokkaido University, Sapporo, Hokkaido, Japan

ARTICLE INFO

Article history:
Received 2 November 2020
Received in revised form
21 December 2020
Accepted 24 December 2020
Available online xxx

Keywords:
Enterobacteriaceae
Cefazoline-resistant
IncFrepB plasmid
bla$_{TEM}$
tetM

ABSTRACT

Introduction: In contrast to the study in other part of the world, information about characteristics of plasmids carrying antimicrobial resistance genes (ARGs) in *Enterobacteriaceae* derived from environmental water in tropical Asian countries including Thailand is limited. This study, therefore, aimed to gain insight into genetic information of antimicrobial resistance in environmental water in Thailand.
Methods: Coliform bacteria were isolated from environmental water collected at 20 locations in Thailand and identified. Then, susceptibility profiles to ampicillin, cefazoline, cefotaxime, kanamycin, ciprofloxacin, sulfamethoxazole, tetracycline, and nalidixic acid were assessed. In addition, antimicrobial resistant genes integrons, and replicon types were analyzed. And furthermore, plasmids carrying *bla*$_{TEM}$ and *tetM* were identified by S1-PFGE analysis and confirmed transmissibility by transconjugation experiments.
Results: In 130 coliform bacteria isolated, 89 were resistant to cefazoline while 41 isolates were susceptible. Cefazoline-resistant coliform bacteria were found to be significantly resistant to cefotaxime and tetracycline as compared to susceptible isolates. Hence, *bla*$_{TEM}$ and *tetM* correlating with β-lactam antibiotics and tetracycline, respectively, were analyzed found to co-localize on the IncFrepB plasmids in isolates from pig farms' wastewater by S1-PFGE analysis. And furthermore, transmissibility of the plasmids was confirmed.
Conclusions: Results obtained in this study suggested that ARGs in coliform bacteria may have been spreading on the farm via IncFrepB plasmids. Hence, appropriate use of antimicrobials and good hygiene management on the farm are required to prevent the emergence and spread of resistant bacteria.
© 2021 Japanese Society of Chemotherapy and The Japanese Association for Infectious Diseases. Published by Elsevier Ltd. All rights reserved.

出典 DOI: 10.1016/j.jiac.2020.12.023
https://doi.org/10.1016/j.jiac.2020.12.023
最終責任者 Masaru Usui and Yasuhiko Suzuki (Corresponding Author)

Journal of Global Antimicrobial Resistance 24 (2021) 383–386

Contents lists available at ScienceDirect

Journal of Global Antimicrobial Resistance

journal homepage: www.elsevier.com/locate/jgar

Decreased colistin resistance and *mcr-1* prevalence in pig-derived *Escherichia coli* in Japan after banning colistin as a feed additive

Masaru Usui[a,*], Yohei Nozawa[a], Akira Fukuda[a], Tomomi Sato[a], Michi Yamada[b], Kohei Makita[c], Yutaka Tamura[a]

[a] *Laboratory of Food Microbiology and Food Safety, Department of Health and Environmental Sciences, School of Veterinary Medicine, Rakuno Gakuen University, Ebetsu, Hokkaido, Japan*
[b] *Department of Sustainable Agriculture, Rakuno Gakuen University, Ebetsu, Hokkaido, Japan*
[c] *Laboratory of Veterinary Epidemiology, Department of Health and Environmental Sciences, School of Veterinary Medicine, Rakuno Gakuen University, Ebetsu, Hokkaido, Japan*

ARTICLE INFO

Article history:
Received 10 August 2020
Received in revised form 20 December 2020
Accepted 23 January 2021
Available online 3 February 2021

Keywords:
Colistin
Feed additive
Pig
Mobilized colistin resistance-1
Antibiotic resistance

ABSTRACT

Background: Antimicrobial resistance to colistin, a widely used feed additive for farm animals across the world, has raised public health concern in recent years. Since July 2018, its use as feed additive has been banned in Japan to reduce the spread of plasmid-based mobilized colistin resistance (*mcr*) genes and the subsequent development of colistin-resistant bacteria. Evaluating the effects of these measures is required.

Methods: We evaluated the effects of colistin use, as a feed additive, on colistin resistance in pigs ($n = 5$) from birth to finishing in the farm. Moreover, to evaluate changes in colistin resistance and *mcr* gene prevalence in response to colistin withdrawal, *E. coli* samples derived from pig faeces sourced from the fields of three geographically distinct farms were characterized before and after the withdrawal of colistin as a feed additive.

Results: Colistin-resistant *Escherichia coli* in pigs ($n = 5$) increased during the colistin administration period and decreased immediately after its end. In three fields, the colistin resistance rate and prevalence of *mcr-1* decreased immediately and significantly after the ban. However, colistin-resistant and *mcr-1*-positive *E. coli* were still detected in all three farm fields 12 months after the ban on colistin use.

Conclusion: Agricultural colistin use caused selective pressure that contributed to widespread *mcr* dissemination in Japan. Colistin resistance and the presence of *mcr* genes should be continuously monitored in food-producing animals.

© 2021 The Author(s). Published by Elsevier Ltd on behalf of International Society for Antimicrobial Chemotherapy. This is an open access article under the CC BY license (http://creativecommons.org/licenses/by/4.0/).

出典　DOI: 10.1016/j.jgar.2021.01.016
https://doi.org/10.1016/j.jgar.2021.01.016
最終責任者　Masaru Usui (Corresponding Author)

SHORT COMMUNICATIONS

DOI: 10.7589/JWD-D-21-00006

Journal of Wildlife Diseases, 57(4), 2021, pp. 000–000
© Wildlife Disease Association 2021

Prevalence of antimicrobial-resistant *Escherichia coli* in migratory Greater White-fronted Goose (*Anser albifrons*) and their habitat in Miyajimanuma, Japan

Akira Fukuda,[1] Masaru Usui,[1,8] Katsumi Ushiyama,[2] Dipti Shrestha,[3] Nagisa Hashimoto,[4] Masayuki K. Sakata,[5] Toshifumi Minamoto,[5] Osamu Yoshida,[6] Kanako Murakami,[1] Yutaka Tamura,[1] and Tetsuo Asai[7] [1]Laboratory of Food Microbiology and Food Safety, School of Veterinary Medicine, Rakuno Gakuen University, Ebetsu 069-8501, Japan; [2]Miyajimanuma Waterbird and Wetland Center, Oomagari 3, Nishibibai, Bibai 072-0057, Japan; [3]Division of Bioresources, Hokkaido University Research Center for Zoonosis Control, Kita 20, Nishi 10, Kita-ku, Sapporo 001-0020, Japan; [4]Faculty of Global Human Sciences, Kobe University, 3-11, Tsurukabuto, Nada-ku, Kobe, Hyogo 657-8501, Japan; [5]Graduate School of Human Development and Environment, Kobe University, 3-11, Tsurukabuto, Nada-ku, Kobe, Hyogo 657-8501, Japan; [6]Laboratory of Environmental Geochemistry, College of Agriculture, Food and Environment Sciences, Rakuno Gakuen University, Ebetsu 069-8501, Japan; [7]Department of Applied Veterinary Science, The United Graduated School of Veterinary Science, Gifu University, Yanagido Post 501-1193, Japan; [8]Corresponding author (email: usuima@rakuno.ac.jp)

ABSTRACT: The spread of antimicrobial-resistant bacteria (ARB) in natural environments including wild animals is a concern for public health. Birds cover large areas, and some fly across borders to migrate in large flocks. As a migratory bird, the Greater White-fronted Goose (*Anser albifrons*) travels to Miyajimanuma, North Japan, each spring and autumn. To investigate the ARB in migratory birds and their surroundings, we collected 110 fecal samples of *A. albifrons* and 18 water samples from Miyajimanuma in spring and autumn of 2019. Isolation of *Escherichia coli* was performed using selective agars with or without antimicrobials (cefazolin and nalidixic acid). Isolates of *E. coli* were recovered from 56 fecal samples (50.9%) and five water samples (27.8%) on agars without antimicrobials. No isolates were recovered on agars with antimicrobials. One *E. coli* isolate derived from a fecal sample exhibited resistance to β-lactams (ampicillin and cefazolin), whereas all other isolates exhibited susceptibility to all tested antimicrobials. The resistant isolate harbored bla_{ACC}, which could be transferred to other bacteria and confer resistance to β-lactams. These results suggest a low prevalence of antimicrobial resistance in wild migratory birds and their living environments; however, wild migratory birds sometimes carry ARB harboring transferrable antimicrobial resistance genes and therefore present a risk of spreading antimicrobial resistance.

veterinary clinical settings. These settings are thought to be hot spots of ARB, causing the spread to surroundings (Guenther et al. 2011). Surveillance of ARB is conducted in clinical settings; however, ARB in natural environments and wild animals are not surveyed sufficiently because of a wide variety of species and ecologies (Ramey and Ahlstrom 2020).

As an indicator bacterium of antimicrobial resistance (AMR) in warm-blooded animals, *Escherichia coli* is commonly used in national surveillance of clinical settings and research on wild animals (Berendonk et al. 2015; Asai et al. 2020). Moreover, *E. coli* is regarded as the indicator bacteria of fecal contamination from humans and animals in environments (Sen et al. 2019). Thus, *E. coli* is considered an appropriate indicator to estimate the prevalence of AMR derived from local humans and animals in various environments.

Environmental DNA (eDNA) is derived from organisms living there and is used to detect the presence of macro-organisms (Sakata et al. 2020). In aquatic ecosystems, detecting the presence of animals is possible

出典 DOI: 10.7589/JWD-D-21-00006
最終責任者 Masaru Usui (Corresponding Author)

frontiers in Microbiology

ORIGINAL RESEARCH
published: 30 September 2021
doi: 10.3389/fmicb.2021.737420

Aerobic Composting and Anaerobic Digestion Decrease the Copy Numbers of Antibiotic-Resistant Genes and the Levels of Lactose-Degrading Enterobacteriaceae in Dairy Farms in Hokkaido, Japan

*Satoshi Katada[1], Akira Fukuda[1], Chie Nakajima[2,3], Yasuhiko Suzuki[2,3], Takashi Azuma[4], Ayaka Takei[5], Hideshige Takada[5], Eiryu Okamoto[6], Toshihide Kato[7], Yutaka Tamura[1] and Masaru Usui[1]**

[1] *Laboratory of Food Microbiology and Food Safety, School of Veterinary Medicine, Rakuno Gakuen University, Ebetsu, Japan,* [2] *Division of Bioresources, Hokkaido University Research Center for Zoonosis Control, Sapporo, Japan,* [3] *International Collaboration Unit, Research Center for Zoonosis Control, Hokkaido University, Sapporo, Japan,* [4] *Department of Pharmacy, Osaka Medical and Pharmaceutical University, Takatsuki, Japan,* [5] *Laboratory of Organic Geochemistry, Faculty of Agriculture, Tokyo University of Agriculture and Technology, Fuchu, Japan,* [6] *Laboratory of Environmental Microbiology, College of Agriculture, Food, and Environment Sciences, Rakuno Gakuen University, Ebetsu, Japan,* [7] *Department of Large Animal Clinical Sciences, School of Veterinary Medicine, Rakuno Gakuen University, Ebetsu, Japan*

OPEN ACCESS

Edited by:
Krassimira Hristova, Marquette University, United States

Reviewed by:
Rishi Mahajan, Chaudhary Sarwan Kumar Himachal Pradesh Krishi Vishvavidyalaya, India
Terry Gentry, Texas A&M University, United States

***Correspondence:**
Masaru Usui
usuima@rakuno.ac.jp

Specialty section:
This article was submitted to Antimicrobials, Resistance and Chemotherapy, a section of the journal Frontiers in Microbiology

Received: *06 July 2021*
Accepted: *03 September 2021*
Published: *30 September 2021*

Citation:
Katada S, Fukuda A, Nakajima C, Suzuki Y, Azuma T, Takei A, Takada H, Okamoto E, Kato T, Tamura Y and Usui M (2021) Aerobic Composting and Anaerobic Digestion Decrease the Copy Numbers of Antibiotic-Resistant Genes and the Levels of Lactose-Degrading Enterobacteriaceae in Dairy Farms in Hokkaido, Japan. Front. Microbiol. 12:737420. doi: 10.3389/fmicb.2021.737420

Efficient methods for decreasing the spread of antimicrobial resistance genes (ARGs) and transfer of antimicrobial-resistant bacteria (ARB) from livestock manure to humans are urgently needed. Aerobic composting (AC) or anaerobic digestion (AD) are widely used for manure treatment in Japanese dairy farms. To clarify the effects of AC and AD on antimicrobial resistance, the abundances of antimicrobial (tetracycline and cefazolin)-resistant lactose-degrading Enterobacteriaceae as indicator bacteria, copy numbers of ARGs (tetracycline resistance genes and β-lactamase coding genes), and concentrations of residual antimicrobials in dairy cow manure were determined before and after treatment. The concentration of tetracycline/cefazolin-resistant lactose-degrading Enterobacteriaceae was decreased over 1,000-fold by both AC and AD. ARGs such as *tetA*, *tetB*, and bla_{TEM} were frequently detected and their copy numbers were significantly reduced by ~1,000-fold by AD but not by AC. However, several ARG copies remained even after AD treatment. Although concentrations of the majority of residual antimicrobials were decreased by both AC and AD, oxytetracycline level was not decreased after treatment in most cases. In addition, 16S rRNA gene amplicon-based metagenomic analysis revealed that both treatments changed the bacterial community structure. These results suggest that both AC and AD could suppress the transmission of ARB, and AD could reduce ARG copy numbers in dairy cow manure.

Keywords: aerobic composting, ampicillin resistance, anaerobic digestion, antimicrobial resistance, dairy cow, tetracycline resistance

出典 DOI: 10.3389/fmicb.2021.737420
最終責任者 Masaru Usui (Corresponding Author)

frontiers in Veterinary Science

ORIGINAL RESEARCH
published: 18 October 2021
doi: 10.3389/fvets.2021.736996

Characterization of Reproductive Microbiota of Primiparous Cows During Early Postpartum Periods in the Presence and Absence of Endometritis

Hayami Kudo[1,2], *Tomochika Sugiura*[3], *Seiya Higashi*[2], *Kentaro Oka*[2], *Motomichi Takahashi*[2], *Shigeru Kamiya*[2], *Yutaka Tamura*[1] *and Masaru Usui*[1]*

[1] *Department of Health and Environmental Sciences, School of Veterinary Medicine, Rakuno Gakuen University, Hokkaido, Japan,* [2] *Research Department, R&D Division, Miyarisan Pharmaceutical Co., Ltd., Saitama, Japan,* [3] *Department of Large Animal Clinical Science, School of Veterinary Medicine, Rakuno Gakuen University, Hokkaido, Japan*

OPEN ACCESS

Edited by:
Hasan Riaz, COMSATS Institute of Information Technology, Pakistan

Reviewed by:
Ricardo Zanella, The University of Passo Fundo, Brazil
Tara G. McDaneld, Agricultural Research Service, United States Department of Agriculture (USDA), United States

***Correspondence:**
Masaru Usui
usuima@rakuno.ac.jp

Specialty section:
This article was submitted to Livestock Genomics, a section of the journal Frontiers in Veterinary Science

Received: *09 July 2021*
Accepted: *21 September 2021*
Published: *18 October 2021*

Citation:
Kudo H, Sugiura T, Higashi S, Oka K, Takahashi M, Kamiya S, Tamura Y and Usui M (2021) Characterization of Reproductive Microbiota of Primiparous Cows During Early Postpartum Periods in the Presence and Absence of Endometritis. Front. Vet. Sci. 8:736996. doi: 10.3389/fvets.2021.736996

Endometritis has a major impact on fertility in postpartum dairy cows. Since previous studies showed an association between reproductive microbiota and perinatal disease, we monitored both bovine uterine and vaginal microbiota in primiparous cows to elucidate the effect of early postpartum microbiota on endometritis. Uterine and vaginal samples were collected at time points from pre-calving to 35 days postpartum (DPP), and analyzed by 16S rRNA sequencing, combined with ancillary bacterial culture. A total of seven healthy cows and seven cows diagnosed with endometritis on 35 DPP were used in the current study. The uterine and vaginal microbiota showed a maximum of 20.1% shared amplicon sequence variants (ASVs) at linked time points. 16S rRNA based analysis and traditional culture methods revealed that *Trueperella* showed a higher abundance in both uterus and vagina of the endometritis group compared to the healthy group on 21 DPP (*U*-test $p < 0.05$). Differential abundance analysis of the uterine microbiota showed that *Enterococcus* and six bacterial genera including *Bifidobacterium* were unique to the healthy group on the day of calving (0 DPP) and 28 DPP, respectively. In contrast, *Histophilus* and *Mogibacteriaceae* were characteristic bacteria in the vagina pre-calving in cows that later developed endometritis, suggesting that these bacteria could be valuable to predict clinical outcomes. Comparing the abundances of bacterial genera in the uterine microbiota, a negative correlation was observed between *Trueperella* and several bacteria including *Lactobacillus*. These results suggest that building an environment where there is an increase in bacteria that are generally recognized as beneficial, such as *Lactobacillus*, may be one possible solution to reduce the abundance of *Trueperella* and control endometritis.

Keywords: endometritis, reproductive tract microbiota, *Trueperella pyogenes*, early postpartum periods, probiotics

出典　DOI: 10.3389/fvets.2021.736996
最終責任者　Masaru Usui (Corresponding Author)

Journal of Applied Microbiology

Campylobacter Express Resistance Array for monitoring the prevalence of fluoroquinolone- and macrolide-resistant Campylobacter jejuni and Campylobacter coli in broiler farms

Journal:	*Journal of Applied Microbiology*
Manuscript ID	Draft
Wiley - Manuscript type:	Original Article
Date Submitted by the Author:	n/a
Complete List of Authors:	Usui, Masaru Tase, Junya Onozaki, Masanobu; Kanto Chemical Co Inc, International Business Dep. Suzuki, Yasuhiko; Hokkaido University, International Institute for Zoonosis Control Tamura, Yutaka Nakajima, Chie
Abstract:	Aims: The aim of the study was to develop a microarray-based method for detection of antibiotic-resistant Campylobacter in broiler farms to decrease the risk of contamination of chicken meat. Methods and Results: A combination of DNA microarray and primer extension for rapid and simultaneous detection of fluoroquinolone- and macrolide-resistant Campylobacter jejuni/Campylobacter coli, Campylobacter Express Resistance Array (CAMERA) was used to analyze chicken caecal droppings. CAMERA assays could detect at least 105 colony forming units of C. jejuni/C. coli g-1 of chicken caecal contents spiked with C. jejuni/C. coli. To compare the CAMERA method and direct culturing method for screening antibiotic-resistant C. jejuni/C. coli in poultry farms, chicken caecal droppings obtained from 42 poultry houses were analyzed using both methods. In total, 95.2% of the results (40/42 poultry houses) obtained using the CAMERA and culturing method were identical. In the remaining two poultry houses, the CAMERA could detect the prevalent strain of C. jejuni/C. coli based on results of the culturing method. Conclusions: The culturing method required >3 days to isolate and identify antibiotic-resistant C. jejuni/C. coli. In contrast, the CAMERA required only 6 hours. Significance and Impact of the Study: This method can facilitate quick screening and control of fluoroquinolone- and macrolide-resistant C. jejuni/C. coli in broiler farms.

出典　DOI: 10.1111/jam.15390
最終責任者　Masaru Usui (Corresponding Author)

Editor: Prof Francesco Iannelli

Journal Pre-proof



Broad-host-range IncW plasmid harbouring tet(X) in Escherichia coli isolated from pigs in Japan

Masaru Usui , Akira Fukuda , Yasuhiko Suzuki , Chie Nakajima , Yutaka Tamura

PII: S2213-7165(21)00286-1
DOI: https://doi.org/10.1016/j.jgar.2021.12.012
Reference: JGAR 1731

To appear in: *Journal of Global Antimicrobial Resistance*

Received date: 15 November 2021
Accepted date: 6 December 2021

Please cite this article as: Masaru Usui , Akira Fukuda , Yasuhiko Suzuki , Chie Nakajima , Yutaka Tamura , Broad-host-range IncW plasmid harbouring tet(X) in Escherichia coli isolated from pigs in Japan, *Journal of Global Antimicrobial Resistance* (2021), doi: https://doi.org/10.1016/j.jgar.2021.12.012

出典 DOI: 10.1016/j.jgar.2021.12.012
最終責任者 Masaru Usui (Corresponding Author)

Contents lists available at ScienceDirect

International Journal of Antimicrobial Agents

journal homepage: www.elsevier.com/locate/ijantimicag

Short Communication

Seven-year surveillance of the prevalence of antimicrobial-resistant *Escherichia coli* isolates, with a focus on ST131 clones, among healthy people in Osaka, Japan

Akira Fukuda[a,*], Hiromi Nakamura[b], Kaoru Umeda[b], Kaori Yamamoto[b], Yuji Hirai[b], Masaru Usui[a], Jun Ogasawara[b]

[a] *Laboratory of Food Microbiology and Food Safety, Department of Health and Environmental Sciences, School of Veterinary Medicine, Rakuno Gakuen University, Ebetsu, Japan*
[b] *Division of Microbiology, Osaka Institute of Public Health, Osaka, Japan*

ARTICLE INFO

Article history:
Received 21 August 2020
Accepted 30 January 2021
Available online xxx

Editor: Professor A Tsakris

Keywords:
Surveillance
ST131
Escherichia coli
bla gene
mcr gene

ABSTRACT

Objectives: *Escherichia coli* (*E. coli*) is an indicator of antimicrobial resistance, and some strains of *E. coli* cause infectious diseases. *E. coli* sequence type 131 (ST131) – a global antimicrobial-resistant pandemic *E. coli* clone – is frequently detected in clinical specimens. Antimicrobial-resistant bacteria are monitored via national surveillance in clinical settings; however, monitoring information in non-clinical settings is limited. This study elucidated antimicrobial resistance trends of *E. coli* and dissemination of ST131 among healthy people in non-clinical settings.

Methods: This study collected 517 *E. coli* isolates from healthy people in Osaka, Japan, between 2013 and 2019. It analysed antimicrobial susceptibility of the isolates and detected the *bla* and *mcr* genes in ampicillin-resistant and colistin-resistant isolates, respectively, and the ST131 clone.

Results: Antimicrobial resistance rates of the bacteria isolated from healthy people in non-clinical settings were lower than for those in clinical settings. The resistance of the isolates to cefotaxime (4.4%) and ciprofloxacin (13.5%) gradually increased during the study period. In 23 cefotaxime-resistant isolates, the most frequent *bla* genes belonged to the $bla_{CTX\text{-}M\text{-}9}$ group, followed by $bla_{CTX\text{-}M\text{-}1}$ goup, bla_{TEM} and $bla_{CMY\text{-}2}$. One *mcr-1*-harbouring colistin-resistant isolate was detected in 2016. The incidence of the *E. coli* O25b-ST131 clone was approximately 5% until 2015 and 10% after 2016.

Conclusion: Both ciprofloxacin resistance and O25b-ST131 clone frequency increased during the study period. Antimicrobial-resistant bacteria gradually spread in healthy people in non-clinical settings; one reason behind this spread was dissemination of global antimicrobial-resistant pandemic clones.

© 2021 Elsevier Ltd and International Society of Antimicrobial Chemotherapy. All rights reserved.

出典　DOI: 10.1016/j.ijantimicag.2021.106298

最終責任者　Akira Fukuda (Corresponding Author)

FOOD SAFETY

©2021 Food Safety Commission, Cabinet Office, Government of Japan
doi: 10.14252/foodsafetyfscj.D-21-00002
Food Safety 2021; Vol. 9, No. 2, 48–56

Original Article

Prevalence of Colistin-Resistant Bacteria among Retail Meats in Japan

Justice O. Odoi[1†], Sayo Takayanagi[2†], Michiyo Sugiyama[1], Masaru Usui[3], Yutaka Tamura[3] and Tetsuo Asai[1, 4]

[1]Department of Applied Veterinary Sciences, United Graduate School of Veterinary Sciences, Gifu University, 1-1 Yanagido, Gifu 501-1193, Japan.

[2]Faculty of Applied Biological Sciences, Gifu University, 1-1 Yanagido, Gifu 501-1193, Japan.

[3]Laboratory of Food Microbiology and Food Safety, School of Veterinary Medicine, Rakuno Gakuen University, 582 Midorimachi, Bunkyodai, Ebetsu 069-8501, Japan.

[4]Education and Research Center for Food Animal Health, Gifu University (GeFAH), 1-1 Yanagido, Gifu 501-1193, Japan.

Colistin (CST) is considered the last resort for the treatment of infectious diseases due to multidrug-resistant bacteria. Since the *mcr*-1 gene has been reported in *Enterobacteriaceae* isolated from food, animals, and humans in China, the prevalence of CST-resistant bacteria has been of great concern. Here, we investigated the prevalence of CST resistance and plasmid-mediated colistin-resistance genes (*mcr*) in gram-negative bacteria isolated among retail meats in Japan. CST-resistant bacteria were isolated from 310 domestic retail meats (103 chicken meat, 103 pork, and 104 beef) purchased between May 2017 and July 2018 from retail shops in Japan using CST-containing media and antimicrobial susceptibility testing. The *mcr* gene was investigated in isolates with a CST minimum inhibitory concentration of ≥1 μg/mL. Excluding the intrinsically CST-resistant isolates, CST-resistant bacteria were isolated from 39 of the total chicken meats (37.9%), 19 of the pork samples (18.4%), and 18 of the beef samples (17.3%). A total of 459 isolates were identified, out of which 99 were CST-resistant. CST resistance (resistance breakpoints: *Aeromonas*, >4 μg/mL; others, >2 μg/mL) was found in *Aeromonas* spp. (48/206, 23.3%), *Yersinia* spp. (5/112, 4.5%), *Escherichia coli* (23/39, 59%), *Citrobacter* spp. (4/26, 15.4%), *Klebsiella* spp. (2/23, 8.7%), *Raoultella* spp. (2/16, 12.5%), *Enterobacter* spp. (7/14, 50%), *Pseudomonas* spp. (1/8, 12.5%), *Pantoea* spp. (5/7, 71.4%), *Ewingella* spp. (1/4, 25%), and *Kluyvera* spp. (1/2, 50%). The *mcr* gene was detected in 16 isolates: *mcr*-1 in 14 isolates of *E. coli* from 10 chicken samples (9.7%), and *mcr*-3 in two isolates of *Aeromonas sobria* from pork and chicken samples (each 1.0%). The findings of this study highlight the necessity of surveillance of CST resistance and resistance genes in bacteria that contaminate retail meats.

Key words: colistin, gram-negative bacteria, plasmid-mediated colistin-resistance gene, retail meat

出典　DOI: 10.14252/foodsafetyfscj.D-21-00002
最終責任者　Tetsuo Asai (Corresponding Author)

AMERICAN SOCIETY FOR MICROBIOLOGY | Microbiology Resource Announcements

GENOME SEQUENCES

Complete Genome Sequence of a Veterinary *Pseudomonas aeruginosa* Isolate, Pa12

Keisuke Nakamura,[a] Jumpei Fujiki,[a] Takaaki Furusawa,[a] Tomohiro Nakamura,[a] Satoshi Gondaira,[b] Michihito Sasaki,[c] Masaru Usui,[d] Hidetoshi Higuchi,[b] Hirofumi Sawa,[c,e] Yutaka Tamura,[d,f] Hidetomo Iwano[a]

[a]Laboratory of Veterinary Biochemistry, Rakuno Gakuen University School of Veterinary Medicine, Ebetsu, Japan
[b]Laboratory of Animal Health, Rakuno Gakuen University School of Veterinary Medicine, Ebetsu, Japan
[c]Division of Molecular Pathobiology, International Institute for Zoonosis Control, Hokkaido University, Sapporo, Japan
[d]Laboratory of Food Microbiology and Food Safety, Rakuno Gakuen University School of Veterinary Medicine, Ebetsu, Japan
[e]International Collaboration Unit, International Institute for Zoonosis Control, Hokkaido University, Sapporo, Japan
[f]Center for Veterinary Drug Development, Rakuno Gakuen University, Ebetsu, Japan

ABSTRACT *Pseudomonas aeruginosa* causes various opportunistic infections in animals. Here, we report the complete genome sequence of *P. aeruginosa* strain Pa12, a fluoroquinolone-resistant isolate from a canine skin lesion. To expand the molecular antimicrobial characteristics of the isolate, the whole Pa12 genome was sequenced and assembled via long- and short-read platforms.

出典　DOI: 10.1128/MRA.00398-21

最終責任者　Jumpei Fujiki (Corresponding Author)

AMERICAN SOCIETY FOR MICROBIOLOGY | Microbiology Resource Announcements

GENOME SEQUENCES

Complete Genome Sequence of an *mcr-9*-Possessing *Enterobacter asburiae* Strain Isolated from a Cat in Japan

Toyotaka Sato,[a] Masaru Usui,[b] Kazuki Harada,[c] Yukari Fukushima,[a,d] Chie Nakajima,[d,e] Yasuhiko Suzuki,[d,e] Shin-ichi Yokota[a]

[a]Department of Microbiology, Sapporo Medical University School of Medicine, Sapporo, Japan
[b]Laboratory of Food Microbiology and Food Safety, Department of Health and Environmental Sciences, School of Veterinary Medicine, Rakuno Gakuen University, Ebetsu, Japan
[c]Department of Veterinary Internal Medicine, Tottori University, Tottori, Japan
[d]Division of Bioresources, Hokkaido University, Research Center for Zoonosis Control, Sapporo, Japan
[e]International Collaboration Unit, Research Center for Zoonosis Control, Hokkaido University, Sapporo, Japan

ABSTRACT We report the complete genome sequence of the *mcr-9*-possessing strain *Enterobacter asburiae* En30, isolated from a cat in Japan. The genome sequence was obtained by using long- and short-read sequencing.

出典　DOI: 10.1128/MRA.00281-21
最終責任者　Toyotaka Sato (Corresponding Author)

AMERICAN SOCIETY FOR MICROBIOLOGY | Microbiology Resource Announcements

GENOME SEQUENCES

Complete Genome Sequence of an *mcr-10*-Possessing *Enterobacter roggenkampii* Strain Isolated from a Dog in Japan

Toyotaka Sato,[a] Masaru Usui,[b] Kazuki Harada,[c] Yukari Fukushima,[a,d] Chie Nakajima,[d,e] Yasuhiko Suzuki,[d,e] Shin-ichi Yokota[a]

[a]Department of Microbiology, Sapporo Medical University School of Medicine, Sapporo, Japan
[b]Laboratory of Food Microbiology and Food Safety, Department of Health and Environmental Sciences, School of Veterinary Medicine, Rakuno Gakuen University, Ebetsu, Japan
[c]Department of Veterinary Internal Medicine, Tottori University, Tottori, Japan
[d]Division of Bioresources, Hokkaido University, Research Center for Zoonosis Control, Sapporo, Japan
[e]International Collaboration Unit, Research Center for Zoonosis Control, Hokkaido University, Sapporo, Japan

ABSTRACT The complete genome sequence of *mcr-10*-possessing *Enterobacter roggenkampii* En37, isolated from a dog in Japan, was determined. *mcr-10* was located on a 70,277-bp IncFIB plasmid without any additional antimicrobial resistance genes.

出典　DOI: 10.1128/MRA.00426-21

最終責任者　Toyotaka Sato (Corresponding Author)

Virus Research 306 (2021) 198596

Contents lists available at ScienceDirect

Virus Research

journal homepage: www.elsevier.com/locate/virusres

Fluctuating Bacteriophage-induced *galU* Deficiency Region is Involved in Trade-off Effects on the Phage and Fluoroquinolone Sensitivity in *Pseudomonas aeruginosa*

Keisuke Nakamura [a,#], Jumpei Fujiki [a,#,*], Tomohiro Nakamura [a], Takaaki Furusawa [a], Satoshi Gondaira [b], Masaru Usui [c], Hidetoshi Higuchi [b], Yutaka Tamura [c], Hidetomo Iwano [a]

[a] *Laboratory of Veterinary Biochemistry, Department of Veterinary Medicine, Rakuno Gakuen University, Ebetsu, Hokkaido, Japan*
[b] *Laboratory of Animal Health, Rakuno Gakuen University School of Veterinary Medicine, Ebetsu, Hokkaido, Japan*
[c] *Laboratory of Food Microbiology and Food Safety, Rakuno Gakuen University School of Veterinary Medicine, Ebetsu, Hokkaido, Japan*

ARTICLE INFO

Keywords:
Bacteriophage
galU
Pseudomonas aeruginosa
Phage resistance
Phage therapy
Trade-off
Fitness cost

ABSTRACT

Pseudomonas aeruginosa, which causes chronic infections, has demonstrated rapid acquisition of antimicrobial resistance (AMR). Therefore, bacteriophages have received significant attention as promising antimicrobial agents; however, previous trials have reported the occurrence of phage-resistant variants. *P. aeruginosa* has lost large chromosomal fragments via evolutionary selection by MutL. Mutants lacking *galU* and *hmgA*, located in close proximity, exhibit phage resistance and brown color phenotype since *hmgA* encodes a homogentisic acid metabolic enzyme and deletion of *galU* results in a lack of *O*-antigen polysaccharide and absence of the phage receptor. In the present study, we evaluated this mechanism for controlling phage resistance in *P. aeruginosa* veterinary isolate Pa12. Phage-resistant Pa12 brown mutants (brmts) with *galU* and *hmgA* deletions were isolated. Whole-genome sequencing of the brmts revealed that regions 148-27 kbp upstream and 261-110 kbp downstream of *galU* were largely deleted from the Pa12 parental chromosome. Furthermore, all of these fluctuating deleted sequences in Pa12 brmts, tentatively designated bacteriophage-induced *galU* deficiency (BigD) regions, harbor multi-drug efflux system genes (*mexXY*). Minimum inhibitory concentration (MIC) assays demonstrated that brmts altered sensitivity to antibiotics and exhibited increased levofloxacin sensitivity compared with the Pa12 parent. Orbifloxacin and enrofloxacin also effectively suppressed growth of the Pa12 brmts, suggesting that MexXY, which mediates quinolone efflux and is located in the BigD region, might be associated with restoration of fluoroquinolone sensitivity. Our findings indicate that AMR-related genes in the BigD region could produce trade-off effects between phages and drug sensitivity and thereby contribute to a potential strategy to control and prevent phage-resistant variants in phage therapy.

出典　DOI: 10.1016/j.virusres.2021.198596
最終責任者　Jumpei Fujiki (Corresponding Author)

伴侶動物内科学(Companion Animal Internal Medicine)

Hiroshi Ohta

Associate Professor

准教授　大田　寛

Ⅰ．筆頭または責任著者　＜First or Corresponding Author＞

1) Prognostic value of small intestinal dilatation in dogs with protein-losing enteropathy.
Ohta H, Nagata N, Yokoyama N, Osuga T, Sasaki N, Morishita K, Takiguchi M.
J. Vet. Med. Sci. 11;83(3):378-384. 2021. doi: 10.1292/jvms.20-0489.

Ⅱ．その他＜Others＞

1) Echocardiographic estimation of left ventricular-arterial coupling in dogs with myxomatous mitral valve disease.
Osuga T, Morita T, Sasaki N, Morishita K, **Ohta H**, Takiguchi M.
J. Vet. Intern. Med. 35(1):78-87. 2021. doi: 10.1111/jvim.16028.

2) PD-L1 immunohistochemistry for canine cancers and clinical benefit of anti-PD-L1 antibody in dogs with pulmonary metastatic oral malignant melanoma.
Maekawa N, Konnai S, Nishimura M, Kagawa Y, Takagi S, Hosoya K, **Ohta H**, Kim S, Okagawa T, Izumi Y, Deguchi T, Kato Y, Yamamoto S, Yamamoto K, Toda M, Nakajima C, Suzuki Y, Murata S, Ohashi K.
NPJ. Precis. Oncol. 12;5(1):10. 2021. doi: 10.1038/s41698-021-00147-6.

3) Canine Transforming Growth Factor-β Receptor 2-Ig: A Potential Candidate Biologic for Melanoma Treatment That Reverses Transforming Growth Factor-β1 Immunosuppression.
Takeuchi H, Konnai S, Maekawa N, Takagi S, **Ohta H**, Sasaki N, Kim S, Okagawa T, Suzuki Y, Murata S, Ohashi K.
Front. Vet. Sci. 14;8:656715. 2021. doi: 10.3389/fvets.2021.656715.

4) Extrahepatic biliary obstruction can interfere with hepatic fibrosis prediction using two-dimensional shear wave elastography in dogs.
Tamura M, **Ohta H**, Osuga T, Sasaki N, Morishita K, Takiguchi M.
Vet. Radiol. Ultrasound. 62(4):483-489. 2021. doi: 10.1111/vru.12969.

5) Morphometric evaluation of canine hepatocellular carcinoma using computed tomography: a promising tool for predicting malignancy.
Leela-Arporn R, **Ohta H**, Shimbo G, Sasaki N, Takiguchi M.
J. Vet. Med. Sci. 27;83(9):1459-1464. 2021. doi: 10.1292/jvms.21-0218.

6) Postoperative improvement of megaesophagus and esophageal motility in a 19-day-old puppy with gastroesophageal intussusception.
Takeuchi R, Takagi S, Hosoya K, **Ohta H**, Itami T, Okumura M.
J. Vet. Med. Sci. 16;83(11):1740-1744. 2021. doi: 10.1292/jvms.21-0384.

7) Prognostic value of left ventricular-arterial coupling estimated using echocardiography in dogs with myxomatous mitral valve disease.
Osuga T, Morita T, Sasaki N, Morishita K, **Ohta H**, Takiguchi M.
J. Vet. Intern. Med. 35(6):2607-2615. 2021. doi: 10.1111/jvim.16290.

The Journal of Veterinary Medical Science

NOTE

Internal Medicine

Prognostic value of small intestinal dilatation in dogs with protein-losing enteropathy

Hiroshi OHTA[1,3]*, Noriyuki NAGATA[1], Nozomu YOKOYAMA[2], Tatsuyuki OSUGA[2], Noboru SASAKI[1], Keitaro MORISHITA[2] and Mitsuyoshi TAKIGUCHI[1]

[1]Laboratory of Veterinary Internal Medicine, Graduate School of Veterinary Medicine, Hokkaido University, N18 W9, Sapporo, Hokkaido 060-0818, Japan

[2]Veterinary Teaching Hospital, Graduate School of Veterinary Medicine, Hokkaido University, N18 W9, Sapporo, Hokkaido 060-0818, Japan

[3]Present address: Laboratory of Veterinary Internal Medicine, Department of Small Animal Clinical Sciences, School of Veterinary Medicine, Rakuno Gakuen University, 582 Bunkyodai-Midorimachi, Ebetsu, Hokkaido 069-8501, Japan

J. Vet. Med. Sci.
83(3): 378–384, 2021
doi: 10.1292/jvms.20-0489

Received: 17 August 2020
Accepted: 26 December 2020
Advanced Epub:
12 January 2021

ABSTRACT. To date, little is known about the prognostic significance of ultrasonographic findings in dogs with protein-losing enteropathy (PLE). The aim of this retrospective study was to examine the prognostic value of ultrasonographic findings in dogs with PLE. A total of 26 dogs with PLE were included: 20 dogs with chronic enteropathy and 6 dogs with gastrointestinal lymphoma. The presence of small intestinal dilatation was associated with shorter survival time in dogs with PLE (P=0.003). The presence of hyperechoic intestinal mucosal striations was associated with longer survival time in dogs with PLE (P=0.0085). The results of the current study indicate that the presence of small intestinal dilatation might be associated with poor prognosis in dogs with PLE.

KEY WORDS: canine, intestinal dilatation, prognosis, protein-losing enteropathy, ultrasound

出典 doi: 10.1292/jvms.20-0489.

https://pubmed.ncbi.nlm.nih.gov/33431757/

最終責任者 Hiroshi Ohta (First Author and Corresponding Author)

Received: 18 June 2020 | Accepted: 18 December 2020

DOI: 10.1111/jvim.16028

STANDARD ARTICLE

Journal of Veterinary Internal Medicine ACVIM Open Access

Echocardiographic estimation of left ventricular-arterial coupling in dogs with myxomatous mitral valve disease

Tatsuyuki Osuga[1] | Tomoya Morita[2] | Noboru Sasaki[2] | Keitaro Morishita[1] | Hiroshi Ohta[1] | Mitsuyoshi Takiguchi[2]

[1]Veterinary Teaching Hospital, Graduate School of Veterinary Medicine, Hokkaido University, Sapporo, Hokkaido, Japan

[2]Laboratory of Veterinary Internal Medicine, Department of Veterinary Clinical Sciences, Graduate School of Veterinary Medicine, Hokkaido University, Sapporo, Hokkaido, Japan

Correspondence
Mitsuyoshi Takiguchi, Laboratory of Veterinary Internal Medicine, Department of Veterinary Clinical Sciences, Graduate School of Veterinary Medicine, Hokkaido University, Sapporo, Hokkaido 060-0818, Japan.
Email: mtaki@vetmed.hokudai.ac.jp

Funding Information
Japan Society for the Promotion of Science, Grant/Award Number: 19K19770; Grant-in-Aid for Scientific Research from the Ministry of Education, Culture, Sports, Science and Technology

Abstract

Background: The effective arterial elastance (Ea) to left ventricular (LV) end-systolic elastance (Ees) ratio (Ea/Ees) is an index of the interaction between LV and systemic arterial systems, left ventricular-arterial coupling (VAC). The Ea is an index of total arterial load of the LV, whereas Ees is an index of LV systolic function. In humans, inappropriate VAC based on increased Ea/Ees estimated using echocardiography is associated with more advanced heart disease severity.

Hypothesis: Left ventricular-arterial coupling assessed by echocardiographic estimation of Ea/Ees is associated with disease severity in dogs with myxomatous mitral valve disease (MMVD).

Animals: Ninety MMVD dogs and 61 healthy dogs.

Methods: Prospective cross-sectional study. The MMVD dogs were classified into stages B1, B2, or C according to American College of Veterinary Internal Medicine guidelines. Effective arterial elastance was echocardiographically estimated using the formula: mean blood pressure/(forward stroke volume/body weight). End-systolic elastance was echocardiographically estimated using the formula: mean blood pressure/(LV end-systolic volume/body weight). The ratio Ea/Ees was calculated.

Results: The ratio Ea/Ees was higher in stage B2 dogs than in healthy dogs and dogs stage B1 (both $P < .0001$), and higher in stage C dogs than in healthy dogs and dogs in the other 2 stages (healthy vs C and B1 vs C, $P < .0001$; B2 vs C, $P = .0005$). Multivariable logistic regression analysis showed that Ea/Ees and the peak velocity of early diastolic transmitral flow to isovolumic relaxation time ratio were independent predictors of stage C among echocardiographic indices in MMVD dogs.

Conclusions and Clinical Importance: Inappropriate VAC assessed by echocardiographically estimated Ea/Ees is associated with advanced disease severity in dogs with MMVD.

KEYWORDS
dogs, Ea/Ees, elastance, heart failure, mitral regurgitation

出典　doi: 10.1111/jvim.16028.
https://www.ncbi.nlm.nih.gov/pmc/articles/PMC7848320/

最終責任者　Mitsuyoshi Takiguchi (Corresponding Author)

npj | Precision Oncology

www.nature.com/npjprecisiononcology

ARTICLE OPEN

Check for updates

PD-L1 immunohistochemistry for canine cancers and clinical benefit of anti-PD-L1 antibody in dogs with pulmonary metastatic oral malignant melanoma

Naoya Maekawa[1], Satoru Konnai[1,2✉], Maki Nishimura[3], Yumiko Kagawa[3], Satoshi Takagi[4,5], Kenji Hosoya[4], Hiroshi Ohta[4], Sangho Kim[4], Tomohiro Okagawa[1], Yusuke Izumi[4], Tatsuya Deguchi[4], Yukinari Kato[6,7], Satoshi Yamamoto[1,8], Keiichi Yamamoto[1,8], Mikihiro Toda[1,8], Chie Nakajima[1,9], Yasuhiko Suzuki[1,9,10], Shiro Murata[1,2] and Kazuhiko Ohashi[1,2]

Immunotherapy targeting programmed cell death 1 (PD-1) and PD-ligand 1 (PD-L1) represents promising treatments for human cancers. Our previous studies demonstrated PD-L1 overexpression in some canine cancers, and suggested the therapeutic potential of a canine chimeric anti-PD-L1 monoclonal antibody (c4G12). However, such evidence is scarce, limiting the clinical application in dogs. In the present report, canine PD-L1 expression was assessed in various cancer types, using a new anti-PD-L1 mAb, 6C11-3A11, and the safety and efficacy of c4G12 were explored in 29 dogs with pulmonary metastatic oral malignant melanoma (OMM). PD-L1 expression was detected in most canine malignant cancers including OMM, and survival was significantly longer in the c4G12 treatment group (median 143 days) when compared to a historical control group ($n = 15$, median 54 days). In dogs with measurable disease ($n = 13$), one dog (7.7%) experienced a complete response. Treatment-related adverse events of any grade were observed in 15 dogs (51.7%). Here we show that PD-L1 is a promising target for cancer immunotherapy in dogs, and dogs could be a useful large animal model for human cancer research.

npj Precision Oncology (2021)5:10; https://doi.org/10.1038/s41698-021-00147-6

出典　doi: 10.1038/s41698-021-00147-6.
https://www.ncbi.nlm.nih.gov/pmc/articles/PMC7881100/

最終責任者　Satoru Konnai (Corresponding Author)

frontiers in Veterinary Science

ORIGINAL RESEARCH
published: 14 June 2021
doi: 10.3389/fvets.2021.656715

Canine Transforming Growth Factor-β Receptor 2-Ig: A Potential Candidate Biologic for Melanoma Treatment That Reverses Transforming Growth Factor-β1 Immunosuppression

Hiroto Takeuchi[1], Satoru Konnai[1,2], Naoya Maekawa[2], Satoshi Takagi[2,4], Hiroshi Ohta[2], Noboru Sasaki[2], Sangho Kim[3], Tomohiro Okagawa[2], Yasuhiko Suzuki[2,3,5], Shiro Murata[1,2] and Kazuhiko Ohashi[1,2]*

[1] Department of Disease Control, Faculty of Veterinary Medicine, Hokkaido University, Sapporo, Japan, [2] Department of Advanced Pharmaceutics, Faculty of Veterinary Medicine, Hokkaido University, Sapporo, Japan, [3] Department of Clinical Sciences, Faculty of Veterinary Medicine, Hokkaido University, Sapporo, Japan, [4] Department of Veterinary Surgery, School of Veterinary Medicine, Azabu University, Sagamihara, Japan, [5] Research Center for Zoonosis Control, Hokkaido University, Sapporo, Japan, [6] Global Station for Zoonosis Control, Global Institution for Collaborative Research and Education, Hokkaido University, Sapporo, Japan

OPEN ACCESS

Edited by:
Chiara Brachelente,
University of Perugia, Italy

Reviewed by:
Naoki Mizuno,
Kagoshima University, Japan
Karen M. Plain,
The University of Sydney, Australia

***Correspondence:**
Satoru Konnai
konnai@vetmed.hokudai.ac.jp

Specialty section:
This article was submitted to Comparative and Clinical Medicine, a section of the journal Frontiers in Veterinary Science

Received: 21 January 2021
Accepted: 21 May 2021
Published: 14 June 2021

Citation:
Takeuchi H, Konnai S, Maekawa N, Takagi S, Ohta H, Sasaki N, Kim S, Okagawa T, Suzuki Y, Murata S and Ohashi K (2021) Canine Transforming Growth Factor-β Receptor 2-Ig: A Potential Candidate Biologic for Melanoma Treatment That Reverses Transforming Growth Factor-β1 Immunosuppression. Front. Vet. Sci. 8:656715. doi: 10.3389/fvets.2021.656715

Cancer cells can evade host immune systems *via* multiple mechanisms. Transforming growth factor beta 1 (TGF-β1) is an immunosuppressive cytokine that induces regulatory T cell (Tregs) differentiation and is involved in immune evasion mechanisms in cancer. The inhibition of the TGF-β1 signaling pathway can suppress cancer progression and metastasis through the modulation of anticancer immune responses. However, to best of our knowledge, no implementation of treatments targeting TGF-β1 has been reported in dog cancers. This study aimed to examine whether TGF-β1 is upregulated in canine cancers. We measured TGF-β1 concentrations in culture supernatants of canine melanoma cell lines and in serum samples from dogs with oral malignant melanoma. TGF-β1 production was observed in several cell lines, and serum TGF-β1 levels were elevated in dogs with oral malignant melanoma. Interestingly, the addition of recombinant TGF-β1 to canine peripheral blood mononuclear cell cultures decreased Th1 cytokine production and increased differentiation of CD4+CD25+Foxp3+ lymphocytes, suggesting that TGF-β1 is immunosuppressive in canine immune systems. We developed a decoy receptor for TGF-β, namely TGF-βRII-Ig, by identifying an open reading frame of the canine TGFBR2 gene. TGF-βRII-Ig was prepared as a recombinant fusion protein of the extracellular region of canine TGF-βRII and the Fc region of canine IgG-B. As expected, TGF-βRII-Ig bound to TGF-β1. In the presence of TGF-β1, the treatment with TGF-βRII-Ig increased Th1 cytokine production and decreased the differentiation of CD4+CD25+Foxp3+ lymphocytes. Our results suggest that TGF-βRII-Ig competitively inhibits the immunosuppressive effects of TGF-β1 and thereby activates immune responses. This study demonstrated the potential of TGF-βRII-Ig as a novel biologic for canine melanoma.

Keywords: canine, melanoma, immunosuppression, TGF-β1, biologic, cancer immunotherapy

出典　doi: 10.3389/fvets.2021.656715.
https://www.ncbi.nlm.nih.gov/pmc/articles/PMC8236594/

最終責任者　Satoru Konnai (Corresponding Author)

Received: 7 June 2020 | Revised: 25 December 2020 | Accepted: 9 February 2021

DOI: 10.1111/vru.12969

ORIGINAL INVESTIGATION

WILEY

Extrahepatic biliary obstruction can interfere with hepatic fibrosis prediction using two-dimensional shear wave elastography in dogs

Masahiro Tamura[1] | Hiroshi Ohta[2] | Tatsuyuki Osuga[1] | Noboru Sasaki[2] | Keitaro Morishita[1] | Mitsuyoshi Takiguchi[2]

[1] Veterinary Teaching Hospital, Graduate school of Veterinary Medicine, Hokkaido University, Sapporo, Hokkaido, Japan

[2] Laboratory of Veterinary Internal Medicine, Department of Veterinary Clinical Sciences, Graduate School of Veterinary Medicine, Hokkaido University, Hokkaido, Japan

Correspondence
Mitsuyoshi Takiguchi, Laboratory of Veterinary Internal Medicine, Department of Veterinary Clinical Sciences, Graduate School of Veterinary Medicine, Hokkaido University, N18W9, Sapporo, Hokkaido 060-0818, Japan.
Email: mtaki@vetmed.hokudai.ac.jp

Abstract

Two-dimensional shear wave elastography (2D-SWE) can be used to quantitatively evaluate the elastic modulus of the liver as shear wave velocity (SWV), which can non-invasively predict clinically relevant hepatic fibrosis in both dogs and humans. However, extrahepatic biliary obstruction (EHBO), regardless of the presence of clinically relevant hepatic fibrosis, can influence SWVs in humans and thus may interfere with hepatic fibrosis prediction using 2D-SWE in dogs. The aim of this prospective, observational, and one-group pretest–posttest study is to investigate whether SWV measured by 2D-SWE displays a difference between dogs with and without EHBO. A total of 20 dogs were included (7 with EHBO and 13 with gallbladder pathology but no EHBO) that underwent preoperative SWV measurement using 2D-SWE. In all dogs, stages of hepatic fibrosis were evaluated histopathologically using a scoring scheme. In addition, postoperative SWVs in dogs with EHBO relieved via laparotomy were also evaluated. The median (range) SWVs in the dogs with and without EHBO were 1.91 (1.81–2.54) m/s and 1.57 (1.37–1.64) m/s, respectively. Although there was no significant difference in the histopathological hepatic fibrosis stages between the dogs with and without EHBO, the preoperative SWVs in the dogs with EHBO were significantly higher than in dogs without EHBO ($P = .0004$), and SWVs were found to decrease significantly after surgery ($P = .0097$). This study demonstrates that EHBO can increase the SWV of dogs without clinically relevant hepatic fibrosis and can interfere with the prediction of noninvasive hepatic fibrosis using 2D-SWE.

KEYWORDS
acoustic radiation force impulse, canine, icterus, jaundice, viscosity

出典　doi: 10.1111/vru.12969.
https://pubmed.ncbi.nlm.nih.gov/33855776/

最終責任者　Mitsuyoshi Takiguchi (Corresponding Author)

The Journal of Veterinary Medical Science

FULL PAPER
Internal Medicine

Morphometric evaluation of canine hepatocellular carcinoma using computed tomography: a promising tool for predicting malignancy

Rommaneeya LEELA-ARPORN[1,2], Hiroshi OHTA[2,3], Genya SHIMBO[4], Noboru SASAKI[2] and Mitsuyoshi TAKIGUCHI[2]*

[1]Faculty of Veterinary Medicine and Applied Zoology, HRH Princess Chulabhorn College of Medical Science, Chulabhorn Royal Academy, Lak Si, Bangkok 10210, Thailand
[2]Laboratory of Veterinary Internal Medicine, Department of Veterinary Clinical Sciences, Graduate School of Veterinary Medicine, Hokkaido University, Sapporo, Hokkaido 060-0818, Japan
[3]Laboratory of Veterinary Internal Medicine, Department of Small Animal Clinical Sciences, School of Veterinary Medicine, Rakuno Gakuen University, Ebetsu, Hokkaido 069-8501, Japan
[4]Veterinary Teaching Hospital, Graduate School of Veterinary Medicine, Hokkaido University, Sapporo, Hokkaido 060-0818, Japan

ABSTRACT. The size of canine focal liver lesions (FLLs) is known to be one of the predicting criteria for malignancy. However, there are discrepancies for the measurement of maximum lesion size, resulting in contradicting results among studies and incidences of false positive outcomes. Thus far, the morphometric changes of FLLs for distinguishing malignancy from benignancy remains undocumented. This study aimed to investigate morphometric characteristics of FLLs using computed tomography (CT). CT images of 40 dogs with histopathological confirmation of 49 liver lesions, including 39 hepatocellular carcinomas and 10 nodular hyperplasias were retrospectively reviewed. The morphometric parameters including size (long and short axis diameters measured on transverse image), shape (measured by long to short axis (L/S) ratio), volume, and surface appearance of a liver lesion were evaluated using univariate and stepwise multivariate analyses, respectively. The results of univariate analysis showed that long and short axis diameters, L/S ratio, volume, and surface appearance of a lesion were significantly different between hepatocellular carcinomas and nodular hyperplasias. Multivariate analysis revealed that short axis diameter (>3.30 cm; odds ratio (OR): 36.1, 95% confidence interval (CI): 3.36–387.05, P=0.0031) and L/S ratio (>1.23; OR: 18.1, 95% CI: 1.61–205.12, P=0.0191) were independent predictors of malignancy, with the area under the curve of 0.9154. These results suggest that the combination of short axis diameter and L/S ratio is a promising tool for predicting liver malignancy with outstanding discriminating ability.

KEY WORDS: differentiation, dog, hepatic tumor, morphometry

J. Vet. Med. Sci.
83(9): 1459–1464, 2021
doi: 10.1292/jvms.21-0218

Received: 9 April 2021
Accepted: 21 June 2021
Advanced Epub:
6 July 2021

出典　doi: 10.1292/jvms.21-0218.
https://pubmed.ncbi.nlm.nih.gov/34234070/

最終責任者　Mitsuyoshi Takiguchi (Corresponding Author)

The Journal of Veterinary Medical Science

NOTE

Surgery

Postoperative improvement of megaesophagus and esophageal motility in a 19-day-old puppy with gastroesophageal intussusception

Ryo TAKEUCHI[1)#*], Satoshi TAKAGI[1)#], Kenji HOSOYA[2)], Hiroshi OHTA[3)], Takaharu ITAMI[1)] and Masahiro OKUMURA[2)]

[1)]Veterinary Teaching Hospital, Graduate School of Veterinary Medicine, Hokkaido University, Sapporo, Hokkaido 060-0018, Japan

[2)]Laboratory of Veterinary Surgery, Department of Veterinary Clinical Sciences, Graduate School of Veterinary Medicine, Hokkaido University, Sapporo, Hokkaido 060-0818, Japan

[3)]Laboratory of Veterinary Internal Medicine, Department of Veterinary Clinical Sciences, Graduate School of Veterinary Medicine, Hokkaido University, Sapporo, Hokkaido 060-0818, Japan

J. Vet. Med. Sci.
83(11): 1740–1744, 2021
doi: 10.1292/jvms.21-0384

Received: 6 July 2021
Accepted: 11 September 2021
Advanced Epub:
21 September 2021

ABSTRACT. Canine gastroesophageal intussusception (GEI) is a rare and life-threatening condition that requires prompt diagnosis and treatment. A 19-day-old Siberian Husky with a 4-day history of regurgitation was diagnosed with GEI based on the findings of computed tomography (CT) performed without anesthesia. Endoscopic reduction of intussusception was impossible; thus, surgical reduction by traction of the duodenum was performed. CT revealed improvement of megaesophagus 82 days postoperatively. Eleven months postoperatively, fluoroscopy showed recovery to nearly normal esophageal motility. Two years postoperatively, no clinical signs were reported. CT is useful to diagnose GEI in neonate puppies with poor abdominal fat and to assess the gastric edema and the anatomical association of stomach with other organs. Fluoroscopy is helpful for evaluating postoperative esophageal motility.

KEY WORDS: canine, computed tomography, fluoroscopy, gastroesophageal intussusception, megaesophagus

出典　doi: 10.1292/jvms.21-0384.
https://pubmed.ncbi.nlm.nih.gov/34544935/

最終責任者　Ryo Takeuchi (Corresponding Author)

Received: 23 March 2021 | Accepted: 12 October 2021
DOI: 10.1111/jvim.16290

STANDARD ARTICLE

Journal of Veterinary Internal Medicine Open Access
ACVIM American College of Veterinary Internal Medicine

Prognostic value of left ventricular-arterial coupling estimated using echocardiography in dogs with myxomatous mitral valve disease

Tatsuyuki Osuga[1] | Tomoya Morita[2] | Noboru Sasaki[2] | Keitaro Morishita[1] | Hiroshi Ohta[1] | Mitsuyoshi Takiguchi[2]

[1]Veterinary Teaching Hospital, Graduate School of Veterinary Medicine, Hokkaido University, Sapporo, Hokkaido, Japan

[2]Laboratory of Veterinary Internal Medicine, Department of Clinical Sciences, Graduate School of Veterinary Medicine, Hokkaido University, Sapporo, Hokkaido, Japan

Correspondence
Mitsuyoshi Takiguchi, Laboratory of Veterinary Internal Medicine, Department of Clinical Sciences, Graduate School of Veterinary Medicine, Hokkaido University, Sapporo, Hokkaido 060-0818, Japan.
Email: mtaki@vetmed.hokudai.ac.jp

Funding Information
Japan Society for the Promotion of Science, Grant/Award Number: 19K15970; Ministry of Education, Culture, Sports, Science and Technology

Abstract

Background: The interaction between the left ventricle (LV) and systemic arterial systems, known as left ventricular-arterial coupling (VAC), has been evaluated based on the effective arterial elastance (Ea) to LV end-systolic elastance (Ees) ratio (Ea/Ees). The Ea reflects the total arterial load of LV, whereas Ees reflects the LV systolic function. A recent study found that inappropriate VAC based on increased Ea/Ees estimated by echocardiography is associated with advanced disease severity in dogs with myxomatous mitral valve disease (MMVD).

Hypothesis: Inappropriate VAC assessed by echocardiographic estimation of Ea/Ees is associated with a worse prognosis in dogs with MMVD.

Animals: Eighty-nine dogs with MMVD.

Methods: Prospective cohort study. Dogs underwent echocardiographic examinations at enrollment. The Ea was estimated using the formula: mean blood pressure/(forward stroke volume/body weight). The Ees was estimated using the formula: mean blood pressure/(LV end-systolic volume/body weight). The Ea/Ees was calculated.

Results: By end of study, 22 dogs died of cardiac-related causes with 67 dogs censored. Dogs with increased Ea/Ees (Ea/Ees >0.34; median survival time, 527 days; 95% confidence interval [CI], 322 days-not determinable) had a shorter survival time ($P < .0001$) than those without increased Ea/Ees (Ea/Ees ≤0.34; median survival time, >1112 days; 95% CI, not determinable). Multivariate Cox proportional hazard analysis showed that Ea/Ees, body weight, peak systolic mitral annular velocity, and the peak early diastolic transmitral velocity-to-peak early diastolic mitral annular velocity ratio were independent predictors of cardiac-related death among echocardiographic indices.

Conclusions and Clinical Importance: Inappropriate VAC assessed based on echocardiographically-estimated Ea/Ees is associated with a worse prognosis in dogs with MMVD.

KEYWORDS
canine, Ea/Ees, elastance, mitral regurgitation, survival time

出典　doi: 10.1111/jvim.16290.
https://pubmed.ncbi.nlm.nih.gov/34741477/

最終責任者　Mitsuyoshi Takiguchi (Corresponding Author)

獣医麻酔学（Veterinary Anesthesiology）

Tadashi SANO

Associate Professor

准教授　佐野　忠士

Ⅰ．筆頭または責任著者　＜First or Corresponding Author＞

1) The Chalactalistcs of Inhalational Anesthesia for Cats
Tadashi SANO
Research Aspects in Agriculture and Veterinary Science Vol. 1, 15 July 2021, Page 89-93.
https://doi.org/10.9734/bpi/raavs/v1/2787FPublished: 2021-07-15.

Ⅱ．その他＜Others＞

1) Effects of sevoflurane, propofol or alfaxalone on neuromuscular blockade produced by a single intravenous bolus of rocuronium in dogs.
Chen IY, Tamogi H, Wei Y, Kato K, Itami T, **Sano T**, Yamashita K.
Vet. Anaesth. Analg. Online ahead of print. 2021.
doi: 10.1016/j.vaa.2021.10.002.

2) The anesthetic effects of intramuscular alfaxalone in dogs premedicated with low-dose medetomidine and/or butorphanol.
Kato K, Itami T, Nomoto K, Endo Y, Tamura J, Oyama N, **Sano T**, Yamashita K.
J. Vet. Med. Sci. 83:53-61. 2021. doi: 10.1292/jvms.20-0330.



The Chalactalistcs of Inhalational Anesthesia for Cats

Tadashi Sano

Research Aspects in Agriculture and Veterinary Science Vol. 1, 15 July 2021, Page 89-93
https://doi.org/10.9734/bpi/raavs/v1/2787F
Published: 2021-07-15

View Article | Cite | Statistics | Share

Abstract

Objective: While clinical use of sevoflurane has been increasing in veterinary medicine, this anaesthetic can cause dose-dependent hypotension, hypoventilation, impaired cardiac contractility, and hypothermia. Because of these side effects, sevoflurane must be carefully titrated and vigilantly monitored to avoid excessive anaesthetic depth. One of the anaesthetic depth evaluation using a minimum alveolar concentration (MAC) has been defined as "produces immobility in 50% of animals exposed to noxious stimulus." Limited information regarding the MAC of sevoflurane required for blunting adrenergic responses (MAC-BAR) in cats currently exists. Therefore, this study was designed to compare the MAC and MAC-BAR of sevoflurane required to prevent autonomic responses and purposeful movements in cats.

Methods: Six adult healthy domestic short haired cats (1year old, 3 males and 3 females) were anaesthetized with sevoflurane on two occasions with a minimum 14-day washout period to determine sevoflurane MAC and MACBAR.

Results: The difference between sevoflurane MAC (2.92 ±0.47%) and MAC-BAR (3.24 ± 0.41%) was not statistically significant.

Conclusions and Clinical Relevance: These results suggested that the detrimental cardiovascular side effects such as hypotension and impaired cardiac contractility can easily occur in sevoflurane-anaesthetized cats.

Keywords: Anaesthetic depth; cat; inhalation; minimum alveolar concentration; sevoflurane

出典 https://doi.org/10.9734/bpi/raavs/v1/2787F

最終責任者 Tadashi SANO (First Author)

ARTICLE IN PRESS
Veterinary Anaesthesia and Analgesia xxxx, xxx, xxx

RESEARCH PAPER

Effects of sevoflurane, propofol or alfaxalone on neuromuscular blockade produced by a single intravenous bolus of rocuronium in dogs

I-Ying Chen, Haruka Tamogi, Yixian Wei, Keiko Kato, Takaharu Itami, Tadashi Sano & Kazuto Yamashita
Department of Small Animal Clinical Sciences, School of Veterinary Medicine, Rakuno Gakuen University, Ebetsu, Hokkaido, Japan

Corresponding. Kazuto Yamashita, Department of Small Animal Clinical Sciences, School of Veterinary Medicine, Rakuno Gakuen University, 582, Bunkyodai-Midorimachi, Ebetsu, Hokkaido 069-8501, Japan. E-mail: yamasita@rakuno.ac.jp

出典 doi: 10.1016/j.vaa.2021.10.002.
https://www.vaajournal.org/article/S1467-2987(21)00294-4/pdf
最終責任者 Kazuto Yamashita (Corresponding Author)

The Journal of Veterinary Medical Science

NOTE

Surgery

Comparison of the anesthetic effects between 5 mg/kg of alfaxalone and 10 mg/kg of propofol administered intravenously in cats

Jun TAMURA[1,2)]*, Norihiko OYAMA[1,2)], Sho FUKUI[1)] and Kazuto YAMASHITA[1)]

[1)]Departments of Small Animal Clinical Sciences, Rakuno Gakuen University, Ebetsu, Hokkaido 069-8501, Japan
[2)]Veterinary Teaching Hospital, Graduate School of Veterinary Medicine, Hokkaido University, Sapporo, Hokkaido 060-0018, Japan

J. Vet. Med. Sci.
83(1): 73–77, 2021
doi: 10.1292/jvms.20-0407

Received: 2 July 2020
Accepted: 4 November 2020
Advanced Epub:
8 January 2021

ABSTRACT. To compare the anesthetic effects after intravenous administration of alfaxalone or propofol without premedication, either alfaxalone (5 mg/kg) or propofol (10 mg/kg) was administered intravenously over 120 sec in 6 cats. Each cat received the alternate treatment at least a 7-day interval. Anesthetic effects (tolerance of intubation, behavior changes and neurodepressive score) and physiological parameters were evaluated. Both treatments produced a rapid loss of consciousness, no apnea, and physiological parameters were maintained within clinically acceptable ranges apart from transient hypoxemia. The degree of hypoxemia was greater after the propofol treatment compared with the alfaxalone treatment. During the recovery period, more adverse events (ataxia, muscular tremors) were observed after the alfaxalone treatment compared with the propofol treatment.

KEY WORDS: alfaxalone, anesthetic induction, feline, propofol

*Correspondence to: Tamura, J.: j-tamura@vetmed.hokudai.ac.jp

©2021 The Japanese Society of Veterinary Science

This is an open-access article distributed under the terms of the Creative Commons Attribution Non-Commercial No Derivatives (by-nc-nd) License. (CC-BY-NC-ND 4.0: https://creativecommons.org/licenses/by-nc-nd/4.0/)

出典　doi: 10.1292/jvms.20-0407.
https://www.ncbi.nlm.nih.gov/pmc/articles/PMC7870395/pdf/jvms-83-073.pdf

最終責任者　Jun Tamura (First Author and Corresponding Author)

The Journal of Veterinary Medical Science

FULL PAPER
Surgery

The anesthetic effects of intramuscular alfaxalone in dogs premedicated with low-dose medetomidine and/or butorphanol

Keiko KATO[1], Takaharu ITAMI[1]*, Ken NOMOTO[1], Yusuke ENDO[1], Jun TAMURA[1], Norihiko OYAMA[1], Tadashi SANO[2] and Kazuto YAMASHITA[1]

[1]Department of Small Animal Clinical Sciences, School of Veterinary Medicine, Rakuno Gakuen University, Ebetsu, Hokkaido 069-8501, Japan
[2]Department of Veterinary Nursing Sciences, School of Veterinary Medicine, Rakuno Gakuen University, Ebetsu, Hokkaido 069-8501, Japan

ABSTRACT. We aimed to evaluate the induction, anesthesia, and cardiorespiratory effects of intramuscular (IM) anesthetic protocol with alfaxalone following premedication with low-dose medetomidine, butorphanol, or a combination of both (medetomidine–butorphanol) in dogs. Six healthy beagles were administered 1, 2.5, or 5 mg/kg alfaxalone IM following premedication with low-dose medetomidine (5 µg/kg; MA-IM), butorphanol (0.3 mg/kg; BA-IM), or medetomidine-butorphanol (5 µg/kg and 0.3 mg/kg, respectively; MBA-IM). Each dog received 9 treatments with minimum 7-day washout period between treatments. Dogs were allowed to breath room air during anesthetic induction. We attempted endotracheal intubation after alfaxalone administration. Alfaxalone produced a dose-dependent anesthetic effect in each anesthetic protocol. Intubation was achieved in 4 out of 6 dogs that received MA-IM and BA-IM with 2.5 mg/kg alfaxalone and in all dogs that received MBA-IM with 1, 2.5, and 5 mg/kg alfaxalone. The median durations [minimum–maximum] of accepting intubation were 79 [0–89], 97 [84–120], and 117 [84–217] min, respectively. Hypotension (mean arterial blood pressure <60 mmHg) did not develop, but bradycardia (heart rate <60 beats/min) was observed in all dogs that received the MA-IM and MBA-IM protocols. Severe hypoxemia (percutaneous arterial oxygen saturation <90%) developed in 2 dogs that received MBA-IM with 5 mg/kg alfaxalone. We consider that the MA-IM and BA-IM protocols with ≥2.5 mg/kg alfaxalone and the MBA-IM protocol with 1–2.5 mg/kg alfaxalone could provide clinically useful and effective anesthesia without causing severe cardiorespiratory depression in healthy dogs.

KEY WORDS: alfaxalone, butorphanol, dog, intramuscular anesthesia, medetomidine

J. Vet. Med. Sci.
83(1): 53–61, 2021
doi: 10.1292/jvms.20-0330

Received: 1 June 2020
Accepted: 28 October 2020
Advanced Epub:
13 November 2020

*Correspondence to: Itami, T.: t-itami@rakuno.ac.jp
(Supplementary material: refer to PMC https://www.ncbi.nlm.nih.gov/pmc/journals/2350/)

©2021 The Japanese Society of Veterinary Science

This is an open-access article distributed under the terms of the Creative Commons Attribution Non-Commercial No Derivatives (by-nc-nd) License. (CC-BY-NC-ND 4.0: https://creativecommons.org/licenses/by-nc-nd/4.0/)

出典　doi: 10.1292/jvms.20-0330.
https://www.ncbi.nlm.nih.gov/pmc/articles/PMC7870407/pdf/jvms-83-053.pdf

最終責任者　Takaharu Itami (Corresponding Author)

獣医臨床病理学（Veterinary Clinicopathology）

Haruyuki Hirata

Associate Professor

准教授　平田　晴之

Ⅰ．筆頭または責任著者　＜First or Corresponding Author＞

1）*Clistobothrium* sp. (Cestoda: Tetraphylidea) in oarfish (*Regalecus russelii*) stranded on the coast of Akita Prefecture, Japan.
Hirata H., Mibe Y., Ono K., Shizuno S., Suzuki K., Asakawa M.
J. Vet. Med. Sci. 83(10): 1590-1592. 2021. doi: 10.1292/jvms.21-0317.

Ⅱ．その他＜Others＞

The Journal of Veterinary Medical Science

NOTE

Wildlife Science

Clistobothrium sp. (Cestoda: Tetraphyllidea) in oarfish (*Regalecus russelii*) stranded on the coast of Akita Prefecture, Japan

Haruyuki HIRATA[1)], Yuki MIBE[1)], Koji ONO[2)], Satsuki SHIZUNO[2)], Kazuyuki SUZUKI[1)] and Mitsuhiko ASAKAWA[1)]*

[1)]School of Veterinary Medicine, Rakuno Gakuen University, Hokkaido 069-8501, Japan
[2)]Oga Aquarium GAO, Akita 010-0673, Japan

J. Vet. Med. Sci.
83(10): 1590–1592, 2021
doi: 10.1292/jvms.21-0317

Received: 3 June 2021
Accepted: 17 August 2021
Advanced Epub:
2 September 2021

ABSTRACT. Oarfish (*Regalecus russelii* Cuvier) are mesopelagic fish with little known about their life history. Oarfish live in deep water, making it difficult for researchers to collect specimens; thus, records of their parasitic helminths are limited. Two plerocercoids were found for the first time in an oarfish stranded on the coast of Akita Prefecture, Japan. These plerocercoids were identified as *Clistobothrium* sp. RR-1 using morphological and molecular analyses. It was revealed that oarfish represent one of the intermediate hosts of the genus *Clistobothrium*, and large sharks are the definitive hosts for these parasites.

KEY WORDS: deep-sea fish, first record, oarfish, phylogenetic analysis, plerocercoid

出典　doi: 10.1292/jvms.21-0317
https://www.jstage.jst.go.jp/article/jvms/83/10/83_21-0317/_article
最終責任者　Mitsuhiko Asakawa (Corresponding Author)

ハードヘルス学（Veterinary Herd Health）

Rika Fukumori

Associate professor

准教授　福森　理加

Ⅰ．筆頭または責任著者　＜First or Corresponding Author＞

1）Performance evaluation of a newly designed on-farm blood testing system for determining blood non-esterified fatty acid and β-hydroxybutyrate.
Fukumori R, Taguchi T, Oetzel GR, Oikawa S.
Research in Veterinary Science 135: 247-252. 2021.
doi: 10.1016/j.rvsc.2020.09.011

2）Evaluation of relationship between ruminal pH and the proportion of de novo fatty acids in milk.
Fukumori R, Weina S, Oikawa S, Oba M.
JDS Communications 2: 123-126. 2021. doi: 10.3168/jdsc.2020-0042

3) The effect of sodium butyrate supplementation on ruminal and fecal pH and serum lipopolysaccharide-binding protein after ruminal acidosis challenge in non-lactating cows.
Fukumori R, Ikeno R, Izumi K, Doi K, Otsuka M, Suzuki K, Oikawa S.
Animal Sciece Journal 92:e13673. 2021. doi: 10.1111/asj.13673

Ⅱ．その他＜Others＞

1) The effects of glutathione ethyl ester in in vitro maturation on the developmental ability of oocytes derived from cattle with liver abnormalities.
Sarentonglaga B, Ashibe S, Kato T, Atchalalt K, **Fukumori R,** Nagao Y.
Theriogenology 170: 85-90. 2021. doi: 10.15406/jmen.2019.07.00256

Research in Veterinary Science 135 (2021) 247–252

Contents lists available at ScienceDirect

Research in Veterinary Science

journal homepage: www.elsevier.com/locate/rvsc

Performance evaluation of a newly designed on-farm blood testing system for determining blood non-esterified fatty acid and β-hydroxybutyrate concentrations in dairy cows

Rika Fukumori [a], Takayuki Taguchi [b], Garrett R. Oetzel [c], Shin Oikawa [a,*]

[a] Department of Veterinary Herd Health, School of Veterinary Medicine, Rakuno Gakuen University, 582 Bunkyodai-Midorimachi, Ebetsu, Hokkaido 069-8501, Japan
[b] I. B. Co., Ltd., 2-11-4 Ginza, Chuo-ku, Tokyo 104-006, Japan
[c] Department of Medical Sciences, School of Veterinary Medicine, University of Wisconsin, 2015 Linden Drive, Madison, WI 53706, USA

ARTICLE INFO

Keywords:
Dairy cow
Non-esterified fatty acids
β-Hydroxybutyrate
On-farm blood testing

ABSTRACT

The objective of this study was to evaluate a newly designed on-farm blood testing system (OFBTS) for monitoring blood concentrations of non-esterified fatty acids (NEFA) and β-hydroxybutyrate (BHBA) in dairy cows. Blood samples from 230 Holstein dairy cows between −86 and 343 days in milk were collected. A drop of whole blood was used to determine NEFA and BHBA using the OFBTS. Plasma from the remaining blood was used to determine both analytes using a commercial kit (gold standard). In the repeatability of the OFBTS, the intra-assay CV for NEFA and BHBA were 1.3% and 4.5%, and the inter-assay CV were 1.8% and 2.9%, respectively. The slope and coefficient of determination of OFBTS analysis of NEFA compared to the gold standard were 0.92 and 0.94. Those for BHBA were 0.94 and 0.98. Mean of the difference between the gold standard laboratory assays and OFBTS of NEFA and BHBA were 0.021 and 0.019, respectively. However, the bias became substantial for NEFA in the higher concentration ranges (>1.2 mEq/L). The sensitivity and specificity of NEFA were 93.2% and 99.4% at a cutpoint of 0.4 mEq/L, and 87.9% and 100% at 0.6 mEq/L. Those of BHBA were 86.2% and 99.0% at a cutpoint of 1.0 mM, and 94.7% and 99.5% at 1.2 mM. The reaction time for the NEFA to reach 0.6 mEq/L was 7 min. The BHBA reaction reached 1.2 mM within 2 min. In conclusion, the OFBTS has excellent performance for evaluating blood NEFA or BHBA concentrations.

1. Introduction

Crucial physiological and metabolic adaptations occur in dairy cows during the transition period from late gestation to early lactation. Most dairy cows experience negative energy balance (NEB) after calving. Ketosis, which is practically quantified as hyperketonemia (HYK), occurs when moderate to severe NEB is accompanied by impaired carbohydrate supply (Grummer, 1993). This combination leads to incomplete β-oxidation of mobilized fatty acids and the formation of ketone bodies. Excessive NEB and HYK after calving are both associated with negative health and production outcomes (Kehrli Jr. et al., 1989; Hammon et al., 2006; Ospina et al., 2010; Ospina et al., 2013). A smaller proportion of prepartum dairy cows experience NEB; however, when it does occur it is very strongly associated with negative health outcomes postpartum (Ospina et al., 2013). A recent epidemiological study (Macrae et al., 2019) reported that 12.8% of cows had high concentration of serum BHBA (≥ 0.8 mM) in the last 10 days of pregnancy. Blood ketone concentrations determined prior to calving are not highly predictive of postpartum problems (Chapinal et al., 2012; Ospina et al., 2013).

The presence and degree of NEB can be determined by measuring blood concentrations of non-esterified fatty acids (NEFA). Animal handling and diet can affect blood NEFA results (Leroy et al., 2011). Elevated blood NEFA concentrations, either before or after calving, are associated with numerous negative health outcomes. For postpartum cows, blood NEFA was more predictive of negative outcomes than blood ketones (Ospina et al., 2013).

Handheld BHBA meters have recently made it practical to conduct large-scale, on-farm testing for HYK. The performance and usefulness of handheld BHBA meters has been substantiated repeatedly (Iwersen et al., 2013; Kanz et al., 2015; Pineda and Cardoso, 2015; Süss et al., 2016). The use of handheld BHBA meters has allowed for determination of the prevalence of hyperketonemia in postpartum cows in several

* Corresponding author at: 582 Bunkyodai-Midorimachi, Ebetsu, Hokkaido 069-8501, Japan.
E-mail address: oishin@rakuno.ac.jp (S. Oikawa).

https://doi.org/10.1016/j.rvsc.2020.09.011
Received 14 April 2020; Received in revised form 27 July 2020; Accepted 14 September 2020
Available online 20 September 2020
0034-5288/© 2020 Elsevier Ltd. All rights reserved.

出典　doi:10.1016/j.rvsc.2020.09.011

最終責任者　Shin Oikawa　(Corresponding Author)

JDS Communications
2021; 2:123–126

https://doi.org/10.3168/jdsc.2020-0042
Short Communication
Animal Nutrition and Farm Systems

Evaluation of relationship between ruminal pH and the proportion of de novo fatty acids in milk

R. Fukumori,[1] W. Shi,[2] S. Oikawa,[1] and M. Oba[2]*

Graphical Abstract

Milk de novo fatty acids estimated by FTIR were related to ruminal pH and can be useful for detecting SARA

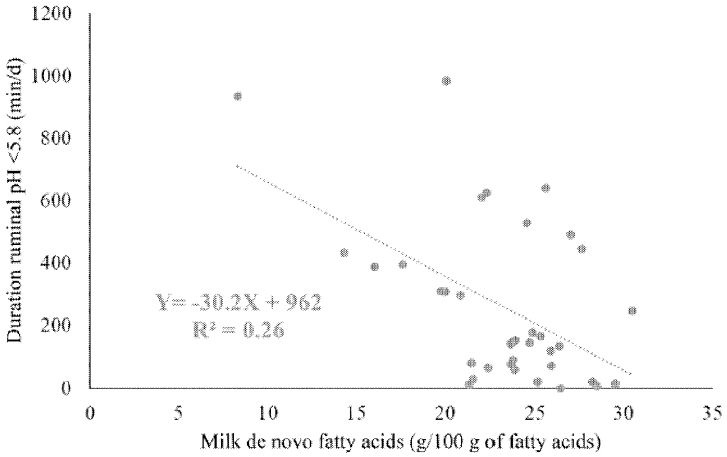

Summary

Subacute ruminal acidosis (SARA) is a serious problem in high-producing dairy cows, but its diagnosis is difficult. Recently, Fourier-transform infrared spectrometry (FTIR) was introduced to the dairy industry as a tool to estimate milk fatty acids (FA), such as de novo, mixed-origin, and preformed FA. The present study showed that milk de novo FA (g/100 g of FA) concentration was positively related to nadir and mean ruminal pH and negatively related to duration below pH 5.8. Milk fat content was not related to ruminal pH, indicating that milk de novo FA concentration is an appropriate measurement variable that relates to ruminal pH.

Highlights

- Milk de novo fatty acids (DNFA) estimated by FTIR were correlated with ruminal pH.
- Ruminal pH was correlated better with DNFA than milk fat content or yield.
- Ruminal pH was correlated better with DNFA in milk fat than with DNFA in milk.



[1]Department of Veterinary Medicine, School of Veterinary Medicine, Rakuno Gakuen University, Ebetsu, Japan 069-8501, [2]Department of Agricultural, Food and Nutritional Science, University of Alberta, Edmonton, AB, Canada T6G 2P5. *Corresponding author: moba@ualberta.ca. © 2021, The Authors. Published by Elsevier Inc. and Fass Inc. on behalf of the American Dairy Science Association®. This is an open access article under the CC BY license (http://creativecommons.org/licenses/by/4.0/). Received October 21, 2020. Accepted February 13, 2021.

出典　https: / / doi .org/ 10 .3168/ jdsc .2020 -0042

最終責任者　Masahito Oba　(Corresponding Author)

Received: 30 May 2021 | Revised: 27 September 2021 | Accepted: 22 November 2021
DOI: 10.1111/asj.13673

RESEARCH ARTICLE

Animal Science Journal WILEY

The effect of sodium butyrate supplementation on ruminal and fecal pH and serum lipopolysaccharide-binding protein after ruminal acidosis challenge in nonlactating cows

Rika Fukumori[1] | Rina Ikeno[1] | Kenichi Izumi[2] | Kazuya Doi[2] | Marina Otsuka[1] | Kazuyuki Suzuki[1] | Shin Oikawa[1]

[1]Department of Veterinary Medicine, School of Veterinary Medicine, Rakuno Gakuen University, Ebetsu, Japan

[2]Department of Sutainable Agricultrure, College of Agriculture, Food and Environment Sciences, Rakuno Gakuen University, Ebetsu, Japan

Correspondence
Shin Oikawa, Department of Veterinary Medicine, School of Veterinary Medicine, Rakuno Gakuen University, Ebetsu 069-8501, Japan.
Email: oishin@rakuno.ac.jp

Funding information
Japan Society for the Promotion of Science, Grant/Award Number: #18K14593

Abstract

The objective of this study was to evaluate effects of sodium-butyrate supplementation on gastrointestinal function and the inflammatory response to ruminal acidosis (RA) challenge in cows. Four nonlactating cows with a rumen cannula were assigned to two treatments in a crossover design. Treatments were ruminal administration of sodium-butyrate (BUT) or control (CON). Sodium-butyrate was provided as Gustor BP70 and administered at a butyrate dose of 0.04% per kg body weight. The CON premix was made by replacing sodium-butyrate with wheat bran. Experimental periods were 28 days long with 21-day washout period separating the treatments. On Day 25 of each period, corn starch was ruminally administered at 0.7% per kg body weight as RA challenge. After RA challenge, ruminal pH was lower, and endotoxin concentration was higher for cows provided with BUT than those with CON, but the increase in fecal starch and the decrease in fecal pH were attenuated by BUT. The effect of butyrate supplementation on serum lipopolysaccharide-binding protein after RA challenge was not found. From these findings, butyrate supplementation mitigated rectal acidosis by reducing the flux of fermentable carbohydrate into the large intestine. An anti-inflammatory effect of butyrate was not observed, possibly due to lower pH and higher endotoxin concentration in the rumen.

KEYWORDS
butyric acid, endotoxin, lipopolysaccharide-binding protein, ruminal acidosis

1 | INTRODUCTION

Ruminal acidosis (RA) is a metabolic disease caused by feeding with high grain diets (Krause & Oetzel, 2005). This disease decreases feed intake and milk fat, affects ruminal microflora and digestion, and can cause diarrhea, rumenitis, parakeratosis, and laminitis in cows (Nocek, 1997; Steele et al., 2009; Zhao et al., 2018). Therefore, RA is a critical issue for improvement of cow health. Penner et al. (2007) defined ruminal pH below 5.8 as subacute RA (SARA) because it is a suboptimal point of ruminal microbiome activit, and ruminal pH below 5.2 as acute RA when lactate accumulation starts in the rumen. High-starch diets often cause RA and SARA because they are rapidly fermented to decrease ruminal pH. This decreased pH alters microbial flora and increases the death of gram-negative bacteria and the concentration of endotoxin, a component of the cell wall of gram-negative bacteria (also called lipopolysaccharide, LPS), in the ruminal fluid (Khafipour et al., 2009a, 2009b). Increased luminal LPS is translocated into the blood via the mucosa was demonstrated by intrauterine infusions of LPS (Purba, Nii, et al., 2020; Purba, Ueda, et al., 2020), leading to systemic inflammation by promoting the

 © 2021 Japanese Society of Animal Science

出典　doi: 10.1111/asj.13673
最終責任者　Shin Oikawa (Corresponding Author)

Theriogenology 170 (2021) 85–90

Contents lists available at ScienceDirect

Theriogenology

journal homepage: www.theriojournal.com

The effects of glutathione ethyl ester in *in vitro* maturation on the developmental ability of oocytes derived from cattle with liver abnormalities

Borjigin Sarentonglaga [a, 1], Shiori Ashibe [a, b, 1], Taiki Kato [a], Khurchabiling Atchalalt [a, d, 2], Rika Fukumori [a, c, 2], Yoshikazu Nagao [a, b, *]

[a] University Farm, Faculty of Agriculture, Utsunomiya University, Tochigi, 321-4415, Japan
[b] Department of Animal Production Science, United Graduate School of Agricultural Science, Tokyo University of Agriculture and Technology, Fuchu, Tokyo 183-8509, Japan
[c] Department of Health and Environmental Science, School of Veterinary Medicine, Rakuno Gakuen University, Ebetsu, Hokkaido 069-8501, Japan
[d] Tokyo University of Agriculture and Technology Field Science Center, Tokyo 183-8509, Japan

ARTICLE INFO

Article history:
Received 23 September 2019
Received in revised form
1 May 2021
Accepted 2 May 2021
Available online 6 May 2021

Keywords:
Bovine
Embryo development
Liver abnormality
Glutathione ethyl ester
Oocyte

ABSTRACT

The main objectives of this study was to identify the effects of a relationship of hyper-concentration of Gamma-glutamyltransferase (γ-GTP) in follicle fluid (FF) on the levels of glutathione (GSH)/reactive oxygen species (ROS) in oocytes and subsequent embryo development in cattle with abnormal livers. Furthermore, we investigated the effect of supplementing *in vitro* maturation medium with glutathione ethyl ester (GSH-OEt) on the subsequent developmental potential of oocytes from such cattle. We used a control group of cattle (with normal livers) and a liver disorder (LD) group, in which the liver was diagnosed as being abnormal. In experiment 1, the LD group was divided to two subgroups according to the concentration of γ-GTP in FF; a low group (<50 IU/L; the low LD group), and a high group (>50 IU/L; the high LD group). Cumulus oocyte-complexes (COCs) were matured and fertilized *in vitro* and then cultured to the blastocyst stage. The levels of GSH and ROS in the matured oocytes after IVM were then assessed in each group. On day 7 after fertilization, embryo cleavage and development were assessed. We found that the rate of development to the blastocyst stage was significantly lower in the high LD group than in the control group and the low LD group. The levels of GSH in matured oocytes were significantly lower in the high LD group than in the control group and low LD group. The levels of ROS in matured oocytes was significantly higher in the high LD group than in the control group and the low LD group. In experiment 2, COCs from cattle in the high LD group were matured in m-199 supplemented with 5 mM GSH-OEt, then IVF and IVC was performed for 7 days. The GSH levels were determined in some COCs after IVM. The supplementation of media with GSH-OEt during IVM increased the levels of GSH in mature oocytes and improved the rate of blastocyst development compared with the control group. In conclusion, GSH-OEt supplementation to media during IVM can improve the developmental potential of oocytes in liver-diseased cattle with high γ-GTP concentrations in the FF by increasing intracellular GSH synthesis and scavenging ROS.

© 2021 Published by Elsevier Inc.

1. Introduction

The application of *in vitro* production techniques on bovine oocytes and embryos is now a routine practice. Recently, the main method of embryo production has shifted from the production of embryos fertilized in vivo in super-ovulated donors to the method of ovum pick-up (OPU) and *in vitro* fertilization (IVF). However, individual variations in the rates of blastocysts produced *in vitro* were reported during IVF programs involving oocytes from individual slaughtered cows [1]. Previously studies have reported that the developmental competence of matured oocytes can be affected by several factors during *in vitro* maturation (IVM) including

*Corresponding author. University Farm, Faculty of Agriculture, Utsunomiya University, Tochigi, 321-4415, Japan. Tel.: +81-285-84-1321, Fax: +81-285-84-1321.
E-mail address: ynagao@cc.utsunomiya-u.ac.jp (Y. Nagao).
[1] These authors contributed egually to this work.
[2] Present post.

https://doi.org/10.1016/j.theriogenology.2021.05.003
0093-691X/© 2021 Published by Elsevier Inc.

出典　doi: 10.1016/j.theriogenology.2021.05.003
最終責任者　Yoshikazu Nagao (Corresponding Author)

伴侶動物内科学（Companion Animal Internal Medicine）

Hiroki Yamazaki

Associate Professor

准教授　山﨑　裕毅

Ⅰ．筆頭または責任著者　＜First or Corresponding Author＞

1) Assessment of biomarkers influencing treatment success on small intestinal lymphoma in dogs.
Hiroki Yamazaki, Hiroshi Sasai, Miyuu Tanaka, Toshiyuki Tanaka, Hidetaka Nishida, Shunsuke Noguchi, Mitsuru Kuwamura, Hideo Akiyoshi
Veterinary and comparative oncology. 19(1). 123-131. 2021

2) Single-modality palliative radiotherapy versus palliative radiotherapy after chemotherapy failure for cats with nasal lymphoma
Hiroki Yamazaki, Yusuke Wada, Toshiyuki Tanaka, Shunsuke Noguchi
Veterinary Radiology & Ultrasound. 2021. in press

Ⅱ．その他＜Others＞

1) Comparing the CT and MRI findings for canine primary hepatocellular lesions.
Shohei Kurokawa, Toshiyuki Tanaka, **Hiroki Yamazaki**, Shunsuke Noguchi, Yusuke Wada, Hidetaka Nishida, Hideo Akiyoshi
The Veterinary record. e1083. 2021

2) Computed tomography may detect liver infiltration of canine diffuse hepatic lymphoma.
Toshiyuki Tanaka, **Hiroki Yamazaki**, Kazuna Ashida, Yasumasa Iimori, Keiichiro Mie, Hidetaka Nishida, Hideo Akiyoshi
Veterinary medicine and science. 7(6). 2172-2177. 2021

3) Radiotherapy-induced tumor lysis syndrome in a dog with thymoma.
Yusuke Wada, **Hiroki Yamazaki**, Miyuu Tanaka, Ayumi Kaneguchi, Toshiyuki Tanaka, Hideo Akiyoshi, Shunsuke Noguchi

The Journal of veterinary medical science. 83(8). 1290-1294. 2021

4) MRI findings, including diffusion-weighted imaging, in seven cats with nasal lymphoma and two cats with nasal adenocarcinoma.
Toshiyuki Tanaka, Kazuna Ashida, Yasumasa Iimori, **Hiroki Yamazaki**, Keiichiro Mie, Hidetaka Nishida, Hideo Akiyoshi
Journal of feline medicine and surgery. 23(4). 393-399. 2021

5) Contrast-enhanced computed tomography characterization of canine rectal neoplasms.
Toshiyuki Tanaka, Yasumasa Iimori, **Hiroki Yamazaki**, Hidetaka Nishida, Hideo Akiyoshi
Japanese Journal of Veterinary Research. 69(3), 163-173. 2021

6) Less enhancement and low apparent diffusion coefficient value on magnetic resonance imaging may be helpful to detect canine prostate adenocarcinoma in case series.
Toshiyuki Tanaka, Kazuna Ashida, Yasumasa Iimori, **Hiroki Yamazaki**, Keiichiro Mie, Hidetaka Nishida, Hideo Akiyoshi
Veterinary and comparative oncology. 18(4). 861-865. 2021

DOI: 10.1111/vco.12653

ORIGINAL ARTICLE

Veterinary and Comparative Oncology WILEY

Assessment of biomarkers influencing treatment success on small intestinal lymphoma in dogs

Hiroki Yamazaki[1,2] | Hiroshi Sasai[3] | Miyuu Tanaka[1] | Toshiyuki Tanaka[1,2] | Hidetaka Nishida[1,2] | Shunsuke Noguchi[1,4] | Mitsuru Kuwamura[5] | Hideo Akiyoshi[1,2]

[1]Veterinary Medical Center, College of Life, Environmental and Advanced Sciences, Osaka Prefecture University, Osaka, Japan

[2]Laboratory of Veterinary Surgery, Graduate School of Life and Environmental Sciences, Osaka Prefecture University, Osaka, Japan

[3]Kitasuna Animal Hospital, Kobe, Hyogo, Japan

[4]Laboratory of Veterinary Radiology, Graduate School of Life and Environmental Sciences, Osaka Prefecture University, Osaka, Japan

[5]Laboratory of Veterinary Pathology, Graduate School of Life and Environmental Sciences, Osaka Prefecture University, Osaka, Japan

Correspondence
Hiroki Yamazaki, Veterinary Medical Center, College of Life, Environmental and Advanced Sciences, Osaka Prefecture University, 1-58 Rinku-orai-kita, Izumisano, Osaka, 598-8531, Japan.
Email: hyamazaki@vet.osakafu-u.ac.jp

Abstract

This study aimed to determine a reliable therapeutic biomarker for localized small intestinal lymphoma (SIL) in dogs based on clinical and histopathological features. We retrospectively investigated 84 dogs with localized SIL, including 36 dogs receiving surgery and 48 dogs receiving chemotherapy. The dogs receiving surgery were divided into two subgroups: 18 dogs (group 1) with overall survival (OS) <120 days (median OS) and 18 dogs (group 2) with OS ≥120 days. Correspondingly, the dogs receiving chemotherapy were divided into 24 dogs (group 3) with OS <98 days (median OS) and 24 dogs (group 4) with OS ≥98 days. Clinical, haematological, histopathological and immunohistochemical analyses were comparatively evaluated among the four subgroups. There was no significant difference in OS between the surgery and chemotherapy groups. In dogs receiving surgery, the rate of Ki67-positive cells was significantly increased in group 1 compared to group 2 and showed no significant difference between groups 3 and 4. In dogs receiving chemotherapy, the rate of O6-methylguanine-DNA methyltransferase (MGMT) was significantly higher in group 3 than in group 4 and showed no significant difference between groups 1 and 2. Additionally, our data showed that OS in dogs with higher Ki67 expression might be significantly increased by chemotherapy than by surgery, that of those with higher MGMT expression might be significantly increased by surgery than by chemotherapy, and Ki67 and MGMT were independent of each other. Indices of Ki67 and MGMT are suggested therapeutic biomarkers to determine the optimal first-line treatment for localized SIL in dogs.

KEYWORDS

dogs, Ki67, MGMT, small intestinal lymphoma, therapeutic biomarker

出典　doi: 10.1111/vco.12653.
https://onlinelibrary.wiley.com/doi/epdf/10.1111/vco.12653

最終責任者　Hiroki Yamazaki (First Author and Corresponding Author)

JOURNALS Visit BVA

Vet Record



Early View
Online Version of Record before inclusion in an issue
e1083

ORIGINAL RESEARCH

Comparing the CT and MRI findings for canine primary hepatocellular lesions

Shohei Kurokawa, Toshiyuki Tanaka, Hiroki Yamazaki, Shunsuke Noguchi, Yusuke Wada, Hidetaka Nishida, Hideo Akiyoshi

First published: 08 November 2021 | https://doi.org/10.1002/vetr.1083

Read the full text > PDF TOOLS SHARE

Abstract

Background

Triple-phase CT and gadolinium ethoxybenzyl diethylenetriamine pentaacetic acid (Gd-EOB-DTPA) MRI have been used to differentiate hepatocellular carcinomas (HCCs) in dogs.

Methods

This retrospective case series aimed to compare the CT findings with MRI findings of 20 canine hepatocellular lesions, including eight poorly/moderately-differentiated HCCs, eight well-differentiated HCCs and four hyperplasias. CT data were analysed, and the following parameters were noted: vessel enhancement, enhancement pattern in the equilibrium phase, maximal transverse diameter, the lowest enhancement, and the attenuation values of each hepatocellular lesion in the precontrast and triple-phase series, including the arterial phase, portal phase and equilibrium phase. MRI data were analysed, and the following parameters were noted: signal intensities of each hepatocellular lesion on T2-weighted images and T1-weighted images, and signal intensity ratio of the hepatocellular lesions in the hepatobiliary phase.

Results

In 62.5% of poorly/moderately-differentiated HCC and 75% of well-differentiated HCC, presumptive necrosis was detected on CT and MRI. In the hepatobiliary phase on MRI, the median signal intensity ratio of poorly/moderately-differentiated HCC (0.54 [range: 0.3–0.71]) was significantly lower than that of well-differentiated HCC (0.75 [range: 0.6–0.96]) and hyperplasia (0.79 [range: 071–0.98]; $p = 0.02$ and $p = 0.02$, respectively).

Conclusion

Gd-EOB-DTPA-enhanced MRI may be a superior modality for differentiating hepatocellular origin lesions.

Related Information

Recommended

Assessment of hepatitis and fibrosis using Gd-EOB-DTPA MRI in dogs
Toshiyuki Tanaka, Hidetaka Nishida, Keiichiro Mie, Hiroki Yamazaki, Lee-Shuan Lin, Hideo Akiyoshi
Veterinary Record Open

Contrast-enhanced ultrasound features of hepatocellular carcinoma in dogs
Tommaso Banzato, Giuseppe Rubini, Riccardo Orlandi, Paolo Bargellini, Federico Bonsembiante, Alessandro Zotti
Veterinary Record

Cellular characteristics of keratin 19-positive canine hepatocellular tumours explain its aggressive behaviour
Renee G van Sprundel, Ted SGAM van den Ingh, Baukje A Schotanus, Monique E van Wolferen, Louis C Penning, Jan Rothuizen , Bart Spee
Veterinary Record Open

Clinical, laboratory and ultrasonographic findings differentiating lowgrade

出典　doi: 10.1002/vetr.1083.
https://bvajournals.onlinelibrary.wiley.com/doi/10.1002/vetr.1083

最終責任者　Hideo Akiyoshi (Corresponding Author)

A system update is scheduled January 7th-9th and there may be a brief interruption. We apologize for any inconvenience.

Wiley Online Library

Search

Login / Register

Veterinary Medicine and Science

Volume 7, Issue 6
November 2021
Pages 2172-2177

CASE REPORT Open Access

Computed tomography may detect liver infiltration of canine diffuse hepatic lymphoma

Toshiyuki Tanaka, Hiroki Yamazaki, Kazuna Ashida, Yasumasa Iimori, Keiichiro Mie, Hidetaka Nishida, Hideo Akiyoshi

First published: 14 August 2021 | https://doi.org/10.1002/vms3.598

SECTIONS PDF TOOLS SHARE

Abstract

Background

In dogs, hepatic lymphoma is characterized by neoplastic lymphocyte infiltration into the liver. Reports on the computed tomography (CT) findings of the liver for canine hepatic lymphoma are few, with only one study of multiple liver lesions type.

Objectives

The purpose of this study was to retrospectively assess the CT findings of the liver in canine diffuse hepatic lymphoma.

Methods

As control, five dogs without abnormalities in the liver were included. CT data were analysed, and the following were noted: presence of edge bluntness of the liver, presence of periportal collar sign, the liver size:body weight (BW) ratio and the mean attenuation of liver lesions on pre-contrast, arterial-phase, portal-phase and equilibrium-phase post-contrast images.

Results

On CT examination, edge bluntness of the liver was significantly detected in lymphoma (4/5, 80%), as opposed to the control (0/5, 0%) ($p = 0.048$, $\varphi = 0.82$). The periportal collar sign was detected in lymphoma (3/5, 60%), as opposed to the control (0/5, 0%) ($p = 0.17$, $\varphi = 0.65$). The liver size:BW ratio of lymphoma cases was significantly higher compared to that of the control cases ($p = 0.0002$, $r = 0.92$). The mean Hounsfield unit of lymphoma cases in the pre-contrast, arterial-phase, portal-phase and equilibrium-phase images were significantly lower than in the control cases ($p = 0.005$, $r = 0.81$; $p = 0.0003$, $r = 0.91$; $p = 0.01$, $r = 0.75$ and $p = 0.02$, $r = 0.71$, respectively).

Conclusions

Hepatic lymphoma should be a differential for a blunted and enlarged liver with

Figures References Related Information

Recommended

Comparison between computed tomographic and ultrasonographic findings of the liver and spleen in dogs with confirmed hepatic or splenic lymphoma involvement
Luis Mesquita, Riccardo Finotello, Amy Ferreira, Thomas Maddox
Veterinary Record

Canine DLA diversity: 1. New alleles and haplotypes
L. J. Kennedy, A. Barnes, A. Short, J. J. Brown, S. Lester, J. Seddon, L. Fleeman, O. Francino, M. Brkljacic, S. Knyazev, G. M. Happ, W. E. R. Ollier
Tissue Antigens

ASSOCIATIONS BETWEEN DUAL-PHASE COMPUTED TOMOGRAPHY FEATURES AND HISTOPATHOLOGIC DIAGNOSES IN 52 DOGS WITH HEPATIC OR SPLENIC MASSES
Ian D. Jones, Christopher R. Lamb, Randi Drees, Simon L. Priestnall, Panagiotis Mantis
Veterinary Radiology & Ultrasound

HEPATIC VOLUME ESTIMATION USING QUANTITATIVE COMPUTED TOMOGRAPHY IN DOGS WITH

出典　doi: 10.1002/vms3.598. https://onlinelibrary.wiley.com/doi/10.1002/vms3.598

最終責任者　Hideo Akiyoshi (Corresponding Author)



出典　doi: 10.1292/jvms.20-0656.
https://www.jstage.jst.go.jp/article/jvms/83/8/83_20-0656/_article

最終責任者　Shunsuke Noguchi (Corresponding Author)



出典　doi: 10.1177/1098612X20932819.
https://journals.sagepub.com/doi/10.1177/1098612X20932819?url_ver=Z39.88-2003&rfr_id=ori:rid:crossref.org&rfr_dat=cr_pub%20%200pubmed

最終責任者　Hideo Akiyoshi (Corresponding Author)

Japanese Journal of Veterinary Research 69(3): 163-173, 2021

JJVR

REGULAR PAPER Clinical Case Report

Contrast-enhanced computed tomography characterization of canine rectal neoplasms

Toshiyuki Tanaka[1,2], Yasumasa Iimori[1], Hiroki Yamazaki[1], Hidetaka Nishida[1] and Hideo Akiyoshi[1,*]

[1] Laboratory of Veterinary Surgery, Department of Graduate School of Life and Environmental Sciences, Osaka Prefecture University, 1-58 Rinku, Ohrai-kita Izumisano, Osaka 598-8531, Japan
[2] Kinki Animal Medical Training Institute & Veterinary Clinic, 3-15-27 Hishie, Higashiosaka, Osaka 578-0984, Japan

Received for publication, February 16, 2021; accepted, July 9, 2021

Abstract

Differential diagnosis of rectal neoplasms is necessary to determine an appropriate treatment plan. In humans, computed tomography (CT) is used to evaluate colorectal neoplasms. This retrospective study assessed the CT features of canine rectal neoplasms, including seventeen inflammatory polyps, six adenocarcinomas, three B-cell lymphomas and four leiomyomas on triple-phase CT. A mass lesion was observed in all seventeen cases of inflammatory polyps (100%), two of six adenocarcinomas (33%), and all four cases of leiomyoma (100%). Wall thickening was observed in four of six (67%) adenocarcinoma cases and all three (100%) lymphoma cases. The leiomyoma was more likely to show obstruction than inflammatory polyps, adenocarcinomas, and lymphomas. Homogeneous enhancement was detected in zero of seventeen (0%) inflammatory polyp cases, two of six (33%) adenocarcinoma cases, all three (100%) lymphoma cases, and all four (100%) leiomyoma cases in all post contrast phases. Lymphadenopathy was detected in three adenocarcinoma cases (50%) and three lymphoma cases (100%). Inflammatory polyps indicated a heterogeneous radial-enhancement mass. Leiomyomas indicated a homogeneous enhancement mass with bowel obstruction. In wall thickening lesions, adenocarcinoma indicated two-layer thickened annular lesions and lymphoma indicated homogeneous thickened annular lesions but less enhancement than the mucosa. These findings may help confirm the diagnosis and reduce the use of invasive biopsy procedures.

Key Words: Adenocarcinoma, Inflammatory polyp, Leiomyoma, Lymphoma, Miniature Dachshunds

出典　doi: 10.14943/jjvr.69.3.163
https://eprints.lib.hokudai.ac.jp/dspace/bitstream/2115/82780/1/JJVR69-3_163-173_ToshiyukiTanaka.pdf

最終責任者　Hideo Akiyoshi (Corresponding Author)

Veterinary and Comparative Oncology



Volume 18, Issue 4
December 2020
Pages 861-865

SHORT COMMUNICATION

Less enhancement and low apparent diffusion coefficient value on magnetic resonance imaging may be helpful to detect canine prostate adenocarcinoma in case series

Toshiyuki Tanaka, Kazuna Ashida, Yasumasa Iimori, Hiroki Yamazaki, Keiichiro Mie, Hidetaka Nishida, Hideo Akiyoshi

First published: 12 February 2020 | https://doi.org/10.1111/vco.12578 | Citations: 1

Read the full text › PDF TOOLS SHARE

Abstract

In dogs, diagnosis of prostate cancer is often delayed because clinical signs are not pathognomonic. Although ultrasonography is mainly performed to detect prostate cancer, the ultrasonographic appearance is not specific. In humans, magnetic resonance imaging (MRI), including diffusion-weighted imaging (DWI) is used to localize the prostate tumour. To our knowledge, there are no studies of MRI findings for detecting or localizing prostate cancer. The purpose of this study was to assess MRI findings of prostate cancer. As a control, three prostate hyperplasia cases were included. MRI data were analysed, and the following parameters were noted: signal intensity (SI) of prostate lesion on T2-weighted imaging, T1-weighted imaging and DWI, enhancement pattern of prostate lesion, and relative contrast enhancement indices (RCEI) and apparent diffusion coefficient (ADC) value of prostate lesion. For MRI examination, the mean RCEI of the adenocarcinoma was significantly lower than that of hyperplasia ($P = .01$, $r = .8$). The SI of the DWI of adenocarcinoma was significantly higher compared to hyperplasia ($P = .03$, $\varphi = 1$). The mean ADC values of the adenocarcinoma were significantly lower than that of hyperplasia ($P = .03$, $r = .82$). Thus, less enhancement on MRI, and low ADC value on MRI may help to detect prostate adenocarcinoma.

Related Information

Recommended

Principles of Prostate Magnetic Resonance Imaging
Sonia Gaur, Baris Turkbey, Peter L. Choyke
Smith's Textbook of Endourology, [1]

TUで□34:08: Short Term Reproducibility in Apparent Diffusion Coefficient for Diffusion Weighted MRI of the Prostate
M Sadinski, M Medved, I Karademir, S Wang, Y Peng, Y Jiang, S Sammet, G Karczmar, A Oto
Medical Physics

Risk stratification of prostate cancer: utilizing apparent diffusion coefficient value and lesion volume on multiparametric MRI
Simpa S. Salami MD, MPH, Eran Ben-Levi MD, Oksana Yaskiv MD, Baris Turkbey MD, Robert Villani MD, Ardeshir R. Rastinehad DO
Journal of Magnetic Resonance Imaging

An open-label dose escalation study

出典　doi: 10.1111/vco.12578. https://onlinelibrary.wiley.com/doi/10.1111/vco.12578

最終責任者　Hideo Akiyoshi (Corresponding Author)

獣医解剖学（Veterinary Anatomy）

Takafumi Watanabe

Associate Professor

准教授　渡邉　敬文

Ⅰ．筆頭または責任著者　＜First or Corresponding Author＞

1) The unique physiological features of the broiler pectoralis major muscle as suggested by the three-dimensional ultrastructural study of mitochondria in type IIb muscle fibers.
Hosotani M, Kametani K, Ohno N, Hiramatsu K, Kawasaki T, Hasegawa Y, Iwasaki T, **Watanabe T.**
J Vet Med Sci. 2021 Nov 24;83(11):1764-1771.

Ⅱ．その他＜Others＞

1) Effects of intra-articular inoculation with Mycoplasma bovis on immunological responses in calf joints.
Nishi K, Hirano Y, Sato A, Eguchi A, Matsuda K, Toda M, **Watanabe T**, Iwasaki T, Takahashi N, Hosotani M, Watanabe R, Kato T, Ohtsuka H, Gondaira S, Higuchi H.
Vet Immunol Immunopathol. Accepted.

2) Versican contributes to ligament formation of knee joints.
Higuchi T, Suzuki D, **Watanabe T**, Fanhchaksai K, Ota K, Yokoo K, Furukawa H, Watanabe H.
PLoS ONE. 2021 Apr 22;16(4): e0250366.

3) Unique histological features of the tail skin of cotton rat (Sigmodon hispidus) related to caudal autotomy.
Hosotani M, Nakamura T, Ichii O, Irie T, Sunden Y, Elewa YHA, **Watanabe T**, Ueda H, Mishima T, Kon Y.
Biol Open. 2021 Feb 19;10(2): bio058230.

4) Accumulation of lipofuscin in broiler chicken with wooden breast.
Hasegawa Y, Kawasaki T, Maeda N, Yamada M, Takahashi N, **Watanabe T,** Iwasaki T. *Anim Sci J*. 2021 Jan;92(1): e13517.

The Journal of Veterinary Medical Science

FULL PAPER

Anatomy

The unique physiological features of the broiler pectoralis major muscle as suggested by the three-dimensional ultrastructural study of mitochondria in type IIb muscle fibers

Marina HOSOTANI[1)], Kiyokazu KAMETANI[1)], Nobuhiko OHNO[2,3)], Kohzy HIRAMATSU[4)], Takeshi KAWASAKI[5)], Yasuhiro HASEGAWA[6)], Tomohito IWASAKI[6)]* and Takafumi WATANABE[1)]*

[1)]Department of Veterinary Anatomy, School of Veterinary Medicine, Rakuno Gakuen University, Ebetsu, Hokkaido 069-8501, Japan

[2)]Division of Ultrastructural Research, National Institute for Physiological Science, Okazaki, Aichi 444-8585, Japan

[3)]Division of Histology and Cell Biology, Department of Anatomy, Jichi Medical University, Shimotsuke, Tochigi 329-0498, Japan

[4)]Laboratory of Animal Functional Anatomy (LAFA), Faculty of Agriculture, Shinshu University, Kami-ina, Nagano 399-4598, Japan

[5)]Research Office Concerning the Health of Humans and Birds, Abashiri, Hokkaido 099-3119, Japan

[6)]Department of Food Science and Human Wellness, College of Agriculture, Food and Environment Science, Rakuno Gakuen University, Ebetsu, Hokkaido 069-8501, Japan

ABSTRACT. Typical skeletal muscles are composed of mixed muscle fiber types, which are classified as slow-twitch (type I) and fast-twitch (type II) fibers, whereas pectoralis major muscles (PMs) in broiler chickens are 100% composed of type IIb fast-twitch fibers. Since metabolic properties differ among muscle fiber types, the combination of muscle fiber types is involved in physiological functions and pathological conditions in skeletal muscles. In this study, using serial block-face scanning electron microscopy, we compared three-dimensional (3D) mitochondrial properties in type IIb fibers in broiler PMs and those in type I fibers of broiler gastrocnemius muscles (GMs) heterogeneously composed of slow- and fast-twitch muscle fibers. In type I fibers in the GMs, elongated mitochondria with numerous interconnections to form a substantial network among myofibrils were observed. Along with lipid droplets sandwiched by mitochondria, these features are an adaptation to effective oxidative respiration and constant oxidative damage in slow-twitch muscle fibers. In contrast, type IIb fibers in the PMs showed small and ellipsoid-shaped mitochondria with few interconnections and no lipid droplets, forming a sparse network. The mitochondrial spatial network comprises of active mitochondrial dynamics to reduce mitochondrial damage; therefore, type IIb fibers possess physiologically low capacity to maintain mitochondrial wellness due to static mitochondrial dynamics. Based on 3D mitochondrial properties, we discussed the contrasting physiological functions between type I and IIb fibers and proposed a high contractile power and low stress resistance as unique physiological properties of broiler PMs.

KEY WORDS: 3D reconstruction, mitochondria, slow-/fast-twitch muscle, ultrastructure, wooden breast syndrome

J. Vet. Med. Sci.
83(11): 1764–1771, 2021
doi: 10.1292/jvms.21-0408

Received: 21 July 2021
Accepted: 5 September 2021
Advanced Epub:
15 September 2021

出典　doi: 10.1292/jvms.21-0408
https://www.ncbi.nlm.nih.gov/pmc/articles/PMC8636870/pdf/jvms-83-1764.pdf

最終責任者　Takafumi Watanabe (Corresponding Author)

Veterinary Immunology and Immunopathology 244 (2022) 110364



Contents lists available at ScienceDirect

Veterinary Immunology and Immunopathology

journal homepage: www.elsevier.com/locate/vetimm



Research paper

Effects of intra-articular inoculation with *Mycoplasma bovis* on immunological responses in calf joints

Koji Nishi [a,b], Yuki Hirano [a,c], Ayano Sato [d], Ayako Eguchi [a], Kazuya Matsuda [e], Miyuki Toda [e], Takafumi Watanabe [f], Tomohito Iwasaki [g], Naoki Takahashi [h], Marina Hosotani [f], Reina Watanabe [a], Toshihide Kato [d], Hiromichi Ohtsuka [d], Satoshi Gondaira [a,*], Hidetoshi Higuchi [a,*]

[a] *Animal Health Laboratory, Department of Veterinary Science, School of Veterinary Medicine, Rakuno Gakuen University, Ebetsu, Hokkaido, Japan*
[b] *NOSAI Okhotsk Monbetsu Veterinary Clinic, Monbetsu, Hokkaido, Japan*
[c] *Animal Research Center, Agricultural Research Department, Hokkaido Research Organization, Shintoku, Hokkaido, Japan*
[d] *Large Animal Clinical Science, Department of Veterinary Science, School of Veterinary Medicine, Rakuno Gakuen University, Ebetsu, Hokkaido, Japan*
[e] *Department of Veterinary Pathology, Department of Veterinary Science, School of Veterinary Medicine, Rakuno Gakuen University, Ebetsu, Hokkaido 069-8501, Japan*
[f] *Laboratory of Veterinary Anatomy, School of Veterinary Medicine, Rakuno Gakuen University, Ebetsu, Hokkaido, Japan*
[g] *Department of Food Science and Human Wellness, College of Agriculture, Food and Environment Science, Rakuno Gakuen University, Hokkaido, Japan*
[h] *Department of Veterinary Anatomy, College of Bioresource Sciences, Nihon University, Fujisawa, Kanagawa, Japan*

ARTICLE INFO

Keywords:
Arthritis
Inflammatory cytokines
Invasion
Matrix metalloproteinases
Mycoplasma bovis

ABSTRACT

Mycoplasma arthritis that caused by *Mycoplasma bovis* exhibit severe lameness. This disease is difficult to cure with antibiotics, but the detailed pathological mechanisms have not been fully clarified. In this study, we examined the effects of intra-articular inoculation with *M. bovis* on immunological responses in calf joints. We inoculated three calves each with *M. bovis* or phosphate buffer saline (control) into the right stifle joint and dissected them at 15 days postinoculation. *Mycoplasma bovis*–inoculated calves exhibited swelling of the stifle joint, increases in synovial fluid, fibrin deposition, and cartilage thinning. Intracellular *M. bovis* was detected in synovial tissues analyzed by immunohistochemistry and transmission electron microscopy. Messenger RNA expressions of interleukin (IL)-1β, IL-6, IL-8, IL-12p40, and IL-17A in synovial fluid cells and synovial tissues from *M. bovis*–inoculated calves were significantly higher than those from control calves. Protein levels of these cytokines in synovial fluid from *M. bovis*–inoculated calves were markedly higher than those from control calves. Our study clarified that inoculation with *M. bovis* into the stifle joint induced the production of inflammatory cytokines by synovial fluid cells and synovial tissues, causing a severe inflammatory response in joints. Additionally, *M. bovis* could invade cells in synovial tissues, which may have aided it in evading antibiotics and host immune surveillance.

出典　doi: 10.1016/j.vetimm.2021.110364.
https://pubmed.ncbi.nlm.nih.gov/34952252/

最終責任者　Hidetoshi Higuchi (Corresponding Author)

PLOS ONE

RESEARCH ARTICLE

Versican contributes to ligament formation of knee joints

Tomoko Higuchi[1], Daisuke Suzuki[2], Takafumi Watanabe[3], Kanda Fanhchaksai[4], Keiko Ota[4], Kazuhisa Yokoo[1], Hiroshi Furukawa[1], Hideto Watanabe[4]*

1 Department of Plastic Surgery, Aichi Medical University, Nagakute, Japan, **2** Department of Health Sciences, Hokkaido Chitose College of Rehabilitation, Chitose, Japan, **3** Laboratory of Veterinary Anatomy, School of Veterinary Medicine, Rakuno Gakuen University, Ebetsu, Japan, **4** Institute for Molecular Science of Medicine, Aichi Medical University, Nagakute, Japan

* wannabee@aichi-med-u.ac.jp

Check for updates

OPEN ACCESS

Citation: Higuchi T, Suzuki D, Watanabe T, Fanhchaksai K, Ota K, Yokoo K, et al. (2021) Versican contributes to ligament formation of knee joints. PLoS ONE 16(4): e0250366. https://doi.org/10.1371/journal.pone.0250366

Editor: Marco Franchi, University of Bologna, ITALY

Abstract

Versican is a large proteoglycan in the extracellular matrix. During embryonic stages, it plays a crucial role in the development of cartilage, heart, and dermis. Previously, we reported that *Prx1-Vcan* conditional knockout mice, lacking Vcan expression in mesenchymal condensation areas of the limb bud, show the impaired joint formation and delayed cartilage development. Here, we investigated their phenotype in adults and found that they develop swelling of the knee joint. Histologically, their newborn joint exhibited impaired formation of both anterior and posterior cruciate ligaments. Immunostaining revealed a decrease in scleraxis-positive cells in both articular cartilage and ligament of *Prx1-Vcan* knee joint, spotty patterns of type I collagen, and the presence of type II collagen concomitant with the absence of versican expression. These results suggest that versican expression during the perinatal period is required for cruciate ligaments' formation and that its depletion affects joint function in later ages.

出典　doi: 10.1371/journal.pone.0250366.
https://www.ncbi.nlm.nih.gov/pmc/articles/PMC8061984/pdf/pone.0250366.pdf

最終責任者　Hideto Watanabe (Corresponding Author)

© 2021. Published by The Company of Biologists Ltd | Biology Open (2021) 10, bio058230. doi:10.1242/bio.058230

RESEARCH ARTICLE

Unique histological features of the tail skin of cotton rat (*Sigmodon hispidus*) related to caudal autotomy

Marina Hosotani[1,*], Teppei Nakamura[2,3,*,‡], Osamu Ichii[2,4], Takao Irie[5,6], Yuji Sunden[7], Yaser Hosny Ali Elewa[2,8], Takafumi Watanabe[1], Hiromi Ueda[1], Takashi Mishima[3] and Yasuhiro Kon[2]

ABSTRACT

Caudal autotomy in rodents is an evolutionarily acquired phenomenon enabling escape from predators, by discarding the tail skin after traumatic injuries. The histological mechanisms underlying caudal autotomy seem to differ among species. Cotton rats (*Sigmodon hispidus*), which are important laboratory rodents for human infectious diseases, possess a fragile tail. In this study, we compared the tail histology of cotton rats with that of laboratory rats (*Rattus norvegicus*), which have no fragility on their tail, to elucidate the process of rodent caudal autotomy. First, the cotton rats developed a false autotomy characterized by loss of the tail sheath with the caudal vertebrae remaining without tail regeneration. Second, we found the fracture plane was continuous from the interscale of the tail epidermis to the dermis, which was lined with an alignment of E-cadherin$^+$ cells. Third, we found an obvious cleavage plane between the dermis and subjacent tissues of the cotton-rat tail, where the subcutis was composed of looser, finer, and fragmented collagen fibers compared with those of the rat. Additionally, the cotton-rat tail was easily torn, with minimum bleeding. The median coccygeal artery of the cotton rat had a thick smooth muscle layer, and its lumen was filled with the peeled intima with fibrin coagulation, which might be associated with reduced bleeding following caudal autotomy. Taken together, we reveal the unique histological features of the tail relating to the caudal autotomy process in the cotton rat, and provide novel insights to help clarify the rodent caudal autotomy mechanism.

KEY WORDS: Cotton rat, Rat, Caudal autotomy, Tail histology, Collagen

[1]Laboratory of Veterinary Anatomy, Department of Veterinary Medicine, School of Veterinary Medicine, Rakuno Gakuen University, Ebetsu, Hokkaido 069-8501, Japan. [2]Laboratory of Anatomy, Department of Basic Veterinary Science, Faculty of Veterinary Medicine, Hokkaido University, Sapporo, Hokkaido, Japan. [3]Department of Biological Safety Research, Chitose Laboratory, Japan Food Research Laboratories, Chitose, Hokkaido, Japan. [4]Laboratory of Agrobiomedical Science, Faculty of Agriculture, Hokkaido University, Sapporo, Hokkaido, Japan. [5]Medical Zoology Group, Department of Infectious Diseases, Hokkaido Institute of Public Health, Sapporo, Hokkaido, Japan. [6]Laboratory of Veterinary Parasitic Diseases, Department of Veterinary Sciences, Faculty of Agriculture, Center for Animal Disease Control, University of Miyazaki, Miyazaki, Japan. [7]Laboratory of Veterinary Pathology, Faculty of Agriculture, Tottori University, Tottori 680-8550, Japan. [8]Department of Histology and Cytology, Faculty of Veterinary Medicine, Zagazig University, Zagazig, Egypt.
*These authors contributed equally to this work

‡Author for correspondence (nakamurate@vetmed.hokudai.ac.jp)

M.H., 0000-0003-0360-3360; T.N., 0000-0003-3204-0245; O.I., 0000-0002-6643-1554; T.I., 0000-0002-8733-0832; Y.K., 0000-0002-6859-6122

This is an Open Access article distributed under the terms of the Creative Commons Attribution License (https://creativecommons.org/licenses/by/4.0), which permits unrestricted use, distribution and reproduction in any medium provided that the original work is properly attributed.

Received 27 November 2020; Accepted 15 January 2021

INTRODUCTION

Autotomy, the phenomenon of discarding or shedding a part of the body, is preserved in some animal species and is generally considered a self-defense mechanism to escape from predators (Emberts et al., 2019). In vertebrates, many lizards are well known as species that can undergo autotomy of the tail, which is followed by subsequent regeneration (Zani, 1996). In mammals, several species of rodents have been reported to possess autotomy of the tail related to predator avoidance as well (Shargal et al., 1999). For example, spiny mice (*Acomys cahirinus*), eastern chipmunks (*Tamias striatus*), and degu (*Octodon degus*) shed their tail skin easily in response to traumatic injuries (Shargal et al., 1999). In contrast with the true autotomy in reptiles, where the entire tail including the caudal vertebra is lost, most instances of autotomy in rodents have been considered a false autotomy, where the tail skin is lost but the vertebra remains (Dubost and Gasc, 1987).

Autotomy in rodents has been reported in five families and at least 27 species, although the precise histology related to the autotomy mechanism varies among species (Shargal et al., 1999). The autotomy process in rodents includes two stages: rupture, and healing of tissue. Specifically for the former, in spiny mice, greater space occupied by hair follicles in the dermis and less absolute connective tissue have been associated with decreased skin elasticity (Seifert et al., 2012). However, the autotomy mechanism has been poorly understood in rodents, except for the spiny mouse, which has been well investigated because of their unique systemic regenerative ability of the injured skin (Shargal et al., 1999; Seifert et al., 2012). In particular, the lack of histological observations on the tail skin in rodents has made it difficult to understand the rupture process of tissue and the variety and/or similarity of mechanisms underlying caudal autotomy among species.

The cotton rat (*Sigmodon hispidus*) is a rodent that is distributed over most of the southern USA. They are classified in the family Cricetidae (with hamsters and gerbils) and belong to a different family from the laboratory rat (*Rattus norvegicus*) and the laboratory mouse (*Mus musculus*), which are classified as Muridae (Coe and Prince, 1996). The cotton rat has been selected as a laboratory animal model in the field of infectious research because it can faithfully reproduce human infectious diseases (Boukhvalova et al., 2009). In addition to its utility in infectious disease research, to date we have reported interesting systemic pathological phenotypes of cotton rats, including chronic kidney disease, chronic anemia, and metabolic disorders (Ichii et al., 2016, 2018, 2020; Nakamura et al., 2019). In addition, the interesting characteristics of cotton rats include a fragile tail (i.e. autotomy); they therefore should not be captured by the tail, as they may spin and shed the tail skin to run away (Faith et al., 1977). Hence, cotton rats can be a useful laboratory animal not only to explore several human diseases but also to investigate the mechanisms underlying the expression of biological characteristics in animals, such as caudal autotomy.

出典　doi: 10.1242/bio.058230.
https://www.ncbi.nlm.nih.gov/pmc/articles/PMC7904004/pdf/biolopen-10-058230.pdf

最終責任者　Marina Hosotani (Corresponding Author)

Animal Science Journal

ORIGINAL ARTICLE

Accumulation of lipofuscin in broiler chicken with wooden breast

Yasuhiro Hasegawa, Takeshi Kawasaki, Naoyuki Maeda, Michi Yamada, Naoki Takahashi, Takafumi Watanabe, Tomohito Iwasaki

First published: 31 January 2021 | https://doi.org/10.1111/asj.13517 | Citations: 1

Read the full text › PDF TOOLS SHARE

Abstract

Lipofuscin is one of the indicators of oxidative stress. To elucidate the role of oxidative stress in the development of wooden breast, this study investigates lipofuscin accumulation in various parts of wooden breast muscles. Sampling was performed using 46-day-old broiler chickens housed at a commercial Japanese poultry slaughterhouse. Fourteen wooden breast fillets and 13 normal breast fillets were collected in the deboning line. The samples used to measure shear force, 2-thiobarbituric acid reactive substance (TBARS), and for histological analysis were taken from the six portions of breast muscle fillets. In muscles affected by wooden breast, vacuolated muscle fibers were observed, and connective tissues appearing like perimysium were expanded with fibrosis. TBARS value and accumulation of lipofuscin were significantly higher in the wooden breast than in the normal breasts. A lot of lipofuscin granules were localized in the cytoplasm of collapsed muscle fibers of the wooden breast. The cranial portion of the wooden breast showed the highest shear force. The cranial position had a large amount of connective tissue and lipofuscin granules. The results of the present study strongly suggest that high oxidative stress, especially with a significant accumulation of lipofuscin, is associated with the development of wooden breasts.

出典　doi: 10.1111/asj.13517.
https://onlinelibrary.wiley.com/doi/10.1111/asj.1351

最終責任者　Tomohito Iwasaki (Corresponding Author)

人獣共通感染症学（Zoonotic Diseases）

Leo Uchida

Lecturer

講師　内田　玲麻

Ⅰ．筆頭または責任著者　＜First or Corresponding Author＞

1）Isolation and Characterization of Mosquito-Associated *Spiroplasma cantharicola* from *Aedes japonicus* Collected in Hokkaido, Japan.
Shimooka M, Sakurai Y, Muramatsu Y, **Uchida L.**
Insects 12(12):1056. 2021. doi.org/10.3390/insects12121056.

2）Zika Virus Potential Vectors among *Aedes* Mosquitoes from Hokkaido, Northern Japan: Implications for Potential Emergence of Zika Disease.
Uchida L, Shibuya M, Morales-Vargas RE, Hagiwara K, Muramatsu Y.
Pathogens 10(8):938. 2021. doi: 10.3390/pathogens10080938.

Ⅱ．その他＜Others＞

1）Seroepidemiological surveys of tick-borne encephalitis virus and novel tick-borne viruses in wild boar in Nagasaki, Japan.
Luvai EAC, **Uchida L**, Tun MMN, Inoue S, Weiyin H, Shimoda H, Morita K, Hayasaka D.
Ticks Tick Borne Dis 13(1):101860. 2022. doi: 10.1016/j.ttbdis.2021.101860.

insects

MDPI

Article

Isolation and Characterization of Mosquito-Associated *Spiroplasma cantharicola* from *Aedes japonicus* Collected in Hokkaido, Japan

Makoto Shimooka, Yoshimi Sakurai, Yasukazu Muramatsu and Leo Uchida *

School of Veterinary Medicine, Rakuno Gakuen University, Ebetsu 069-8501, Hokkaido, Japan; s21761034@stu.rakuno.ac.jp (M.S.); s21561167@g.rakuno.ac.jp (Y.S.); y-mrmt@rakuno.ac.jp (Y.M.)
* Correspondence: uchidaleo@rakuno.ac.jp; Tel.: +81-11-388-4828

Simple Summary: *Spiroplasma*, which comprises a group of the smallest known bacteria, is commonly found in insects and plants. Some species of *Spiroplasma* have shown pathogenicity against mosquitoes and are expected to be useful vector control tools. In this study, we isolated *S. cantharicola* from the mosquito *Aedes japonicus* collected in Hokkaido, northern Japan. Field surveillance implied a relatively low prevalence of the bacteria in the local mosquitoes. Phylogenetic analysis showed that our isolate is closer to a strain of *S. cantharicola* isolated from mosquitoes in previous studies. Our isolate grew well in the R2 broth medium and grew into a visible colony on R2 broth agar. Co-culturing with mosquito-derived C6/36 cells resulted in slightly more bacterial growth than culturing without cells, showing the strong cytopathogenic effect of the cells. To our knowledge, this is the third report on the isolation of *S. cantharicola* from mosquitoes.

Abstract: Species of the genus *Spiroplasma* are common within arthropods and plants worldwide. Mosquito-associated *Spiroplasma* spp. have been reported to show pathogenicity toward mosquitoes, which serve as vectors of several infectious diseases that have detrimental effects on public health. Although *Spiroplasma* spp. are expected to have potential use as biological vector-control tools, characteristics such as their distribution, host species, and cytopathogenic effects (CPEs) are not well understood. In this study, we isolated a *Spiroplasma* sp. from a female *Aedes japonicus* collected in Hokkaido, northern Japan. Phylogenetic analysis based on the 16S rRNA gene sequence indicated our isolate was closely related to *S. cantharicola*. We screened 103 mosquito pools consisting of 3 genera and 9 species, but only detected *S. cantharicola* in the first isolation. In an in vitro assay, our isolate grew well at 28 °C, but no propagation was observed at 37 °C. Furthermore, the isolate showed strong CPE on a mosquito-derived cultured cell line (C6/36), and its propagation slightly increased when co-cultured with C6/36 cells. To our knowledge, this is the third report of the isolation of *S. cantharicola* from mosquitoes and the first case in Asia. Our findings provide epidemiological data on *S. cantharicola* distribution in the region.

Keywords: *Aedes japonicus*; C6/36 cells; cytopathogenic effect; Japan; mosquito; *Spiroplasma cantharicola*

check for updates

Citation: Shimooka, M.; Sakurai, Y.; Muramatsu, Y.; Uchida, L. Isolation and Characterization of Mosquito-Associated *Spiroplasma cantharicola* from *Aedes japonicus* Collected in Hokkaido, Japan. *Insects* **2021**, *12*, 1056. https://doi.org/10.3390/insects12121056

Academic Editors: Adriano Pinter and Karin Kirchgatter

Received: 14 October 2021
Accepted: 23 November 2021
Published: 25 November 2021

Publisher's Note: MDPI stays neutral with regard to jurisdictional claims in published maps and institutional affiliations.

出典　doi.org/10.3390/insects12121056.
https://www.mdpi.com/2075-4450/12/12/1056
最終責任者　Leo Uchida (Corresponding Author)

pathogens

MDPI

Article

Zika Virus Potential Vectors among *Aedes* Mosquitoes from Hokkaido, Northern Japan: Implications for Potential Emergence of Zika Disease

Leo Uchida [1,*], Miki Shibuya [1], Ronald Enrique Morales-Vargas [2], Katsuro Hagiwara [1] and Yasukazu Muramatsu [1]

[1] School of Veterinary Medicine, Rakuno Gakuen University, Ebetsu, Hokkaido 069-8501, Japan; s21361159@g.rakuno.ac.jp (M.S.); k-hagi@rakuno.ac.jp (K.H.); y-mrmt@rakuno.ac.jp (Y.M.)

[2] Department of Medical Entomology, Faculty of Tropical Medicine, Mahidol University, Ratchathewi, Bangkok 10400, Thailand; ronald.mor@mahidol.ac.th

* Correspondence: uchidaleo@rakuno.ac.jp; Tel.: +81-11-388-4828

Abstract: The Zika virus (ZIKV) is a rapidly expanding mosquito-borne virus that causes febrile illness in humans. *Aedes aegypti* and *Ae. albopictus* are the primary ZIKV vectors; however, the potential vector competence of other *Aedes* mosquitoes distributed in northern Japan (Palearctic ecozone) are not yet known. In this study, the susceptibility to Zika virus infection of three *Aedes* mosquitoes distributed in the main city of the northern Japan and their capacities as vectors for ZIKV were evaluated. Field-collected mosquitoes were fed ad libitum an infectious blood meal containing the ZIKV PRVABC59. The Zika virus was detected in the abdomen of *Ae. galloisi* and *Ae. japonicus* at 2–10 days post infection (PI), and from the thorax and head of *Ae. galloisi* at 10 days PI, resulting in 17.6% and 5.9% infection rates, respectively. The Zika virus was not detected from *Ae. punctor* at any time. Some northern Japanese *Aedes* could be suspected as vectors of ZIKV but the risk may be low when compared with major ZIKV vectors.

Keywords: Zika virus; susceptibility; *Aedes japonicus*; *Aedes galloisi*; *Aedes* mosquitoes; Palearctic ecozone

check for updates

Citation: Uchida, L.; Shibuya, M.; Morales-Vargas, R.E.; Hagiwara, K.; Muramatsu, Y. Zika Virus Potential Vectors among *Aedes* Mosquitoes from Hokkaido, Northern Japan: Implications for Potential Emergence of Zika Disease. *Pathogens* **2021**, *10*, 938. https://doi.org/10.3390/pathogens10080938

出典　doi: 10.3390/pathogens10080938.
https://www.mdpi.com/2076-0817/10/8/938

最終責任者　Leo Uchida (First Author and Corresponding Author)

Ticks and Tick-borne Diseases 13 (2022) 101860

Contents lists available at ScienceDirect

Ticks and Tick-borne Diseases

journal homepage: www.elsevier.com/locate/ttbdis

Seroepidemiological surveys of tick-borne encephalitis virus and novel tick-borne viruses in wild boar in Nagasaki, Japan

Elizabeth Ajema Chebichi Luvai [a], Leo Uchida [b], Mya Myat Ngwe Tun [a], Shingo Inoue [a], Hu Weiyin [c], Hiroshi Shimoda [c], Kouichi Morita [b], Daisuke Hayasaka [c,*]

[a] Department of Virology, Institute of Tropical Medicine, Nagasaki University, 1-12-4 Sakamoto, Nagasaki, Nagasaki 852-8523, Japan
[b] School of Veterinary Medicine, Rakuno Gakuen University, Ebetsu, Hokkaido 069-8501, Japan
[c] Laboratory of veterinary Microbiology, Joint Faculty of Veterinary Medicine, Yamaguchi University, 1677-1 Yoshida, Yamaguchi, Yamaguchi 753-8511, Japan

ARTICLE INFO

Keywords:
Tick-borne viruses
Wild boar
Tofla virus
Tick-borne encephalitis virus
Muko virus
Kabuto mountain virus

ABSTRACT

In Japan, tick-borne viruses such as tick-borne encephalitis virus (TBEV) and severe fever with thrombocytopenia syndrome virus have been identified in humans, animals, and ticks. In addition, novel tick-borne viruses have been isolated from ticks in Japan. This study aimed to determine the seroprevalence of TBEV and novel viruses, particularly Tofla virus (TFLV), Kabuto Mountain virus (KAMV), and Muko virus (MUV) in wild boar in Nagasaki, Japan. Enzyme-linked immunosorbent assays and neutralization tests were performed to detect antibodies against each virus. Wild boar serum tested positive for antibodies against KAMV, TFLV, and TBEV, but not MUV. This study revealed the seroprevalence of newly identified tick-borne viruses and TBEV in animals residing in the Nagasaki area. The seroprevalence of these viruses in sentinel animals may inform policies aimed at preventing tick-borne virus disease outbreaks.

出典　doi: 10.1016/j.ttbdis.2021.101860
https://www.sciencedirect.com/science/article/pii/S1877959X21002132?via%3Dihub

最終責任者　Daisuke Hayasaka (Corresponding Author)

獣医衛生学（Animal Health）

Satoshi Gondaira

Lecturer

講師　権平　智

Ⅰ．筆頭または責任著者　＜First or Corresponding Author＞

1) Innate immune response in bovine neutrophils stimulated with *Mycoplasma bovis*.
Gondaira S, Nishi K, Fujiki J, Iwano H, Watanabe R, Eguchi A, Hirano Y, Higuchi H, Nagahata H
Vet Res 52(1) 58 2021. doi: 10.1186/s13567-021-00920-2.

2) Effects of intra-articular inoculation with *Mycoplasma bovis* on immunological responses in calf joints
Nishi K, Hirano Y, Sato A, Eguchi A, Matsuda K, Toda M, Watanabe T, Iwasaki T, Takahashi N, Hosotani M, Watanabe R, Kato T, Ohtsuka H, **Gondaira S**, Higuchi H.
Vet immunol immunopathol. in press 2021. doi: 10.1016/j.vetimm.2021.110364.

Ⅱ．その他＜Others＞

1) Inflammatory cytokine mRNA and protein levels in the synovial fluid of Mycoplasma arthritis calves.
Nishi K, **Gondaira S**, Okamoto M, Matsuda K, Sato A, Kato T, Sasagawa M, Tanaka T, Higuchi H.
J Vet Med Sci 83(1) 31-35 2021. doi: 10.1292/jvms.20-0491

2) Somatic cell and innate immune responses in mammary glands of lactating cows to intramammary infusion of *Bifidobacterium breve* atpre-drying off period.
Nagahata H, Kine M, Watanabe H, Tanaka A, Takahashi A, **Gondaira S**, Higuchi H.
J Vet Med Sci 82(12) 1845-1851. 2021. doi: 10.1292/jvms.21-0306

3) Fluctuating Bacteriophage-induced galU Deficiency Region is Involved in Trade-off Effects on the Phage and Fluoroquinolone Sensitivity in Pseudomonas aeruginosa.

Nakamura K, Fujiki J, Nakamura T, Furusawa T , **Gondaira S**, Usui M, Higuchi H, Tamura Y, Iwano H.
Virus Res. 198596. 2021. doi: 10.1016/j.virusres.

4) Complete Genome Sequence of a Veterinary Pseudomonas aeruginosa Isolate, Pa12.
Nakamura K, Fujiki J, Furusawa T, Nakamura T, **Gondaira S**, Sasaki M, Usui M, Higuchi H, Sawa H, Tamura Y, Iwano H.
Microbiol resour announc 10(26) e0039821. 2021. doi: 10.1128/MRA.00398-21

Gondaira et al. Vet Res (2021) 52:58
https://doi.org/10.1186/s13567-021-00920-2

VETERINARY RESEARCH

RESEARCH ARTICLE Open Access

Innate immune response in bovine neutrophils stimulated with *Mycoplasma bovis*

Satoshi Gondaira[1], Koji Nishi[1], Jumpei Fujiki[2], Hidetomo Iwano[2], Reina Watanabe[1], Ayako Eguchi[1], Yuki Hirano[3], Hidetoshi Higuchi[1*] and Hajime Nagahata[1,4]

Abstract

Mycoplasma bovis (*M. bovis*) is a significant worldwide pathogen of cattle. Neutrophils have an important role in the innate immune response during infection with *M. bovis*. However, even though neutrophils accumulate in *M. bovis* infection, the interaction of *M. bovis* and neutrophils has not been fully elucidated. We attempted to elucidate the innate immune response of neutrophils stimulated with *M. bovis* and evaluate the transcriptome and functional analysis of bovine neutrophils stimulated with *M. bovis*. Proinflammatory cytokines, such as inducible nitric oxide (*iNOS*), which was the most increased gene in transcriptome analysis, were increased in quantitative polymerase chain reaction analysis of bovine neutrophils stimulated with live or heat-killed *M. bovis*. Nitric oxide and intracellular reactive oxygen species production of neutrophils stimulated with *M. bovis* was significantly increased. Neutrophils stimulated with *M. bovis* showed an increased ratio of nonapoptotic cell death compared to unstimulated controls. We demonstrated that neutrophil extracellular traps (NETs) formation was not recognized in neutrophils stimulated with live *M. bovis*. However, heat-killed *M. bovis* induced NETs formation. We also showed the interaction with *M. bovis* and bovine neutrophils regarding proinflammatory cytokine gene expression and functional expression related to NETs formation. Live and killed *M. bovis* induced innate immune responses in neutrophils and had the potential to induce NETs formation, but live *M. bovis* escaped NETs.

Keywords: *Mycoplasma bovis*, Bovine, Neutrophils, Innate immune, Transcriptome analysis

出典　doi:110.1186/s13567-021-00920-2.
https://veterinaryresearch.biomedcentral.com/articles/10.1186/s13567-021-00920-2

最終責任者　Hidetoshi Higuchi (Corresponding Author)

Contents lists available at ScienceDirect

Veterinary Immunology and Immunopathology

journal homepage: www.elsevier.com/locate/vetimm



Research paper

Effects of intra-articular inoculation with *Mycoplasma bovis* on immunological responses in calf joints

Koji Nishi [a,b], Yuki Hirano [a,c], Ayano Sato [d], Ayako Eguchi [a], Kazuya Matsuda [e], Miyuki Toda [e], Takafumi Watanabe [f], Tomohito Iwasaki [g], Naoki Takahashi [h], Marina Hosotani [f], Reina Watanabe [g], Toshihide Kato [d], Hiromichi Ohtsuka [d], Satoshi Gondaira [a,*], Hidetoshi Higuchi [a,*]

[a] *Animal Health Laboratory, Department of Veterinary Science, School of Veterinary Medicine, Rakuno Gakuen University, Ebetsu, Hokkaido, Japan*
[b] *NOSAI Okhotsk Monbetsu Veterinary Clinic, Monbetsu, Hokkaido, Japan*
[c] *Animal Research Center, Agricultural Research Department, Hokkaido Research Organization, Shintoku, Hokkaido, Japan*
[d] *Large Animal Clinical Science, Department of Veterinary Science, School of Veterinary Medicine, Rakuno Gakuen University, Ebetsu, Hokkaido, Japan*
[e] *Department of Veterinary Pathology, Department of Veterinary Science, School of Veterinary Medicine, Rakuno Gakuen University, Ebetsu, Hokkaido 069-8501, Japan*
[f] *Laboratory of Veterinary Anatomy, School of Veterinary Medicine, Rakuno Gakuen University, Ebetsu, Hokkaido, Japan*
[g] *Department of Food Science and Human Wellness, College of Agriculture, Food and Environment Science, Rakuno Gakuen University, Hokkaido, Japan*
[h] *Department of Veterinary Anatomy, College of Bioresource Sciences, Nihon University, Fujisawa, Kanagawa, Japan*

ARTICLE INFO

Keywords:
Arthritis
Inflammatory cytokines
Invasion
Matrix metalloproteinases
Mycoplasma bovis

ABSTRACT

Mycoplasma arthritis that caused by *Mycoplasma bovis* exhibit severe lameness. This disease is difficult to cure with antibiotics, but the detailed pathological mechanisms have not been fully clarified. In this study, we examined the effects of intra-articular inoculation with *M. bovis* on immunological responses in calf joints. We inoculated three calves each with *M. bovis* or phosphate buffer saline (control) into the right stifle joint and dissected them at 15 days postinoculation. *Mycoplasma bovis*–inoculated calves exhibited swelling of the stifle joint, increases in synovial fluid, fibrin deposition, and cartilage thinning. Intracellular *M. bovis* was detected in synovial tissues analyzed by immunohistochemistry and transmission electron microscopy. Messenger RNA expressions of interleukin (IL)-1β, IL-6, IL-8, IL-12p40, and IL-17A in synovial fluid cells and synovial tissues from *M. bovis*–inoculated calves were significantly higher than those from control calves. Protein levels of these cytokines in synovial fluid from *M. bovis*–inoculated calves were markedly higher than those from control calves. Our study clarified that inoculation with *M. bovis* into the stifle joint induced the production of inflammatory cytokines by synovial fluid cells and synovial tissues, causing a severe inflammatory response in joints. Additionally, *M. bovis* could invade cells in synovial tissues, which may have aided it in evading antibiotics and host immune surveillance.

出典　doi: 10.1016/j.vetimm.2021.110364.
https://doi.org/10.1016/j.vetimm.2021.110364

最終責任者　Satoshi Gondaira and Hidetoshi Higuchi (Corresponding Author)

The Journal of Veterinary Medical Science

NOTE

Internal Medicine

Inflammatory cytokine mRNA and protein levels in the synovial fluid of *Mycoplasma* arthritis calves

Koji NISHI[1)], Satoshi GONDAIRA[1)], Mariko OKAMOTO[1,4)], Kazuya MATSUDA[2)], Ayano SATO[3)], Toshihide KATO[3)], Misawo SASAGAWA[1)], Takahiro TANAKA[1)] and Hidetoshi HIGUCHI[1)]*

[1)]Animal Health Laboratory, Department of Veterinary Science, School of Veterinary Medicine, Rakuno Gakuen University, Ebetsu, Hokkaido 069-8501, Japan
[2)]Department of Veterinary Pathology, Department of Veterinary Science, School of Veterinary Medicine, Rakuno Gakuen University, Ebetsu, Hokkaido 069-8501, Japan
[3)]Large Animal Clinical Science, Department of Veterinary Science, School of Veterinary Medicine, Rakuno Gakuen University, Ebetsu, Hokkaido 069-8501, Japan
[4)]Present address: Division of Bacterial and Parasitic Disease, National Institute of Animal Health, National Agriculture and Food Research Organization, Tsukuba, Ibaraki 305-0856, Japan

J. Vet. Med. Sci.
83(1): 31–35, 2021
doi: 10.1292/jvms.20-0491

Received: 19 August 2020
Accepted: 4 November 2020
Advanced Epub:
8 January 2021

ABSTRACT. Bovine *Mycoplasma* arthritis (MA) is caused by *Mycoplasma bovis* and exhibits severe clinical symptoms. However, the pathophysiology of bovine MA is incompletely understood. In this study, we examined the cytokine mRNA expression of synovial fluid (SF) cells and cytokine concentrations in the SF of MA calves. The SF was isolated from five clinically healthy (control) and seven MA calves. mRNA and protein levels of interleukin (IL)-1β, IL-6, IL-8, IL-12, and IL-17 in the SF from MA calves were significantly higher than those from control calves. Our results indicate that SF cells produce inflammatory cytokines, which mainly contribute to the severe inflammatory response in the joints of the MA calves.

KEY WORDS: bovine bacterial arthritis, inflammatory cytokine, *Mycoplasma* arthritis, *Mycoplasma bovis*, synovial fluid

出典　doi: 10.1292/jvms.20-0491
https://www.jstage.jst.go.jp/article/jvms/83/1/83_20-0491/_article
最終責任者　Hidetoshi Higuchi (Corresponding Author)

The Journal of Veterinary Medical Science

FULL PAPER
Immunology

Somatic cell and innate immune responses in mammary glands of lactating cows to intramammary infusion of *Bifidobacterium breve* at pre-drying off period

Hajime NAGAHATA[1)]*, Mari KINE[2)], Hisato WATANABE[2)], Ai TANAKA[2)], Aoi TAKAHASHI[2)], Satoshi GONDAIRA[2)] and Hidetoshi HIGUCHI[2)]

[1)]Department of Veterinary Associated Science, Faculty of Veterinary Medicine, Okayama University of Science, Ikoinooka 1-3, Imabari, Ehime 794-8555, Japan
[2)]Animal Health Unit, Department of Health and Environmental Sciences, School of Veterinary Medicine, Rakuno Gakuen University, Bunkyodai-Midori 582, Ebetsu, Hokkaido 069-8501, Japan

ABSTRACT. Intramammary infusion of *Bifidobacterium breve (B. breve)*-induced somatic cell (SC) counts, chemiluminescent response (CL), lactoferrin (LF) concentrations and mastitis-causing pathogens from quarters with subclinical mastitis were measured to evaluate innate immune response of mammary glands in dairy cows at 3 to 4 weeks before drying off. SC counts in 7 quarters of 7 control cows and 5 quarters of 6 cows with mastitis increased markedly on day 1 and SC values in control cows were significantly ($P<0.05$) increased and returned to pre-infusion levels on day 5 after *B. breve*-infusion. CL values in both groups increased markedly on day 1 and then decreased after *B. breve*-infusion; however, CL values in cows with mastitis did not return to normal levels on day 5 and at postpartum. The CL values were highly correlated with their SC counts in milk from both groups. LF concentrations increased toward day 3 after *B. breve*-infusion and were higher in cows with mastitis. *B. breve*-infusion eliminated 16.6% (1/6) of pathogens from 6 quarters with chronic subclinical mastitis. *B. breve*-induced SC responses in quarters from 3 cows with mastitis showed characteristic patterns of recovery, persistent and new infections. *B. breve*-induced SC counts in quarters from the cows in the pre-drying off were lower (25.7–70.6%) than those of the cows in mid-lactation. The intrinsic innate immune response in cows on pre-drying off may be decreased and appears to be insufficient to eliminate pathogens from mammary gland in the pre-drying off.

KEY WORDS: *Bifidobacterium breve*, innate immune response, lactating cows, mammary gland, pre-drying off

J. Vet. Med. Sci.
83(12): 1845–1851, 2021
doi: 10.1292/jvms.21-0306

Received: 31 May 2021
Accepted: 2 October 2021
Advanced Epub:
14 October 2021

出典　doi: 10.1292/jvms.21-0306
https://www.jstage.jst.go.jp/article/jvms/83/12/83_21-0306/_article
最終責任者　Hajime Nagahata (First Author and Corresponding Author)

Contents lists available at ScienceDirect

Virus Research

journal homepage: www.elsevier.com/locate/virusres

Fluctuating Bacteriophage-induced *galU* Deficiency Region is Involved in Trade-off Effects on the Phage and Fluoroquinolone Sensitivity in *Pseudomonas aeruginosa*

Keisuke Nakamura [a, #], Jumpei Fujiki [a, #, *], Tomohiro Nakamura [a], Takaaki Furusawa [a], Satoshi Gondaira [b], Masaru Usui [c], Hidetoshi Higuchi [b], Yutaka Tamura [c], Hidetomo Iwano [a]

[a] Laboratory of Veterinary Biochemistry, Department of Veterinary Medicine, Rakuno Gakuen University, Ebetsu, Hokkaido, Japan
[b] Laboratory of Animal Health, Rakuno Gakuen University School of Veterinary Medicine, Ebetsu, Hokkaido, Japan
[c] Laboratory of Food Microbiology and Food Safety, Rakuno Gakuen University School of Veterinary Medicine, Ebetsu, Hokkaido, Japan

ARTICLE INFO

Keywords:
Bacteriophage
galU
Pseudomonas aeruginosa
Phage resistance
Phage therapy
Trade-off
Fitness cost

ABSTRACT

Pseudomonas aeruginosa, which causes chronic infections, has demonstrated rapid acquisition of antimicrobial resistance (AMR). Therefore, bacteriophages have received significant attention as promising antimicrobial agents; however, previous trials have reported the occurrence of phage-resistant variants. *P. aeruginosa* has lost large chromosomal fragments via evolutionary selection by MutL. Mutants lacking *galU* and *hmgA*, located in close proximity, exhibit phage resistance and brown color phenotype since *hmgA* encodes a homogentisic acid metabolic enzyme and deletion of *galU* results in a lack of O-antigen polysaccharide and absence of the phage receptor. In the present study, we evaluated this mechanism for controlling phage resistance in *P. aeruginosa* veterinary isolate Pa12. Phage-resistant Pa12 brown mutants (brmts) with *galU* and *hmgA* deletions were isolated. Whole-genome sequencing of the brmts revealed that regions 148-27 kbp upstream and 261-110 kbp downstream of *galU* were largely deleted from the Pa12 parental chromosome. Furthermore, all of these fluctuating deleted sequences in Pa12 brmts, tentatively designated bacteriophage-induced *galU* deficiency (BigD) regions, harbor multi-drug efflux system genes (*mexXY*). Minimum inhibitory concentration (MIC) assays demonstrated that brmts altered sensitivity to antibiotics and exhibited increased levofloxacin sensitivity compared with the Pa12 parent. Orbifloxacin and enrofloxacin also effectively suppressed growth of the Pa12 brmts, suggesting that MexXY, which mediates quinolone efflux and is located in the BigD region, might be associated with restoration of fluoroquinolone sensitivity. Our findings indicate that AMR-related genes in the BigD region could produce trade-off effects between phages and drug sensitivity and thereby contribute to a potential strategy to control and prevent phage-resistant variants in phage therapy.

出典　doi: 10.1016/j.virusres.2021.198596
https://www.sciencedirect.com/science/article/pii/S0168170221003038?via%3Dihub

最終責任者　Jumpei Fujiki (Corresponding Author)

AMERICAN SOCIETY FOR MICROBIOLOGY | Microbiology Resource Announcements
GENOME SEQUENCES
July 2021 Volume 10 Issue 26 e00398-21
https://doi.org/10.1128/MRA.00398-21

Complete Genome Sequence of a Veterinary *Pseudomonas aeruginosa* Isolate, Pa12

Keisuke Nakamura[a], Jumpei Fujiki [a], Takaaki Furusawa[a], Tomohiro Nakamura[a], Satoshi Gondaira[b], Michihito Sasaki [c], Masaru Usui[d], Hidetoshi Higuchi[b], Hirofumi Sawa[c,e], Yutaka Tamura[d,f], and Hidetomo Iwano[a]

[a]Laboratory of Veterinary Biochemistry, Rakuno Gakuen University School of Veterinary Medicine, Ebetsu, Japan
[b]Laboratory of Animal Health, Rakuno Gakuen University School of Veterinary Medicine, Ebetsu, Japan
[c]Division of Molecular Pathobiology, International Institute for Zoonosis Control, Hokkaido University, Sapporo, Japan
[d]Laboratory of Food Microbiology and Food Safety, Rakuno Gakuen University School of Veterinary Medicine, Ebetsu, Japan
[e]International Collaboration Unit, International Institute for Zoonosis Control, Hokkaido University, Sapporo, Japan
[f]Center for Veterinary Drug Development, Rakuno Gakuen University, Ebetsu, Japan

ABSTRACT *Pseudomonas aeruginosa* causes various opportunistic infections in animals. Here, we report the complete genome sequence of *P. aeruginosa* strain Pa12, a fluoroquinolone-resistant isolate from a canine skin lesion. To expand the molecular antimicrobial characteristics of the isolate, the whole Pa12 genome was sequenced and assembled via long- and short-read platforms.

出典　doi: 10.1128/MRA.00398-21
https://journals.asm.org/doi/10.1128/MRA.00398-21
最終責任者　Jumpei Fujiki (Corresponding Author)

獣医病理学（Veterinary Pathology）

Yuto Sano

Lecturer

講師　佐野　悠人

Ⅰ．筆頭または責任著者　＜First or Corresponding Author＞

1) Medaistinal basaloid carcinoma arising from thymic cysts in two dogs.
Sano Y, Seki K, Miyoshi K, Sakai T, Kadosawa T, Matsuda K.
J. Vet. Med. Sci. 83:876-880. 2021. 10.1292/jvms.20-0518

2) A bronchopulmonary artery fistula in a horse.
Sano Y, Kuwajima H, Kanai H, Baba C, Azami K, Matsuda K.
J. Vet. Med. Sci. 83:1225-1228. 2021. 10.1292/jvms.21-0221

Ⅱ．その他＜Others＞

The Journal of Veterinary Medical Science

NOTE

Pathology

Mediastinal basaloid carcinoma arising from thymic cysts in two dogs

Yuto SANO[1)]*, Kanae SEKI[1)], Kenjirou MIYOSHI[2)], Toshikazu SAKAI[2)], Tsuyoshi KADOSAWA[2)] and Kazuya MATSUDA[1)]

[1)]Department of Veterinary Pathology, School of Veterinary Medicine, Rakuno Gakuen University, Ebetsu, Hokkaido 069-8501, Japan

[2)]Department of Small Animal Clinical Sciences, School of Veterinary Medicine, Rakuno Gakuen University, Ebetsu, Hokkaido 069-8501, Japan

J. Vet. Med. Sci.
83(5): 876–880, 2021
doi: 10.1292/jvms.20-0518

Received: 1 September 2020
Accepted: 24 March 2021
Advanced Epub:
5 April 2021

ABSTRACT. Mediastinal masses in dogs were diagnosed as basaloid carcinoma associated with multiple thymic cysts (MTCs). The masses were composed of MTCs and proliferating intracystic neoplastic basaloid cells, which immunohistochemically diffusely expressed p63 and cytokeratin 19. A gradual transition from the basal cell layers lining the cysts walls to the neoplastic cells was seen, and it was indicated that the neoplastic cells had originated from the basal cell layers of the cysts. To the best of our knowledge, this is the first report of basaloid carcinoma occurring in the mediastinal cavity in dogs. Although these tumors were demonstrated to be rare origins, basaloid carcinoma should be included in the differential diagnoses for canine mediastinal tumors.

KEY WORDS: basaloid carcinoma, dog, mediastinum, thymic branchial cyst, thymic cyst

出典　doi: 10.1292/jvms.20-0518
https://www.jstage.jst.go.jp/article/jvms/83/5/83_20-0518/_pdf/-char/en

最終責任者　Yuto Sano (First Author and Corresponding Author)

The Journal of Veterinary Medical Science

NOTE

Pathology

A bronchopulmonary artery fistula in a horse

Yuto SANO[1)]*, Hikaru KUWAJIMA[1)], Hiroki KANAI[1)], Chiemi BABA[1)], Kohei AZAMI[1)] and Kazuya MATSUDA[1)]

[1)]Department of Veterinary Pathology, School of Veterinary Medicine, Rakuno Gakuen University, Ebetsu, Hokkaido 069-8501, Japan

J. Vet. Med. Sci.
83(8): 1225–1228, 2021
doi: 10.1292/jvms.21-0221

Received: 11 April 2021
Accepted: 24 May 2021
Advanced Epub:
10 June 2021

ABSTRACT. A 24-year-old, Thoroughbred gelding presented with difficulty breathing for a few days and intermittent nose bleeding before dying. At necropsy, the bronchoesophageal artery and the bronchial artery that flowed into the left anterior lobe were tortuous and dilated, and it was found that dilated tortuous branches of the bronchial artery ran over the dorsal and ventral surfaces of the left anterior lobe. Histopathologically, an anastomosis between a muscular artery and an elastic artery were demonstrated, which were identified as bronchial and pulmonary arteries, respectively. Based on the gross and histopathological findings, a bronchopulmonary artery fistula was diagnosed. To the best of our knowledge, this is the first case report of a pulmonary vascular anastomosis in a horse.

KEY WORDS: anastomosis, bronchial artery, horse, lung, pulmonary artery

出典　doi: 10.1292/jvms.21-0221
https://www.jstage.jst.go.jp/article/jvms/83/8/83_21-0221/_pdf/-char/en

最終責任者　Yuto Sano (First Author and Corresponding Author

The Journal of Veterinary Medical Science

NOTE

Pathology

Peritoneal sarcomatoid mesothelioma in a sika deer

Kazuya MATSUDA[1)]*, Shun KOGAME[1)], Rina YAEGASHI[1)] and Yuto SANO[1)]

[1)]Department of Veterinary Pathology, School of Veterinary Medicine, Rakuno Gakuen University, Ebetsu, Hokkaido 069-8501, Japan

J. Vet. Med. Sci.
81(10): 1504–1508, 2019
doi: 10.1292/jvms.19-0345

Received: 24 June 2019
Accepted: 8 August 2019
Advanced Epub:
15 August 2019

ABSTRACT. A slaughtered 2-year-old female sika deer (*Cervus nippon yesoensis*) had diffusely distributed multinodular lesions on the serosal surface of the peritoneal cavity and several nodules in the pleural cavity. Histologically, they were composed of proliferating spindle-shaped neoplastic cells, arranged in a fascicular fashion. The cells in the invasive foci transitioned from a sarcomatoid to an epithelioid appearance. Immunohistochemically, both the spindle-shaped and epithelioid cells were at least focally positive for pancytokeratin, vimentin, calretinin, α-SMA, and desmin. From these findings, the deer was diagnosed with peritoneal sarcomatoid mesothelioma with metastasis to the pleural cavity. To our knowledge, this is the first reported case of peritoneal mesothelioma in a cervid species and the first case of mesothelioma in a sika deer.

KEY WORDS: *Cervus nippon yesoensis*, neoplasm, peritoneal cavity, sarcomatoid mesothelioma, sika deer

出典　doi: 10.1292/jvms.19-0345
https://www.jstage.jst.go.jp/article/jvms/81/10/81_19-0345/_pdf/-char/en

最終責任者　Kazuya Matsuda (First Author and Corresponding Author)

画像診断学（Veterinary Diagnostic Imaging）

Kiwamu Hanazono

Senior lecture

講師　華園　究

Ⅰ．筆頭または責任著者　＜First or Corresponding Author＞

1) Prognostic role of ΔNp63 expression in canine transitional cell carcinoma of the urinary bladder.
Nishimori T, **Hanazono K**, Matsuda K, Kawamura Y, Kadosawa T, Endo Y, Uchide T. 2021.
Open. Vet. J. 11: 700–706. 2021. doi: 10.5455/OVJ.2021.v11.i4.22

2) The effects of gel pad thickness on the evaluation of skin structures using ultrasonography in normal dogs.
Chhay S, **Hanazono K**, Kitahara J, Hori A, Miyoshi K, Itami T, Endoh D, Nakade T.
J. Vet. Med. Sci. 83:1472-1475. 2021 doi: 10.1292/jvms.21-0086.

3) Effects of gel pad thickness on skin stiffness evaluation by ultrasonographic strain elastography in normal dogs.
Chhay S, **Hanazono K**, Kitahara J, Hori A, Miyoshi K, Itami T, Endoh D, Nakade T.
Jpn. J. Vet. Res. 69: 125-139. 2021. doi: 10.14943/jjvr.69.2.125

Ⅱ．その他＜Others＞

1) Prediction of PCR amplification from primer and template sequences using recurrent neural network.
Kayama K, Kanno M, Chisaki N, Tanaka M, Yao R, **Hanazono K**, Camer GA, Endoh D.
Sci. Rep. 11:7493. 2021. doi: 10.1038/s41598-021-86357-1.

Open Veterinary Journal, (2021), Vol. 11(4): 700–706
ISSN: 2226-4485 (Print)
ISSN: 2218-6050 (Online)
Original Research
DOI: *10.5455/OVJ.2021.v11.i4.22*

Submitted: 06/06/2021 Accepted: 19/11/2021 Published: 15/12/2021

Prognostic role of ΔNp63 expression in canine transitional cell carcinoma of the urinary bladder

Tomohiro Nishimori[1], Kiwamu Hanazono[1*], Kazuya Matsuda[1], Yoshio Kawamura[1], Tsuyoshi Kadosawa[1], Yoshifumi Endo[1] and Tsuyoshi Uchide[2]

[1]*School of Veterinary Medicine, Rakuno Gakuen University, Ebetsu, Japan*
[2]*Laboratory of Veterinary Molecular Pathology and Therapeutics, Tokyo University of Agriculture and Technology, Fuchu, Japan*

Abstract

Background: Decreased p63 protein expression in canine transitional cell carcinoma (TCC) of the urinary bladder is associated with vascular invasion of the tumor, metastasis, and shortened survival. ΔNp63, an isoform of p63, is downregulated in high-grade invasive urothelial carcinoma in humans. However, the clinical significance of ΔNp63 expression in canine urinary bladder tumors is unknown. Therefore, it is essential to investigate ΔNp63 expression patterns in TCC, the most common urinary bladder tumor in dogs.

Aim: This study aimed to evaluate the expression and role of ΔNp63 in canine TCC of the urinary bladder.

Methods: ΔNp63 expression was compared between the normal canine urinary bladder, polypoid cystitis, and TCC. The correlation of ΔNp63 expression with histopathological and clinical findings were further evaluated, and its usefulness as a prognostic factor was examined.

Results: We observed that ΔNp63 was highly expressed in dogs' normal urinary bladder and polypoid cystitis, and its expression levels were low in TCC. Furthermore, low levels of ΔNp63 expression were associated with vascular invasion, metastasis, and shortened survival in dogs with TCC.

Conclusion: These results indicate that ΔNp63 expression could serve as a valuable biomarker for invasion, metastasis, and prognosis of canine TCC of the urinary bladder.

Keywords: ΔNp63, Metastasis, Survival, Transitional cell carcinoma, Urinary bladder.

出典　doi: 10.5455/OVJ.2021.v11.i4.22

https://www.openveterinaryjournal.com/volume-11-no-4-2021

最終責任者　Kiwamu Hanazono (Corresponding Author)

The Journal of Veterinary Medical Science

NOTE

Internal Medicine

The effects of gel pad thickness on the evaluation of skin structures using ultrasonography in normal dogs

Sothavy CHHAY[1)], Kiwamu HANAZONO[1,2)]*, Jo KITAHARA[1)], Ai HORI[2)], Kenjiro MIYOSHI[1,2)], Takaharu ITAMI[1,2)], Daiji ENDOH[1)] and Tetsuya NAKADE[1,2)]

[1)]School of Veterinary Medicine, Rakuno Gakuen University, 582 Bunkyodai Midorimach, Ebetsu, Hokkaido 069-8501, Japan

[2)]Animal Medical Center, Rakuno Gakuen University, 582 Bunkyodai Midorimach, Ebetsu, Hokkaido 069-8501, Japan

J. Vet. Med. Sci.
83(9): 1472–1475, 2021
doi: 10.1292/jvms.21-0086

Received: 15 February 2021
Accepted: 14 July 2021
Advanced Epub:
26 July 2021

ABSTRACT. Gel pads are commonly used in skin ultrasonography; however, the effects of their thickness are unknown. This study investigated the effects of pad thickness on measurements of skin thickness in 10 beagle dogs. Sonograms to measure neck skin thickness were captured without pads and using pads with thicknesses of 3, 5, 10, and 20 mm. Without pads, acoustic shading was observed due to air bubbles in the coupling gel. With 20-mm pads, echogenic artifacts were observed on the skin surface. Entry echo with 20-mm pads was significantly higher than with 3-mm pads. This suggests that visibility of the skin structure could be affected when a gel pad is not used or when a thick gel pad is selected.

KEY WORDS: artifact, gel pad, normal dog, skin thickness, skin ultrasonography

出典　doi: 10.1292/jvms.21-0086.
https://www.ncbi.nlm.nih.gov/pmc/articles/PMC8498840/pdf/jvms-83-1472.pdf

最終責任者　Kiwamu Hanazono (Corresponding Author)

Japanese Journal of Veterinary Research 69(2): 125-134, 2021

JJVR

REGULAR PAPER Experimental Research

Effects of gel pad thickness on skin stiffness evaluation by ultrasonographic strain elastography in normal dogs

Sothavy Chhay[1)], Kiwamu Hanazono[2,3,*)], Jo Kitahara[1)], Ai Hori[3)], Kenjiro Miyoshi[1,3)], Takaharu Itami[1,3)], Daiji Endoh[2)] and Tetsuya Nakade[1,3)]

[1)] Department of Small Animal Clinical Sciences, School of Veterinary Medicine, Rakuno Gakuen University, 582 Bunkyodai Midorimach, Ebetu-shi, Hokkaido 069-8501, Japan
[2)] Department of Biosciences, School of Veterinary Medicine, Rakuno Gakuen University, Ebetsu, Hokkaido 069-8501, Japan
[3)] Animal Medical Center, Rakuno Gakuen University, 582 Bunkyodai Midorimach, Ebetu-shi, Hokkaido 069-8501, Japan

Received for publication, November 8, 2020; accepted, February 25, 2021

Abstract

Gel pads are commonly used for skin ultrasound examination; however, the effect of their thickness on the measured values is unknown. We investigated the effect of pad thickness on skin stiffness measurement in healthy dogs. The skin stiffness of the dorsal neck was measured using a durometer. Ultrasonographic strain elastography was performed with 5-, 10-, and 20-mm-thick pads. Among the strain ratios, muscle/skin (5 mm) showed a significantly positive correlation with skin stiffness. In the strain histogram, AREA (20 mm), CONTRAST (20 mm), MEAN (5, 20 mm), and STANDARD DEVIATION (20 mm) were significantly correlated with skin stiffness. In conclusion, the thickness of the gel pad affects the measurements during skin ultrasonographic strain elastography.

Key Words: Gel pad, normal dog, skin ultrasonography, ultrasonographic strain elastography

出典 doi: 10.14943/jjvr.69.2.125
https://eprints.lib.hokudai.ac.jp/dspace/bitstream/2115/81817/1/JJVR69-2_125-134_SothavyChhay.pdf

最終責任者 Kiwamu Hanazono (Corresponding Author)

scientific reports

Check for updates

OPEN

Prediction of PCR amplification from primer and template sequences using recurrent neural network

Kotetsu Kayama[1], Miyuki Kanno[1], Naoto Chisaki[1], Misaki Tanaka[1], Reika Yao[1], Kiwamu Hanazono[1], Gerry Amor Camer[1,2] & Daiji Endoh[1]✉

We have developed a novel method to predict the success of PCR amplification for a specific primer set and DNA template based on the relationship between the primer sequence and the template. To perform the prediction using a recurrent neural network, the usual double-stranded formation between the primer and template nucleotide sequences was herein expressed as a five-lettered word. The set of words (pseudo-sentences) was placed to indicate the success or failure of PCR targeted to learn recurrent neural network (RNN). After learning pseudo-sentences, RNN predicted PCR results from pseudo-sentences which were created by primer and template sequences with 70% accuracy. These results suggest that PCR results could be predicted using learned RNN and the trained RNN could be used as a replacement for preliminary PCR experimentation. This is the first report which utilized the application of neural network for primer design and prediction of PCR results.

出典　2021. doi: 10.1038/s41598-021-86357-1.
https://www.nature.com/articles/s41598-021-86357-1.pdf

最終責任者　Daiji Endoh (Corresponding Author)

食品衛生学 (Food Microbiology and Food Safety)

Akira Fukuda

Lecture

講師　福田　昭

Ⅰ．筆頭または責任著者　＜First or Corresponding Author＞

1) Seven-year surveillance of the prevalence of antimicrobial-resistant *Escherichia coli* isolates, with a focus on ST131 clones, among healthy people in Osaka, Japan.
Fukuda A, Nakamura H, Umeda K, Yamamoto K, Hirai Y, Usui M, Ogasawara J.
International Journal of Antimicrobial Agents 57:106298. 2021.
doi: 10.1016/j.ijantimicag.2021.106298.
2) Prevalence of antimicrobial-resistant *Escherichia coli* in the migratory bird (*Anser albifrons*) and their habitat in Miyajimanuma, Japan.
Fukuda A, Usui M, Ushiyama K, Shrestha D, Hashimoto N, Sakata M, Minamoto T, Yoshida O, Murakami K, Tamura Y, Asai T. 2021.
Journal of Wildlife Diseases 57:954-958. doi: 10.7589/JWD-D-21-00006.

Ⅱ．その他＜Others＞

1) Evaluation of nosocomial infections through contact patterns in a small animal hospital using social network analysis and genotyping techniques.
Churak A, Poolkhet C, Tamura Y, Sato T, **Fukuda A**, Thongratsakul S.
Scientific Reports 11:1647. doi: 10.1038/s41598-021-81301-9. 2021.
2) Genomic characterization of clinical *Enterobacter roggenkampii* co-harboring bla_{IMP-1}- and bla_{GES-5}-encoding IncP6 and *mcr-9*-encoding IncHI2 plasmids isolated in Japan.
Umeda K, Nakamura H, **Fukuda A**, Matsumoto Y, Motooka D, Nakamura S, Yasui Y, Yoshida H, Kawahara R.
Journal of Global Antimicrobial Resistance 24:220-227. 2021.
doi: 10.1016/j.jgar.2020.11.028.
3) Decreased colistin resistance and *mcr-1* prevalence in pig-derived *Escherichia*

coli in Japan after banning colistin as a feed additive.
Usui M, Nozawa Y, **Fukuda A**, Sato T, Yamada M, Makita K, Tamura Y.
Journal of Global Antimicrobial Resistance 24:383-386.
doi: 10.1016/j.jgar.2021.01.016.

4) Genetic characterization of coliform bacterial isolates from environmental water in Thailand.
Tsunoda R, Usui M, Tagaki C, **Fukuda A**, Boonla C, Anomasiri W, Sukpanyatham N, Akapelwa AL, Nakajima C, Tamura Y, Suzuki Y.
Journal of Infection and Chemotherapy 27:722-728. 2021.
doi: 10.1016/j.jiac.2020.12.023.

5) Aerobic composting and anaerobic digestion decrease the copy numbers of antibiotic-resistant genes and the levels of lactose-degrading *Enterobacteriaceae* in dairy farms in Hokkaido, Japan.
Katada S, **Fukuda A**, Nakajima C, Suzuki Y, Azuma T, Takei A, Takada H, Okamoto E, Kato T, Tamura Y, Usui M.
Frontiers in Microbiology 12:737420. 2021. doi: 10.3389/fmicb.2021.737420.

6) Broad-host-range IncW plasmid harbouring *tet(X)* in *Escherichia coli* isolated from pigs in Japan.
Usui M, **Fukuda A**, Suzuki Y, Nakajima C, Tamura Y.
Journal of Global Antimicrobial Resistance in press. 2021.
doi: 10.1016/j.jgar.2021.12.012

International Journal of Antimicrobial Agents 57 (2021) 106298

Contents lists available at ScienceDirect

International Journal of Antimicrobial Agents

journal homepage: www.elsevier.com/locate/ijantimicag

Short Communication

Seven-year surveillance of the prevalence of antimicrobial-resistant *Escherichia coli* isolates, with a focus on ST131 clones, among healthy people in Osaka, Japan

Akira Fukuda[a,*], Hiromi Nakamura[b], Kaoru Umeda[b], Kaori Yamamoto[b], Yuji Hirai[b], Masaru Usui[a], Jun Ogasawara[b]

[a] *Laboratory of Food Microbiology and Food Safety, Department of Health and Environmental Sciences, School of Veterinary Medicine, Rakuno Gakuen University, Ebetsu, Japan*
[b] *Division of Microbiology, Osaka Institute of Public Health, Osaka, Japan*

ARTICLE INFO

Article history:
Received 21 August 2020
Accepted 30 January 2021

Editor: Professor A Tsakris

Keywords:
Surveillance
ST131
Escherichia coli
bla gene
mcr gene

ABSTRACT

Objectives: *Escherichia coli* (*E. coli*) is an indicator of antimicrobial resistance, and some strains of *E. coli* cause infectious diseases. *E. coli* sequence type 131 (ST131) – a global antimicrobial-resistant pandemic *E. coli* clone – is frequently detected in clinical specimens. Antimicrobial-resistant bacteria are monitored via national surveillance in clinical settings; however, monitoring information in non-clinical settings is limited. This study elucidated antimicrobial resistance trends of *E. coli* and dissemination of ST131 among healthy people in non-clinical settings.

Methods: This study collected 517 *E. coli* isolates from healthy people in Osaka, Japan, between 2013 and 2019. It analysed antimicrobial susceptibility of the isolates and detected the *bla* and *mcr* genes in ampicillin-resistant and colistin-resistant isolates, respectively, and the ST131 clone.

Results: Antimicrobial resistance rates of the bacteria isolated from healthy people in non-clinical settings were lower than for those in clinical settings. The resistance of the isolates to cefotaxime (4.4%) and ciprofloxacin (13.5%) gradually increased during the study period. In 23 cefotaxime-resistant isolates, the most frequent *bla* genes belonged to the $bla_{CTX\text{-}M\text{-}9}$ group, followed by $bla_{CTX\text{-}M\text{-}1}$ goup, bla_{TEM} and $bla_{CMY\text{-}2}$. One *mcr-1*-harbouring colistin-resistant isolate was detected in 2016. The incidence of the *E. coli* O25b-ST131 clone was approximately 5% until 2015 and 10% after 2016.

Conclusion: Both ciprofloxacin resistance and O25b-ST131 clone frequency increased during the study period. Antimicrobial-resistant bacteria gradually spread in healthy people in non-clinical settings; one reason behind this spread was dissemination of global antimicrobial-resistant pandemic clones.

© 2021 Elsevier Ltd and International Society of Antimicrobial Chemotherapy. All rights reserved.

出典　doi: 10.1016/j.ijantimicag.2021.106298.
https://doi.org/10.1016/j.ijantimicag.2021.106298

最終責任者　Akira Fukuda (First Author and Corresponding Author)

SHORT COMMUNICATIONS

DOI: 10.7589/JWD-D-21-00006 *Journal of Wildlife Diseases*, 57(4), 2021, pp. 000–000
© Wildlife Disease Association 2021

Prevalence of antimicrobial-resistant *Escherichia coli* in migratory Greater White-fronted Goose (*Anser albifrons*) and their habitat in Miyajimanuma, Japan

Akira Fukuda,[1] Masaru Usui,[1,8] Katsumi Ushiyama,[2] Dipti Shrestha,[3] Nagisa Hashimoto,[4] Masayuki K. Sakata,[5] Toshifumi Minamoto,[5] Osamu Yoshida,[6] Kanako Murakami,[1] Yutaka Tamura,[1] and Tetsuo Asai[7] [1]Laboratory of Food Microbiology and Food Safety, School of Veterinary Medicine, Rakuno Gakuen University, Ebetsu 069-8501, Japan; [2]Miyajimanuma Waterbird and Wetland Center, Oomagari 3, Nishibibai, Bibai 072-0057, Japan; [3]Division of Bioresources, Hokkaido University Research Center for Zoonosis Control, Kita 20, Nishi 10, Kita-ku, Sapporo 001-0020, Japan; [4]Faculty of Global Human Sciences, Kobe University, 3-11, Tsurukabuto, Nada-ku, Kobe, Hyogo 657-8501, Japan; [5]Graduate School of Human Development and Environment, Kobe University, 3-11, Tsurukabuto, Nada-ku, Kobe, Hyogo 657-8501, Japan; [6]Laboratory of Environmental Geochemistry, College of Agriculture, Food and Environment Sciences, Rakuno Gakuen University, Ebetsu 069-8501, Japan; [7]Department of Applied Veterinary Science, The United Graduated School of Veterinary Science, Gifu University, Yanagido Post 501-1193, Japan; [8]Corresponding author (email: usuima@rakuno.ac.jp)

ABSTRACT: The spread of antimicrobial-resistant bacteria (ARB) in natural environments including wild animals is a concern for public health. Birds cover large areas, and some fly across borders to migrate in large flocks. As a migratory bird, the Greater White-fronted Goose (*Anser albifrons*) travels to Miyajimanuma, North Japan, each spring and autumn. To investigate the ARB in migratory birds and their surroundings, we collected 110 fecal samples of *A. albifrons* and 18 water samples from Miyajimanuma in spring and autumn of 2019. Isolation of *Escherichia coli* was performed using selective agars with or without antimicrobials (cefazolin and nalidixic acid). Isolates of *E. coli* were recovered from 56 fecal samples (50.9%) and five water samples (27.8%) on agars without antimicrobials. No isolates were recovered on agars with antimicrobials. One *E. coli* isolate derived from a fecal sample exhibited resistance to β-lactams (ampicillin and cefazolin), whereas all other isolates exhibited susceptibility to all tested antimicrobials. The resistant isolate harbored bla_{ACC}, which could be transferred to other bacteria and confer resistance to β-lactams. These results suggest a low prevalence of antimicrobial resistance in wild migratory birds and their living environments; however, wild migratory birds sometimes carry ARB harboring transferrable antimicrobial resistance genes and therefore present a risk of spreading antimicrobial resistance.

Key Words: Antimicrobial resistance, eDNA, *Escherichia coli*, migratory bird, transferrable element.

veterinary clinical settings. These settings are thought to be hot spots of ARB, causing the spread to surroundings (Guenther et al. 2011). Surveillance of ARB is conducted in clinical settings; however, ARB in natural environments and wild animals are not surveyed sufficiently because of a wide variety of species and ecologies (Ramey and Ahlstrom 2020).

As an indicator bacterium of antimicrobial resistance (AMR) in warm-blooded animals, *Escherichia coli* is commonly used in national surveillance of clinical settings and research on wild animals (Berendonk et al. 2015; Asai et al. 2020). Moreover, *E. coli* is regarded as the indicator bacteria of fecal contamination from humans and animals in environments (Sen et al. 2019). Thus, *E. coli* is considered an appropriate indicator to estimate the prevalence of AMR derived from local humans and animals in various environments.

Environmental DNA (eDNA) is derived from organisms living there and is used to detect the presence of macro-organisms (Sakata et al. 2020). In aquatic ecosystems, detecting the presence of animals is possible regardless of species, because animals generally need frequent opportunities to come in contact with water (Ushio et al. 2018).

出典　doi: 10.7589/JWD-D-21-00006.
https://doi.org/10.7589/JWD-D-21-00006
最終責任者　Masaru Usui (Corresponding Author)

scientific reports

Check for updates

OPEN

Evaluation of nosocomial infections through contact patterns in a small animal hospital using social network analysis and genotyping techniques

Amara Churak[1], Chaithep Poolkhet[1], Yutaka Tamura[2], Tomomi Sato[2], Akira Fukuda[2] & Sukanya Thongratsakul[1✉]

Nosocomial infections or hospital-acquired infections (HAIs) are common health problems affecting patients in human and animal hospitals. Herein, we hypothesised that HAIs could be spread through human and animal movement, contact with veterinary medical supplies, equipment, or instruments. We used a combination of social network analysis and genotyping techniques to find key players (or key nodes) and spread patterns using *Escherichia coli* as a marker. This study was implemented in the critical care unit, outpatient department, operation room, and ward of a small animal hospital. We conducted an observational study used for key player determination (or key node identification), then observed the selected key nodes twice with a one-month interval. Next, surface swabs of key nodes and their connecting nodes were analysed using bacterial identification, matrix-assisted laser desorption/ionisation-time of flight mass spectrometry, and pulsed-field gel electrophoresis. Altogether, our results showed that veterinarians were key players in this contact network in all departments. We found two predominant similarity clusters; dendrogram results suggested *E. coli* isolates from different time points and places to be closely related, providing evidence of HAI circulation within and across hospital departments. This study could aid in limiting the spread of HAIs in veterinary and human hospitals.

出典　doi: 10.1038/s41598-021-81301-9.
https://doi.org/10.1038/s41598-021-81301-9

最終責任者　Sukanya Thongratsakul (Corresponding Author)

Journal of Global Antimicrobial Resistance 24 (2021) 220–227

Contents lists available at ScienceDirect

Journal of Global Antimicrobial Resistance

journal homepage: www.elsevier.com/locate/jgar

Genomic characterization of clinical *Enterobacter roggenkampii* co-harbouring bla_{IMP-1}- and bla_{GES-5}-encoding IncP6 and *mcr-9*-encoding IncHI2 plasmids isolated in Japan

Kaoru Umeda[a,*], Hiromi Nakamura[a], Akira Fukuda[a,b], Yuki Matsumoto[c], Daisuke Motooka[c], Shota Nakamura[c], Yoshinori Yasui[d], Hideki Yoshida[e], Ryuji Kawahara[a]

[a] *Division of Microbiology, Osaka Institute of Public Health, 8-34 Tojo-cho, Tennoji-ku, Osaka, Japan*
[b] *Department of Health and Environmental Sciences, School of Veterinary Medicine, Rakuno Gakuen University, 582 Bunkyodai Midorimachi, Ebetsu, Hokkaido, Japan*
[c] *Genome Information Research Center, Research Institute for Microbial Diseases, Osaka University, 3-1 Yamadaoka, Suita, Osaka, Japan*
[d] *Osaka Saiseikai Nakatsu Hospital, 2-10-39 Shibata, Kita-ku, Osaka, Japan*
[e] *Osaka City Public Health Office, 1-2-7-1060 Asahi-cho, Abeno-ku, Osaka, Japan*

ARTICLE INFO

Article history:
Received 11 November 2020
Accepted 29 November 2020
Available online 29 December 2020

Keywords:
Whole-genome sequencing
Carbapenemase-producing *Enterobacterales*
bla_{IMP-1}
bla_{GES-5}
mcr-9
IS26

ABSTRACT

Objectives: The spread of carbapenemase-producing *Enterobacterales* (CPE) with colistin resistance is a critical public health issue. We genetically characterized the clinical isolate *Enterobacter roggenkampii* OIPH-N260, which harboured carbapenemase genes bla_{IMP-1} and bla_{GES-5} with multiple resistance genes, including *mcr-9* and $bla_{CTX-M-9}$.

Methods: This isolate was characterized by whole-genome sequencing, comparative analysis of resistance plasmids, susceptibility tests, bacterial conjugation, S1-nuclease digested pulsed-field-gel electrophoresis, and Southern blot hybridization.

Results: The OIPH-N260 isolate exhibited resistance to most β-lactams and colistin. It co-harboured two resistance plasmids, the bla_{IMP-1}- and bla_{GES-5}-encoding IncP6 plasmid pN260-3 and *mcr-9*- and $bla_{CTX-M-9}$-encoding IncHI2 plasmid pN260-1. The comparative analysis of pN260-3 indicated that a unique bla_{IMP-1}-surrounding region was inserted into the bla_{GES-5}-encoding plasmid with the mobile element IS26, which plays an important role in the spread of resistance genes. pN260-1 did not possess the *mcr-9* expression regulative gene *qseBC*. Both plasmids were transferable into other bacterial species via conjugation.

Conclusions: This is the first study to report not only a bla_{IMP-1} and bla_{GES-5} co-encoding plasmid, but also the co-harbouring of another plasmid carrying *mcr-9* and $bla_{CTX-M-9}$ in *Enterobacter cloacae* complex. The development of advanced resistance via IS26-mediated insertion and the co-harbouring of resistance plasmids highlights the need to monitor for resistance genes in CPE.

© 2021 The Authors. Published by Elsevier Ltd on behalf of International Society for Antimicrobial Chemotherapy. This is an open access article under the CC BY-NC-ND license (http://creativecommons.org/licenses/by-nc-nd/4.0/).

出典　doi: 10.1016/j.jgar.2020.11.028.
https://doi.org/10.1016/j.jgar.2020.11.028

最終責任者　Kaoru Umeda (Corresponding Author)

Journal of Global Antimicrobial Resistance 24 (2021) 383–386

Contents lists available at ScienceDirect

Journal of Global Antimicrobial Resistance

journal homepage: www.elsevier.com/locate/jgar

Decreased colistin resistance and *mcr-1* prevalence in pig-derived *Escherichia coli* in Japan after banning colistin as a feed additive

Masaru Usui[a,*], Yohei Nozawa[a], Akira Fukuda[a], Tomomi Sato[a], Michi Yamada[b], Kohei Makita[c], Yutaka Tamura[a]

[a] *Laboratory of Food Microbiology and Food Safety, Department of Health and Environmental Sciences, School of Veterinary Medicine, Rakuno Gakuen University, Ebetsu, Hokkaido, Japan*
[b] *Department of Sustainable Agriculture, Rakuno Gakuen University, Ebetsu, Hokkaido, Japan*
[c] *Laboratory of Veterinary Epidemiology, Department of Health and Environmental Sciences, School of Veterinary Medicine, Rakuno Gakuen University, Ebetsu, Hokkaido, Japan*

ARTICLE INFO

Article history:
Received 10 August 2020
Received in revised form 20 December 2020
Accepted 23 January 2021
Available online 3 February 2021

Keywords:
Colistin
Feed additive
Pig
Mobilized colistin resistance-1
Antibiotic resistance

ABSTRACT

Background: Antimicrobial resistance to colistin, a widely used feed additive for farm animals across the world, has raised public health concern in recent years. Since July 2018, its use as feed additive has been banned in Japan to reduce the spread of plasmid-based mobilized colistin resistance (*mcr*) genes and the subsequent development of colistin-resistant bacteria. Evaluating the effects of these measures is required.

Methods: We evaluated the effects of colistin use, as a feed additive, on colistin resistance in pigs ($n = 5$) from birth to finishing in the farm. Moreover, to evaluate changes in colistin resistance and *mcr* gene prevalence in response to colistin withdrawal, *E. coli* samples derived from pig faeces sourced from the fields of three geographically distinct farms were characterized before and after the withdrawal of colistin as a feed additive.

Results: Colistin-resistant *Escherichia coli* in pigs ($n = 5$) increased during the colistin administration period and decreased immediately after its end. In three fields, the colistin resistance rate and prevalence of *mcr-1* decreased immediately and significantly after the ban. However, colistin-resistant and *mcr-1*-positive *E. coli* were still detected in all three farm fields 12 months after the ban on colistin use.

Conclusion: Agricultural colistin use caused selective pressure that contributed to widespread *mcr* dissemination in Japan. Colistin resistance and the presence of *mcr* genes should be continuously monitored in food-producing animals.

© 2021 The Author(s). Published by Elsevier Ltd on behalf of International Society for Antimicrobial Chemotherapy. This is an open access article under the CC BY license (http://creativecommons.org/licenses/by/4.0/).

出典　doi: 10.1016/j.jgar.2021.01.016.
https://doi.org/10.1016/j.jgar.2021.01.016

最終責任者　Masaru Usui (Corresponding Author)

J Infect Chemother 27 (2021) 722–728

Contents lists available at ScienceDirect

Journal of Infection and Chemotherapy

journal homepage: http://www.elsevier.com/locate/jic

Original Article

Genetic characterization of coliform bacterial isolates from environmental water in Thailand

Risa Tsunoda [a], Masaru Usui [b, **], Chie Tagaki [b], Akira Fukuda [b], Chanchai Boonla [c], Wilai Anomasiri [c], Nop Sukpanyatham [d], Mwangala Lonah Akapelwa [a], Chie Nakajima [a, e], Yutaka Tamura [b, ***], Yasuhiko Suzuki [a, e, *]

[a] Division of Bioresources, Research Center for Zoonosis Control, Hokkaido University, Sapporo, Japan
[b] Laboratory of Food Microbiology and Food Safety, School of Veterinary Medicine, Rakuno Gakuen University, Ebetsu, Japan
[c] Department of Biochemistry, Chulalongkorn University, Bangkok, Thailand
[d] Quality Vet Product Co., Ltd, Klongsamwa District, Bangkok, Thailand
[e] International Collaboration Unit, Research Center for Zoonosis Control, Hokkaido University, Sapporo, Hokkaido, Japan

ARTICLE INFO

Article history:
Received 2 November 2020
Received in revised form
21 December 2020
Accepted 24 December 2020
Available online 16 January 2021

Keywords:
Enterobacteriaceae
Cefazoline-resistant
IncFrepB plasmid
bla_{TEM}
tetM

ABSTRACT

Introduction: In contrast to the study in other part of the world, information about characteristics of plasmids carrying antimicrobial resistance genes (ARGs) in *Enterobacteriaceae* derived from environmental water in tropical Asian countries including Thailand is limited. This study, therefore, aimed to gain insight into genetic information of antimicrobial resistance in environmental water in Thailand.
Methods: Coliform bacteria were isolated from environmental water collected at 20 locations in Thailand and identified. Then, susceptibility profiles to ampicillin, cefazoline, cefotaxime, kanamycin, ciprofloxacin, sulfamethoxazole, tetracycline, and nalidixic acid were assessed. In addition, antimicrobial resistant genes integrons, and replicon types were analyzed. And furthermore, plasmids carrying bla_{TEM} and *tetM* were identified by S1-PFGE analysis and confirmed transmissibility by transconjugation experiments.
Results: In 130 coliform bacteria isolated, 89 were resistant to cefazoline while 41 isolates were susceptible. Cefazoline-resistant coliform bacteria were found to be significantly resistant to cefotaxime and tetracycline as compared to susceptible isolates. Hence, bla_{TEM} and *tetM* correlating with β-lactam antibiotics and tetracycline, respectively, were analyzed found to co-localize on the IncFrepB plasmids in isolates from pig farms' wastewater by S1-PFGE analysis. And furthermore, transmissibility of the plasmids was confirmed.
Conclusions: Results obtained in this study suggested that ARGs in coliform bacteria may have been spreading on the farm via IncFrepB plasmids. Hence, appropriate use of antimicrobials and good hygiene management on the farm are required to prevent the emergence and spread of resistant bacteria.
© 2021 Japanese Society of Chemotherapy and The Japanese Association for Infectious Diseases. Published by Elsevier Ltd. All rights reserved.

出典　doi: 10.1016/j.jiac.2020.12.023.
https://doi.org/10.1016/j.jiac.2020.12.023
最終責任者　Usui Masaru, Nakajima Chie, Yasuhiko Suzuki Yasuhiko (Corresponding Author)

frontiers in Microbiology

ORIGINAL RESEARCH
published: 30 September 2021
doi: 10.3389/fmicb.2021.737420

Aerobic Composting and Anaerobic Digestion Decrease the Copy Numbers of Antibiotic-Resistant Genes and the Levels of Lactose-Degrading Enterobacteriaceae in Dairy Farms in Hokkaido, Japan

*Satoshi Katada[1], Akira Fukuda[1], Chie Nakajima[2,3], Yasuhiko Suzuki[2,3], Takashi Azuma[4], Ayaka Takei[5], Hideshige Takada[5], Eiryu Okamoto[6], Toshihide Kato[7], Yutaka Tamura[1] and Masaru Usui[1]**

[1] Laboratory of Food Microbiology and Food Safety, School of Veterinary Medicine, Rakuno Gakuen University, Ebetsu, Japan, [2] Division of Bioresources, Hokkaido University Research Center for Zoonosis Control, Sapporo, Japan, [3] International Collaboration Unit, Research Center for Zoonosis Control, Hokkaido University, Sapporo, Japan, [4] Department of Pharmacy, Osaka Medical and Pharmaceutical University, Takatsuki, Japan, [5] Laboratory of Organic Geochemistry, Faculty of Agriculture, Tokyo University of Agriculture and Technology, Fuchu, Japan, [6] Laboratory of Environmental Microbiology, College of Agriculture, Food, and Environment Sciences, Rakuno Gakuen University, Ebetsu, Japan, [7] Department of Large Animal Clinical Sciences, School of Veterinary Medicine, Rakuno Gakuen University, Ebetsu, Japan*

OPEN ACCESS

Edited by:
Krassimira Hristova, Marquette University, United States

Reviewed by:
Rishi Mahajan, Chaudhary Sarwan Kumar Himachal Pradesh Krishi Vishvavidyalaya, India
Terry Gentry, Texas A&M University, United States

***Correspondence:**
Masaru Usui
usuima@rakuno.ac.jp

Specialty section:
This article was submitted to Antimicrobials, Resistance and Chemotherapy, a section of the journal Frontiers in Microbiology

Received: 06 July 2021
Accepted: 03 September 2021
Published: 30 September 2021

Citation:
Katada S, Fukuda A, Nakajima C, Suzuki Y, Azuma T, Takei A, Takada H, Okamoto E, Kato T, Tamura Y and Usui M (2021) Aerobic Composting and Anaerobic Digestion Decrease the Copy Numbers of Antibiotic-Resistant Genes and the Levels of Lactose-Degrading Enterobacteriaceae in Dairy Farms in Hokkaido, Japan. Front. Microbiol. 12:737420. doi: 10.3389/fmicb.2021.737420

Efficient methods for decreasing the spread of antimicrobial resistance genes (ARGs) and transfer of antimicrobial-resistant bacteria (ARB) from livestock manure to humans are urgently needed. Aerobic composting (AC) or anaerobic digestion (AD) are widely used for manure treatment in Japanese dairy farms. To clarify the effects of AC and AD on antimicrobial resistance, the abundances of antimicrobial (tetracycline and cefazolin)-resistant lactose-degrading Enterobacteriaceae as indicator bacteria, copy numbers of ARGs (tetracycline resistance genes and β-lactamase coding genes), and concentrations of residual antimicrobials in dairy cow manure were determined before and after treatment. The concentration of tetracycline/cefazolin-resistant lactose-degrading Enterobacteriaceae was decreased over 1,000-fold by both AC and AD. ARGs such as *tetA*, *tetB*, and bla_{TEM} were frequently detected and their copy numbers were significantly reduced by ~1,000-fold by AD but not by AC. However, several ARG copies remained even after AD treatment. Although concentrations of the majority of residual antimicrobials were decreased by both AC and AD, oxytetracycline level was not decreased after treatment in most cases. In addition, 16S rRNA gene amplicon-based metagenomic analysis revealed that both treatments changed the bacterial community structure. These results suggest that both AC and AD could suppress the transmission of ARB, and AD could reduce ARG copy numbers in dairy cow manure.

Keywords: aerobic composting, ampicillin resistance, anaerobic digestion, antimicrobial resistance, dairy cow, tetracycline resistance

出典　doi: 10.3389/fmicb.2021.737420
https://doi.org/10.3389/fmicb.2021.737420
最終責任者　Masaru Usui (Corresponding Author)

Journal of Global Antimicrobial Resistance
Available online 20 December 2021
In Press, Journal Pre-proof

Broad-host-range IncW plasmid harbouring *tet*(X) in *Escherichia coli* isolated from pigs in Japan

MasaruUsui[a] AkiraFukuda[a] YasuhikoSuzuki[bc] ChieNakajima[bc] YutakaTamura[a]

Show more

Outline | Share Cite

https://doi.org/10.1016/j.jgar.2021.12.012
Get rights and content
Under a Creative Commons license
open access

Highlights

- Tigecycline is the last resort used to treat multidrug-resistant bacteria.
- Tigecycline resistance gene *tet*(X) was detected in *E. coli* isolate from pigs.
- Tet(X) is harboured in IncW plasmid, which is a broad-host-range plasmid.
- The emergence and spread of *tet*(X) poses a public health concern.

Abstract

Objectives

Tetracyclines are used in veterinary medicine for livestock. Tigecycline, a semisynthetic tetracycline derivative, is the last resort antimicrobial used to treat multidrug-resistant gram-negative bacterial infections. The prevalence of variants of mobile tigecycline resistance gene *tet*(X) in livestock is increasing worldwide. However, the prevalence of Tet(X) among livestock in Japan is obscure. This study was conducted to clarify the prevalence of Tet(X) in pigs in Japan, focusing on isolation and molecular characterisation of plasmid-mediated *tet*(X)-positive *Escherichia coli* through retrospective analysis.

Methods

We retrospectively screened for tigecycline-resistant *E. coli* strains isolated from pigs. The tigecycline-resistant strain and *tet*(X)-harbouring plasmid were characterised.

Results

The IncW plasmid harbouring the *tet*(X) variant (previously named as *tet*(X6)) was detected in one *E. coli* isolate from pigs (0.8%, 1/120) in 2012. The *tet*(X) plasmid was transferable by conjugation into the *E. coli* ML4909 recipient strain. Some mobile gene elements (TnAs3 and IS*Vsa3*) were observed in the region surrounding *tet*(X). The *tet*(X)-harbouring plasmid shared a conserved backbone IncW plasmid R388, which is a broad-host-range plasmid.

Conclusions

The emergence and spread of *tet*(X) variants in Enterobacterales poses a public health concern. To the best of our knowledge, this is the first report of the emergence of the IncW plasmid harbouring *tet*(X). Using tetracyclines in livestock

出典　doi: 10.1016/j.jgar.2021.12.012
https://doi.org/10.1016/j.jgar.2021.12.012
最終責任者　Masaru Usui (Corresponding Author)

獣医麻酔学（Veterinary Anesthesiology）

Kenjirou Miyoshi

Lecturer

講師　三好健二郎

Ⅰ．筆頭または責任著者　＜First or Corresponding Author＞

Ⅱ．その他＜Others＞

1) Effects of gel pad thickness on skin stiffness evaluation by ultrasonographic strain elastography in normal dogs
Chhay S, Hanazono K, Kitahara J, Hori A, **Miyoshi K**, Itami T, Endoh D, Nakade T.
Jpn J Vet Res. 69:125-134. 2021. doi: 10.14943/jjvr.69.2.125.

2) Mediastinal basaloid carcinoma arising from thymic cysts in two dogs
Sano Y, Seki K, **Miyoshi K**, Sakai T, Kadosawa T, Matsuda K.
J Vet Med Sci. 83:876-880. 2021. doi: 10.1292/jvms.20-0518.

3) The effects of gel pad thickness on the evaluation of skin structures using ultrasonography in normal dogs
Chhay S, Hanazono K, Kitahara J, Hori A, **Miyoshi K**, Itami T, Endoh D, Nakade T.
J Vet Med Sci. 83:1472-1475. 2021. doi: 10.1292/jvms.21-0086.

Japanese Journal of Veterinary Research 69(2): 125-134, 2021

JJVR

REGULAR PAPER Experimental Research

Effects of gel pad thickness on skin stiffness evaluation by ultrasonographic strain elastography in normal dogs

Sothavy Chhay[1)], Kiwamu Hanazono[2,3)], Jo Kitahara[1)], Ai Hori[3)], Kenjiro Miyoshi[1,3)], Takaharu Itami[1,3,*)], Daiji Endo[2)] and Tetsuya Nakade[1,3)]

[1)] Department of Small Animal Clinical Sciences, School of Veterinary Medicine, Rakuno Gakuen University, 582 Bunkyodai Midorimach, Ebetu-shi, Hokkaido 069-8501, Japan
[2)] Department of Biosciences, School of Veterinary Medicine, Rakuno Gakuen University, Ebetsu, Hokkaido 069-8501, Japan
[3)] Animal Medical Center, Rakuno Gakuen University, 582 Bunkyodai Midorimach, Ebetu-shi, Hokkaido 069-8501, Japan

Received for publication, November 8, 2020; accepted, February 25, 2021

Abstract

Gel pads are commonly used for skin ultrasound examination; however, the effect of their thickness on the measured values is unknown. We investigated the effect of pad thickness on skin stiffness measurement in healthy dogs. The skin stiffness of the dorsal neck was measured using a durometer. Ultrasonographic strain elastography was performed with 5-, 10-, and 20-mm-thick pads. Among the strain ratios, muscle/skin (5 mm) showed a significantly positive correlation with skin stiffness. In the strain histogram, AREA (20 mm), CONTRAST (20 mm), MEAN (5, 20 mm), and STANDARD DEVIATION (20 mm) were significantly correlated with skin stiffness. In conclusion, the thickness of the gel pad affects the measurements during skin ultrasonographic strain elastography.

Key Words: Gel pad, normal dog, skin ultrasonography, ultrasonographic strain elastography

出典　doi: 10.14943/jjvr.69.2.125.
http://hdl.handle.net/2115/81817

最終責任者　Kiwamu Hanazono (Corresponding Author)

The Journal of Veterinary Medical Science

NOTE

Pathology

Mediastinal basaloid carcinoma arising from thymic cysts in two dogs

Yuto SANO[1)*], Kanae SEKI[1)], Kenjirou MIYOSHI[2)], Toshikazu SAKAI[2)], Tsuyoshi KADOSAWA[2)] and Kazuya MATSUDA[1)]

[1)]Department of Veterinary Pathology, School of Veterinary Medicine, Rakuno Gakuen University, Ebetsu, Hokkaido 069-8501, Japan
[2)]Department of Small Animal Clinical Sciences, School of Veterinary Medicine, Rakuno Gakuen University, Ebetsu, Hokkaido 069-8501, Japan

J. Vet. Med. Sci.
83(5): 876–880, 2021
doi: 10.1292/jvms.20-0518

Received: 1 September 2020
Accepted: 24 March 2021
Advanced Epub:
5 April 2021

ABSTRACT. Mediastinal masses in dogs were diagnosed as basaloid carcinoma associated with multiple thymic cysts (MTCs). The masses were composed of MTCs and proliferating intracystic neoplastic basaloid cells, which immunohistochemically diffusely expressed p63 and cytokeratin 19. A gradual transition from the basal cell layers lining the cysts walls to the neoplastic cells was seen, and it was indicated that the neoplastic cells had originated from the basal cell layers of the cysts. To the best of our knowledge, this is the first report of basaloid carcinoma occurring in the mediastinal cavity in dogs. Although these tumors were demonstrated to be rare origins, basaloid carcinoma should be included in the differential diagnoses for canine mediastinal tumors.

KEY WORDS: basaloid carcinoma, dog, mediastinum, thymic branchial cyst, thymic cyst

出典　doi: 10.1292/jvms.20-0518.
https://doi.org/10.1292/jvms.20-0518

最終責任者　Yuto Sano　((First Author and Corresponding Author)

The Journal of Veterinary Medical Science

NOTE

Internal Medicine

The effects of gel pad thickness on the evaluation of skin structures using ultrasonography in normal dogs

Sothavy CHHAY[1)], Kiwamu HANAZONO[1,2)*], Jo KITAHARA[1)], Ai HORI[2)], Kenjiro MIYOSHI[1,2)], Takaharu ITAMI[1,2)], Daiji ENDOH[1)] and Tetsuya NAKADE[1,2)]

[1)]School of Veterinary Medicine, Rakuno Gakuen University, 582 Bunkyodai Midorimach, Ebetsu, Hokkaido 069-8501, Japan

[2)]Animal Medical Center, Rakuno Gakuen University, 582 Bunkyodai Midorimach, Ebetsu, Hokkaido 069-8501, Japan

J. Vet. Med. Sci.
83(9): 1472–1475, 2021
doi: 10.1292/jvms.21-0086

Received: 15 February 2021
Accepted: 14 July 2021
Advanced Epub:
26 July 2021

ABSTRACT. Gel pads are commonly used in skin ultrasonography; however, the effects of their thickness are unknown. This study investigated the effects of pad thickness on measurements of skin thickness in 10 beagle dogs. Sonograms to measure neck skin thickness were captured without pads and using pads with thicknesses of 3, 5, 10, and 20 mm. Without pads, acoustic shading was observed due to air bubbles in the coupling gel. With 20-mm pads, echogenic artifacts were observed on the skin surface. Entry echo with 20-mm pads was significantly higher than with 3-mm pads. This suggests that visibility of the skin structure could be affected when a gel pad is not used or when a thick gel pad is selected.

KEY WORDS: artifact, gel pad, normal dog, skin thickness, skin ultrasonography

出典　doi: 10.1292/jvms.21-0086.
https://doi.org/10.1292/jvms.21-0086

最終責任者　Kiwamu Hanazono (Corresponding Author)

獣医生化学（Veterinary Biochemistry）

Jumpei Fujiki

Lecturer

講師　藤木　純平

Ⅰ．筆頭または責任著者　＜First or Corresponding Author＞

1) Novel Virulent Bacteriophage ΦSG005, Which Infects *Streptococcus gordonii*, Forms a Distinct Clade among Streptococcus Viruses.
Fujiki J, Yoshida SI, Nakamura T, Nakamura K, Amano Y, Nishida K, Nishi K, Sasaki M, Iwasaki T, Sawa H, Komatsuzawa H, Hijioka H, Iwano H.
Viruses. 2021 Sep 29;13(10):1964. doi: 10.3390/v13101964.

2) Fluctuating Bacteriophage-induced galU Deficiency Region is Involved in Trade-off Effects on the Phage and Fluoroquinolone Sensitivity in Pseudomonas aeruginosa.
Nakamura K, **Fujiki J***, Nakamura T, Furusawa T, Gondaira S, Usui M, Higuchi H, Tamura Y, Iwano H.
Virus Res. 2021 Dec;306:198596. doi: 10.1016/j.virusres.2021.198596. Epub 2021 Oct 12.

3) Complete Genome Sequence of a Veterinary Pseudomonas aeruginosa Isolate, Pa12.
Nakamura K, **Fujiki J***, Furusawa T, Nakamura T, Gondaira S, Sasaki M, Usui M, Higuchi H, Sawa H, Tamura Y, Iwano H.
Microbiol Resour Announc. 2021 Jul;10(26):e0039821. doi: 10.1128/MRA.00398-21. Epub 2021 Jul 1.

Ⅱ．その他＜Others＞

1) Innate immune response in bovine neutrophils stimulated with Mycoplasma bovis.
Gondaira S, Nishi K, **Fujiki J**, Iwano H, Watanabe R, Eguchi A, Hirano Y, Higuchi H, Nagahata H. *Vet Res*. 2021 Apr 16;52(1):58. doi: 10.1186/s13567-021-00920-2.

2) Testicular induced corticosterone synthesis in male rats under fasting stress. Maeda N, **Fujiki J**, Hasegawa Y, Ieko T, Miyasho T, Iwasaki T, Yokota H. *Steroids*. 2022 Jan;177:108947. doi: 10.1016/j.steroids.2021.108947. Epub 2021 Nov 27.

viruses

MDPI

Article

Novel Virulent Bacteriophage ΦSG005, Which Infects *Streptococcus gordonii*, Forms a Distinct Clade among Streptococcus Viruses

Jumpei Fujiki [1], Shin-ichi Yoshida [1], Tomohiro Nakamura [1], Keisuke Nakamura [1], Yurika Amano [1], Keita Nishida [1], Keitaro Nishi [2], Michihito Sasaki [3], Tomohito Iwasaki [4], Hirofumi Sawa [3,5,6], Hitoshi Komatsuzawa [7], Hiroshi Hijioka [2] and Hidetomo Iwano [1,*]

1 Laboratory of Veterinary Biochemistry, Department of Veterinary Medicine, Rakuno Gakuen University, Ebetsu 069-8501, Japan; j-fujiki@rakuno.ac.jp (J.F.); Shinichi.Yoshida@kaneka.co.jp (S.-i.Y.); s21941005@stu.rakuno.ac.jp (T.N.); s21661158@stu.rakuno.ac.jp (K.N.); s21661157@stu.rakuno.ac.jp (Y.A.); nk.0418trbr@gmail.com (K.N.)
2 Department of Maxillofacial Diagnostic and Surgical Science, Field of Oral and Maxillofacial Rehabilitation, Graduate School of Medical and Dental Sciences, Kagoshima University, Kagoshima 890-8544, Japan; nsktr.248@gmail.com (K.N.); zio@dent.kagoshima-u.ac.jp (H.H.)
3 Division of Molecular Pathobiology, International Institute for Zoonosis Control, Hokkaido University, Sapporo 001-0020, Japan; m-sasaki@czc.hokudai.ac.jp (M.S.); h-sawa@czc.hokudai.ac.jp (H.S.)
4 Department of Food Science and Human Wellness, College of Agriculture, Food and Environment Science, Rakuno Gakuen University, Ebetsu 069-8501, Japan; iwasaki@rakuno.ac.jp
5 International Collaboration Unit, International Institute for Zoonosis Control, Hokkaido University, Sapporo 001-0020, Japan
6 One Health Research Center, Hokkaido University, Sapporo 001-0020, Japan
7 Department of Bacteriology, Graduate School of Biomedical and Health Sciences, Hiroshima University, Hiroshima 734-8553, Japan; komatsuz@hiroshima-u.ac.jp
* Correspondence: h-iwano@rakuno.ac.jp; Tel./Fax: +81-11-388-4885

check for updates

Citation: Fujiki, J.; Yoshida, S.-i.; Nakamura, T.; Nakamura, K.; Amano, Y.; Nishida, K.; Nishi, K.; Sasaki, M.; Iwasaki, T.; Sawa, H.; et al. Novel Virulent Bacteriophage ΦSG005, Which Infects *Streptococcus gordonii*, Forms a Distinct Clade among Streptococcus Viruses. *Viruses* **2021**, *13*, 1964. https://doi.org/10.3390/v13101964

Academic Editor: Terje Dokland

Received: 7 August 2021
Accepted: 25 September 2021
Published: 29 September 2021

Publisher's Note: MDPI stays neutral with regard to jurisdictional claims in published maps and institutional affiliations.

Copyright: © 2021 by the authors. Licensee MDPI, Basel, Switzerland. This article is an open access article distributed under the terms and conditions of the Creative Commons Attribution (CC BY) license (https://creativecommons.org/licenses/by/4.0/).

Abstract: Bacteriophages are viruses that specifically infect bacteria and are classified as either virulent phages or temperate phages. Despite virulent phages being promising antimicrobial agents due to their bactericidal effects, the implementation of phage therapy depends on the availability of virulent phages against target bacteria. Notably, virulent phages of *Streptococcus gordonii*, which resides in the oral cavity and is an opportunistic pathogen that can cause periodontitis and endocarditis have previously never been found. We thus attempted to isolate virulent phages against *S. gordonii*. In the present study, we report for the first time a virulent bacteriophage against *S. gordonii*, ΦSG005, discovered from drainage water. ΦSG005 is composed of a short, non-contractile tail and a long head, revealing *Podoviridae* characteristics via electron microscopic analysis. In turbidity reduction assays, ΦSG005 showed efficient bactericidal effects on *S. gordonii*. Whole-genome sequencing showed that the virus has a DNA genome of 16,127 bp with 21 coding sequences. We identified no prophage-related elements such as integrase in the ΦSG005 genome, demonstrating that the virus is a virulent phage. Phylogenetic analysis indicated that ΦSG005 forms a distinct clade among the streptococcus viruses and is positioned next to streptococcus virus C1. Molecular characterization revealed the presence of an anti-CRISPR (Acr) IIA5-like protein in the ΦSG005 genome. These findings facilitate our understanding of streptococcus viruses and advance the development of phage therapy against *S. gordonii* infection.

Keywords: bacteriophage; streptococcus virus; phage therapy; *Streptococcus gordonii*

1. Introduction

Bacteriophages, which are viruses that infect bacterial cells, are ubiquitous in nature. Phage lifecycles are divided into two major categories, lysogenic and lytic [1,2]. In the lysogenic cycle, temperate phages infect host bacterial cells but are usually integrated into

出典 doi: 10.3390/v13101964.
https://www.mdpi.com/1999-4915/13/10/1964
最終責任者 Hidetomo Iwano (Corresponding Author)

Contents lists available at ScienceDirect

Virus Research

journal homepage: www.elsevier.com/locate/virusres

Fluctuating Bacteriophage-induced *galU* Deficiency Region is Involved in Trade-off Effects on the Phage and Fluoroquinolone Sensitivity in *Pseudomonas aeruginosa*

Keisuke Nakamura [a,#], Jumpei Fujiki [a,#,*], Tomohiro Nakamura [a], Takaaki Furusawa [a], Satoshi Gondaira [b], Masaru Usui [c], Hidetoshi Higuchi [b], Yutaka Tamura [c], Hidetomo Iwano [a]

[a] *Laboratory of Veterinary Biochemistry, Department of Veterinary Medicine, Rakuno Gakuen University, Ebetsu, Hokkaido, Japan*
[b] *Laboratory of Animal Health, Rakuno Gakuen University School of Veterinary Medicine, Ebetsu, Hokkaido, Japan*
[c] *Laboratory of Food Microbiology and Food Safety, Rakuno Gakuen University School of Veterinary Medicine, Ebetsu, Hokkaido, Japan*

ARTICLE INFO

Keywords:
Bacteriophage
galU
Pseudomonas aeruginosa
Phage resistance
Phage therapy
Trade-off
Fitness cost

ABSTRACT

Pseudomonas aeruginosa, which causes chronic infections, has demonstrated rapid acquisition of antimicrobial resistance (AMR). Therefore, bacteriophages have received significant attention as promising antimicrobial agents; however, previous trials have reported the occurrence of phage-resistant variants. *P. aeruginosa* has lost large chromosomal fragments via evolutionary selection by MutL. Mutants lacking *galU* and *hmgA*, located in close proximity, exhibit phage resistance and brown color phenotype since *hmgA* encodes a homogentisic acid metabolic enzyme and deletion of *galU* results in a lack of *O*-antigen polysaccharide and absence of the phage receptor. In the present study, we evaluated this mechanism for controlling phage resistance in *P. aeruginosa* veterinary isolate Pa12. Phage-resistant Pa12 brown mutants (brmts) with *galU* and *hmgA* deletions were isolated. Whole-genome sequencing of the brmts revealed that regions 148-27 kbp upstream and 261-110 kbp downstream of *galU* were largely deleted from the Pa12 parental chromosome. Furthermore, all of these fluctuating deleted sequences in Pa12 brmts, tentatively designated bacteriophage-induced *galU* deficiency (BigD) regions, harbor multi-drug efflux system genes (*mexXY*). Minimum inhibitory concentration (MIC) assays demonstrated that brmts altered sensitivity to antibiotics and exhibited increased levofloxacin sensitivity compared with the Pa12 parent. Orbifloxacin and enrofloxacin also effectively suppressed growth of the Pa12 brmts, suggesting that MexXY, which mediates quinolone efflux and is located in the BigD region, might be associated with restoration of fluoroquinolone sensitivity. Our findings indicate that AMR-related genes in the BigD region could produce trade-off effects between phages and drug sensitivity and thereby contribute to a potential strategy to control and prevent phage-resistant variants in phage therapy.

出典　doi: 10.1016/j.virusres.2021.198596.
https://www.sciencedirect.com/science/article/abs/pii/S0168170221003038?via%3Dihub
最終責任者 Jumpei Fujiki（Corresponding and Co-first Author）

AMERICAN SOCIETY FOR MICROBIOLOGY | Microbiology Resource Announcements

GENOME SEQUENCES

Complete Genome Sequence of a Veterinary *Pseudomonas aeruginosa* Isolate, Pa12

Keisuke Nakamura,[a] Jumpei Fujiki,[a] Takaaki Furusawa,[a] Tomohiro Nakamura,[a] Satoshi Gondaira,[b] Michihito Sasaki,[c] Masaru Usui,[d] Hidetoshi Higuchi,[b] Hirofumi Sawa,[c,e] Yutaka Tamura,[d,f] Hidetomo Iwano[a]

[a]Laboratory of Veterinary Biochemistry, Rakuno Gakuen University School of Veterinary Medicine, Ebetsu, Japan
[b]Laboratory of Animal Health, Rakuno Gakuen University School of Veterinary Medicine, Ebetsu, Japan
[c]Division of Molecular Pathobiology, International Institute for Zoonosis Control, Hokkaido University, Sapporo, Japan
[d]Laboratory of Food Microbiology and Food Safety, Rakuno Gakuen University School of Veterinary Medicine, Ebetsu, Japan
[e]International Collaboration Unit, International Institute for Zoonosis Control, Hokkaido University, Sapporo, Japan
[f]Center for Veterinary Drug Development, Rakuno Gakuen University, Ebetsu, Japan

ABSTRACT *Pseudomonas aeruginosa* causes various opportunistic infections in animals. Here, we report the complete genome sequence of *P. aeruginosa* strain Pa12, a fluoroquinolone-resistant isolate from a canine skin lesion. To expand the molecular antimicrobial characteristics of the isolate, the whole Pa12 genome was sequenced and assembled via long- and short-read platforms.

Pseudomonas aeruginosa is an opportunistic Gram-negative bacterium and an important pathogen of humans and animals. In veterinary medicine, *P. aeruginosa* typically causes skin and urinary tract infections in dogs (1–3). The recent spread of antimicrobial resistance (AMR) has become a major problem in veterinary medicine; notably, the rate of resistance to fluoroquinolones has increased rapidly (4–6).

Pseudomonas aeruginosa exhibits AMR via multiple mechanisms. Multidrug efflux (Mex) systems are associated with intrinsic fluoroquinolone resistance, and *P. aeruginosa* can also acquire fluoroquinolone resistance through mutations in genes of the quinolone resistance–determining region (QRDR) (7–10).

We previously isolated *P. aeruginosa* strain Pa12 from a canine skin lesion at a veterinary hospital in Japan (11). The specimen was cultured on sheep blood agar and MacConkey agar at 35°C for 24 to 48 h under aerobic conditions. This strain exhibited intermediate resistance to orbifloxacin in MIC assays (11, 12). In the present study, we report the complete genome sequence of *P. aeruginosa* strain Pa12 to enhance molecular understanding of the isolate with respect to AMR.

DNA was extracted from an overnight culture (grown at 37°C in LB medium) using phenol and chloroform (13) and purified using a QIAamp DNA minikit column (Qiagen, Hilden, Germany). The DNA concentration was determined using a Qubit fluorometer (Invitrogen, Carlsbad, CA, USA). Whole-genome sequencing was performed using MiSeq (Illumina, San Diego, CA, USA) and GridION X5 (Oxford Nanopore Technologies [ONT], Oxford, UK) platforms. Libraries for Illumina sequencing were prepared using a Nextera XT DNA library preparation kit (Illumina). The whole genome was then subjected to 300-bp paired-end sequencing on the MiSeq platform. The resulting 8,118,954 reads were trimmed of adaptors and low-quality bases (Q scores of <20), and short reads (<127 bp) were removed using Sickle v1.33. Libraries for GridION X5 sequencing were prepared using a native barcoding expansion kit (ONT) and a ligation sequence kit (SQK-LSK109; ONT) without DNA shearing. The resulting sample was sequenced on the GridION X5 platform using an R9.4.1 flow cell (ONT) and Guppy v3.2.10 for live base calling. The resulting 56,776 reads were trimmed and quality filtered using Porechop v0.2.3 and Filtlong v0.2.0 (minimum length, 1,000 bp; N_{50}, 25,214 bp). Hybrid *de novo* assembly,

Citation Nakamura K, Fujiki J, Furusawa T, Nakamura T, Gondaira S, Sasaki M, Usui M, Higuchi H, Sawa H, Tamura Y, Iwano H. 2021. Complete genome sequence of a veterinary *Pseudomonas aeruginosa* isolate, Pa12. Microbiol Resour Announc 10:e00398-21. https://doi.org/10.1128/MRA.00398-21.

Editor Irene L. G. Newton, Indiana University, Bloomington

Copyright © 2021 Nakamura et al. This is an open-access article distributed under the terms of the Creative Commons Attribution 4.0 International license.

Address correspondence to Jumpei Fujiki, j-fujiki@rakuno.ac.jp.

Received 18 April 2021
Accepted 31 May 2021
Published 1 July 2021

出典　doi: 10.1128/MRA.00398-21.
https://journals.asm.org/doi/epub/10.1128/MRA.00398-21

最終責任者 Jumpei Fujiki（Corresponding Author）

Gondaira et al. Vet Res (2021) 52:58
https://doi.org/10.1186/s13567-021-00920-2

VETERINARY RESEARCH

RESEARCH ARTICLE Open Access

Innate immune response in bovine neutrophils stimulated with *Mycoplasma bovis*

Satoshi Gondaira[1], Koji Nishi[1], Jumpei Fujiki[2], Hidetomo Iwano[2], Reina Watanabe[1], Ayako Eguchi[1], Yuki Hirano[3], Hidetoshi Higuchi[1*] and Hajime Nagahata[1,4]

Abstract

Mycoplasma bovis (*M. bovis*) is a significant worldwide pathogen of cattle. Neutrophils have an important role in the innate immune response during infection with *M. bovis*. However, even though neutrophils accumulate in *M. bovis* infection, the interaction of *M. bovis* and neutrophils has not been fully elucidated. We attempted to elucidate the innate immune response of neutrophils stimulated with *M. bovis* and evaluate the transcriptome and functional analysis of bovine neutrophils stimulated with *M. bovis*. Proinflammatory cytokines, such as inducible nitric oxide (*iNOS*), which was the most increased gene in transcriptome analysis, were increased in quantitative polymerase chain reaction analysis of bovine neutrophils stimulated with live or heat-killed *M. bovis*. Nitric oxide and intracellular reactive oxygen species production of neutrophils stimulated with *M. bovis* was significantly increased. Neutrophils stimulated with *M. bovis* showed an increased ratio of nonapoptotic cell death compared to unstimulated controls. We demonstrated that neutrophil extracellular traps (NETs) formation was not recognized in neutrophils stimulated with live *M. bovis*. However, heat-killed *M. bovis* induced NETs formation. We also showed the interaction with *M. bovis* and bovine neutrophils regarding proinflammatory cytokine gene expression and functional expression related to NETs formation. Live and killed *M. bovis* induced innate immune responses in neutrophils and had the potential to induce NETs formation, but live *M. bovis* escaped NETs.

Keywords: *Mycoplasma bovis*, Bovine, Neutrophils, Innate immune, Transcriptome analysis

出典　doi:110.1186/s13567-021-00920-2.
https://veterinaryresearch.biomedcentral.com/articles/10.1186/s13567-021-00920-2

最終責任者　Hidetoshi Higuchi（Corresponding Author）

Contents lists available at ScienceDirect

Steroids

journal homepage: www.elsevier.com/locate/steroids

Testicular induced corticosterone synthesis in male rats under fasting stress

Naoyuki Maeda [a], Jumpei Fujiki [b], Yasuhiro Hasegawa [c], Takahiro Ieko [b], Taku Miyasho [d], Tomohito Iwasaki [c], Hiroshi Yokota [b,*]

[a] Laboratory of Meat Science and Technology, Department of Food Science and Human Wellness, Rakuno Gakuen University, Hokkaido 069-8501, Japan
[b] Laboratory of Veterinary Biochemistry, Department of Veterinary Medicine, Rakuno Gakuen University, Hokkaido 069-8501, Japan
[c] Laboratory of Applied Biochemistry, Department of Food Science and Human Wellness, Rakuno Gakuen University, Hokkaido 069-8501, Japan
[d] Laboratory of Animal Biological Responses, Department of Veterinary Science, Rakuno Gakuen University, Hokkaido 069-8501, Japan

ARTICLE INFO

Keywords:
Testicular steroidogenesis
Testosterone
Corticosterone
3β-hydroxysteroid dehydrogenase
Fasting stress

ABSTRACT

Testicular steroidogenesis is depressed by adrenal-secreted corticosterone (CORT) under stress. However, the mechanisms are not well understood. This study investigated the details of testicular steroidogenesis depression during fasting. Blood levels of adrenocorticotropic hormone secreted from the pituitary glands increased, but blood CORT was not changed in rats that fasted for 96 h, in spite of the rats being severely stressed. CORT in fasting adult male rats increased more than three times in the testis, but reduced testicular testosterone (T) and blood T levels to 5% and 2% of the control, respectively, was observed. The contents of T precursor (except PGN) were drastically reduced in the fasted-rat testes. Testicular CORT levels were elevated, but the enzymatic activity of cytochrome P45011β, which produces CORT, remained unchanged. The enzymatic activities of 3β-hydroxysteroid dehydrogenase (3β-HSD), mediating the conversion of pregnenolone to progesterone, decreased in the fasted-rat testes. Thus, fasting suppressed testicular steroidogenesis by affecting the enzyme activity of 3β-HSD in the testes and drastically reduced T and increased CORT synthesis. It can be considered that T synthesis involved in cell proliferation is suppressed due to lack of energy during fasting. Conversely, 11β-hydroxylase enzyme activity was induced and CORT synthesis is increased to cope with the fasting stress. Hence, it can be concluded that CORT synthesis in the testes plays a role in the local defense response.

出典　10.1016/j.steroids.2021.108947.
https://linkinghub.elsevier.com/retrieve/pii/S0039-128X(21)00159-8
最終責任者　Hiroshi Yokota（Corresponding Author）

獣医細菌学（Veterinary Bacteriology）

Ryo Murata

Lecturer

講師　村田　亮

Ⅰ．筆頭または責任著者　＜First or Corresponding Author＞

Ⅱ．その他＜Others＞

1）Changes in mRNA of immune factors expressed by milk somatic cells of Holstein cows with hypocalcemia after calving.
Ohtsuka H, Ohsawa M, Murakami K, **Murata R**, Kato T, Tajima M.
Can. J. Vet. Res. 85:72-76. 2021

2) Use of antimicrobial agents on a dairy farm where cefazoline-low susceptible Mannheimia haemolytica serotype 1 was isolated.
M. Akiyoshi, M. Nouchi, K. Sugiura, **R. Murata**, N. Abe, A. Sato, T. Kato.
Jpn. J. Anim. Hyg. 47:85-90. 2021.

Canadian Journal of Veterinary Research
Revue Canadienne de Recherche Vétérinaire
Formerly published as Canadian Journal of Comparative Medicine
Journal Web site
How to Submit

Can J Vet Res. 2021 Jan; 85(1): 72–76.

PMCID: PMC7747659
PMID: 33390657

Language: English | French

Changes in mRNA of immune factors expressed by milk somatic cells of Holstein cows with hypocalcemia after calving

Hiromichi Ohtsuka,✉ Misa Ohsawa, Kenji Murakami, Ryo Murata, Toshihide Kato, and Motoshi Tajima

▸ Author information ▸ Article notes ▸ Copyright and License information Disclaimer

Abstract

Go to:

Changes in immune factors expressed by milk somatic cells from Holstein cows with hypocalcemia after calving were investigated in this study. Fourteen multiparous Holstein cows after their 3rd or 4th calving in one farm were used. The cows were divided into 2 groups: 7 cows needing treatment due to onset of hypocalcemia (hypocalcemia group; age = 5.53 ± 0.27 years, parity = 3.14 ± 0.14) and 7 cows without health problems (control group; age = 5.88 ± 0.31 years, parity = 3.57 ± 0.26). Milk samples were collected aseptically using a cannula and mRNA of immune factors expressed by milk somatic cells were analyzed. Milk samples (50 mL) were collected from the right rear mammary gland of cows before milking at day 1 and weeks 1, 2, 4, and 8 after calving. All milk samples showed a negative reaction to the California Mastitis Test. Levels of relative interleukin (IL)-6 and cathelicidin in the hypocalcemia group were lower than those in the control group in weeks 1 to 8. A significant difference in relative IL-6 levels was found in week 4 ($P < 0.05$). These results suggest that levels of IL-6 expressed by milk somatic cells may be affected by hypocalcemia in dairy cows.

出典　https://www.ncbi.nlm.nih.gov/pmc/articles/PMC7747659/

最終責任者　Hiromichi Ohtsuka (Corresponding Author)

Note

Use of antimicrobial agents on a dairy farm where cefazoline-low susceptible *Mannheimia haemolytica* serotype 1 was isolated

Misaki Akiyoshi[1], Minami Nouchi[1], Kazumi Sugiura[1], Ryo Murata[2], Noritsugu Abe[1], Ayano Sato[1]*, Toshihide Kato[1]

([1] Division of Farm Animal Clinical Science, School of Veterinary Medicine, Rakuno Gakuen University, 582-1 Bunkyodai-midorimachi, Ebetsu, Hokkaido 069-8501, Japan
[2] Division of Pathobiology, School of Veterinary Medicine, Rakuno Gakuen University, 582-1 Bunkyodai-midorimachi, Ebetsu, Hokkaido 069-8501, Japan
* Corresponding Author: Ayano Sato (e-mail: ayanok@rakuno.ac.jp))
(Received 14. May. 2021／Accepted 29. Jul. 2021)

Summary

Mannheimia haemolytica serotype 1 was isolated from a dairy farm with frequent pneumonia in adult cattle. In order to investigate the cause of *M. haemolytica* serotype 1 strain showing low cefazolin (CEZ) susceptibility, the occurrence of mastitis prior to pneumonia and the use of antimicrobial agents were investigated and compared with a control farm in the same series with low pneumonia incidence. In addition, *M. haemolytica* isolates from the control farm were examined for drug susceptibilities. The annual incidence of mastitis was 1.29 and 0.55 in the study and control farms, respectively, and the incidence ratio between the two farms was 2.35, which was significantly higher in the study farm. The antimicrobial agents used for mastitis treatment at the study farm were cephalosporin-based, and consisted of 70.2 g of CEZ intramammary infusion and 129 g of CEZ systemic injection to the intramammary for off-label use. Only intramammary infusions were used on the control farm, and CEZ was administered at a dose of 12.9 g. Per head of the study farm enrollment, the amount of CEZ intramammary infusion and intramammary injectants used (4.6 g) was more than 5 times that of the control farm (0.89 g), and approximately 2.6 times the standard dosage of CEZ intramammary infusion for lactation (0.15 g/dose per container × 4 mammary glands × 3 days = 1.8 g) for cattle with 4 affected mammary glands. Also, the MIC values for CEZ of *M. haemolytica* isolated from the control farm were low. Thus, it can be inferred that excessive use of CEZ was one of the factors responsible for the decreased susceptibility of *M. haemolytica* in the study farm. Another factor could be the external invasion of CEZ low-susceptible *M. haemolytica*. However, it was inferred that it was unlikely to have been introduced from this farm, as only individuals raised on the control farm were introduced.

Key words : antimicrobial usage, drug susceptibility, *Mannheimia haemolytica*, intramammary therapy

Jpn. J. Anim. Hyg. 47, 85~90 (2021)

出典　http://www.kachiku-eisei.jp
最終責任者　Ayano Sato (Corresponding Author)

獣医麻酔学（Veterinary Anesthesiology）

Keiko Kato

Assistant Professor

助教　加藤　桂子

Ⅰ．筆頭または責任著者　＜First or Corresponding Author＞

6）The anesthetic effects of intramuscular alfaxalone in dogs premedicated with low-dose medetomidine and/or butorphanol.
Kato K, Itami T, Nomoto K, Endo Y, Tamura J, Oyama N, Sano T, Yamashita K.
J. Vet. Med. Sci. 83:53-61. 2021. doi: 10.1292/jvms.20-0330.

Ⅱ．その他＜Others＞

3）Effects of sevoflurane, propofol or alfaxalone on neuromuscular blockade produced by a single intravenous bolus of rocuronium in dogs.
Chen IY, Tamogi H, Wei Y, **Kato K**, Itami T, Sano T, Yamashita K.
Vet. Anaesth. Analg. Online ahead of print. 2021.
doi: 10.1016/j.vaa.2021.10.002.

The Journal of Veterinary Medical Science

FULL PAPER
Surgery

The anesthetic effects of intramuscular alfaxalone in dogs premedicated with low-dose medetomidine and/or butorphanol

Keiko KATO[1], Takaharu ITAMI[1]*, Ken NOMOTO[1], Yusuke ENDO[1], Jun TAMURA[1], Norihiko OYAMA[1], Tadashi SANO[2] and Kazuto YAMASHITA[1]

[1]Department of Small Animal Clinical Sciences, School of Veterinary Medicine, Rakuno Gakuen University, Ebetsu, Hokkaido 069-8501, Japan
[2]Department of Veterinary Nursing Sciences, School of Veterinary Medicine, Rakuno Gakuen University, Ebetsu, Hokkaido 069-8501, Japan

ABSTRACT. We aimed to evaluate the induction, anesthesia, and cardiorespiratory effects of intramuscular (IM) anesthetic protocol with alfaxalone following premedication with low-dose medetomidine, butorphanol, or a combination of both (medetomidine–butorphanol) in dogs. Six healthy beagles were administered 1, 2.5, or 5 mg/kg alfaxalone IM following premedication with low-dose medetomidine (5 µg/kg; MA-IM), butorphanol (0.3 mg/kg; BA-IM), or medetomidine-butorphanol (5 µg/kg and 0.3 mg/kg, respectively; MBA-IM). Each dog received 9 treatments with minimum 7-day washout period between treatments. Dogs were allowed to breath room air during anesthetic induction. We attempted endotracheal intubation after alfaxalone administration. Alfaxalone produced a dose-dependent anesthetic effect in each anesthetic protocol. Intubation was achieved in 4 out of 6 dogs that received MA-IM and BA-IM with 2.5 mg/kg alfaxalone and in all dogs that received MBA-IM with 1, 2.5, and 5 mg/kg alfaxalone. The median durations [minimum–maximum] of accepting intubation were 79 [0–89], 97 [84–120], and 117 [84–217] min, respectively. Hypotension (mean arterial blood pressure <60 mmHg) did not develop, but bradycardia (heart rate <60 beats/min) was observed in all dogs that received the MA-IM and MBA-IM protocols. Severe hypoxemia (percutaneous arterial oxygen saturation <90%) developed in 2 dogs that received MBA-IM with 5 mg/kg alfaxalone. We consider that the MA-IM and BA-IM protocols with ≥2.5 mg/kg alfaxalone and the MBA-IM protocol with 1–2.5 mg/kg alfaxalone could provide clinically useful and effective anesthesia without causing severe cardiorespiratory depression in healthy dogs.

KEY WORDS: alfaxalone, butorphanol, dog, intramuscular anesthesia, medetomidine

J. Vet. Med. Sci.
83(1): 53–61, 2021
doi: 10.1292/jvms.20-0330

Received: 1 June 2020
Accepted: 28 October 2020
Advanced Epub:
13 November 2020

*Correspondence to: Itami, T.: t-itami@rakuno.ac.jp
(Supplementary material: refer to PMC https://www.ncbi.nlm.nih.gov/pmc/journals/2350/)

©2021 The Japanese Society of Veterinary Science

This is an open-access article distributed under the terms of the Creative Commons Attribution Non-Commercial No Derivatives (by-nc-nd) License. (CC-BY-NC-ND 4.0: https://creativecommons.org/licenses/by-nc-nd/4.0/)

出典　doi: 10.1292/jvms.20-0330.
https://www.ncbi.nlm.nih.gov/pmc/articles/PMC7870407/pdf/jvms-83-053.pdf

最終責任者　Takaharu Itami (Corresponding Author)

Veterinary Anaesthesia and Analgesia xxxx, xxx, xxx

RESEARCH PAPER

Effects of sevoflurane, propofol or alfaxalone on neuromuscular blockade produced by a single intravenous bolus of rocuronium in dogs

I-Ying Chen, Haruka Tamogi, Yixian Wei, Keiko Kato, Takaharu Itami, Tadashi Sano & Kazuto Yamashita

Department of Small Animal Clinical Sciences, School of Veterinary Medicine, Rakuno Gakuen University, Ebetsu, Hokkaido, Japan

Corresponding. Kazuto Yamashita, Department of Small Animal Clinical Sciences, School of Veterinary Medicine, Rakuno Gakuen University, 582, Bunkyodai-Midorimachi, Ebetsu, Hokkaido 069-8501, Japan. E-mail: yamasita@rakuno.ac.jp

Abstract

Objective To compare the effects of sevoflurane, propofol and alfaxalone on the neuromuscular blockade induced by a single intravenous bolus of rocuronium in dogs.

Study design A randomized, prospective, crossover experimental study.

Animals A total of eight adult Beagle dogs (four female, four male), weighing 8.9−15.3 kg and aged 5−7 years.

Methods The dogs were anesthetized three times with 1.25× minimum alveolar concentration of sevoflurane (SEVO treatment) and 1.25× minimum infusion rate of propofol (PROP treatment) or alfaxalone (ALFX treatment) at intervals of ≥14 days. Neuromuscular function was monitored with train-of-four (TOF) stimulation of the peroneal nerve by acceleromyography. After recording the control TOF ratio (TOFRC), a single bolus dose of rocuronium (1 mg kg^{-1}) was administered intravenously. The times from rocuronium administration to achieving TOF count 0 (onset time), from achieving TOF count 0 to the reappearance of TOF count 4 (clinical blockade period), from 25% to 75% of TOFRC (recovery index) and from achieving TOF count 0 to TOF ratio/TOFRC >0.9 (total neuromuscular blockade duration) were recorded.

Results The onset time and recovery index did not differ among the treatments. The median clinical blockade period was longer in the SEVO treatment [27.3 (26.0−30.3) minutes] than in PROP [16.6 (15.4−18.0) minutes; $p = 0.002$] and ALFX [22.4 (18.6−23.1) minutes; $p = 0.017$] treatments; and longer in the ALFX treatment than in the PROP treatment ($p = 0.020$). The mean total neuromuscular blockade duration was longer in the SEVO treatment (43.7 ± 9.9 minutes) than in PROP (25.1 ± 2.7 minutes; $p < 0.001$) and ALFX (32.5 ± 8.4 minutes; $p = 0.036$) treatments.

Conclusions and clinical relevance Compared with alfaxalone and propofol, sevoflurane prolonged rocuronium-induced neuromuscular blockade by a significantly greater extent in dogs.

Keywords alfaxalone, dogs, neuromuscular blockade, propofol, rocuronium, sevoflurane.

Introduction

Rocuronium bromide, an aminosteroid, is a nondepolarizing neuromuscular blocking agent (NMBA). It has a faster onset as compared with that of vecuronium, but the duration of action is similar between the two (Marshall et al. 1994; Larijani et al. 1995; Kansanaho et al. 1997). Currently, rocuronium has widespread clinical application in veterinary practice and has been administered to dogs through intravenous (IV) boluses, incremental IV doses or constant rate infusion (CRI) to improve skeletal muscle relaxation during surgical procedures under general anesthesia (Dugdale et al. 2002; Alderson et al. 2007; Auer et al. 2007; Briganti et al. 2015; Haga et al. 2019). However, administration of NMBAs may lead to a residual block, which is the presence of a neuromuscular blockade during the postoperative period (Jones et al. 2015). Studies in humans have shown that sex, body weight, body temperature, concentration of volatile anesthetic agents and interval between the last NMBA administration and reversal agent administration are associated with a residual block (Vanlinthout et al. 1996; Srivastava & Hunter 2009; Khamtuikrua et al. 2017; Saager et al. 2019).

出典　doi: 10.1016/j.vaa.2021.10.002.
https://www.vaajournal.org/article/S1467-2987(21)00294-4/pdf
最終責任者　Kazuto Yamashita (Corresponding Author)

伴侶動物外科学（Companion Animal Surgery）

Toshikazu Sakai

Assistant Professor

助教　酒井　俊和

Ⅰ．筆頭または責任著者　＜First or Corresponding Author＞

1）Mid-to-caudal partial hemipelvectomy with limb preservation for ischial tumor in a dog.
Endo Y, **Sakai T**, Fukui S, Hori A, Echigo R, Matsunaga S, Kadosawa T.
J Vet Med Sci. 2021.in press. doi: 10.1292/jvms.21-0414

Ⅱ．その他＜Others＞

1) Mediastinal basaloid carcinoma arising from thymic cysts in two dogs.
Sano Y, Seki K, Miyoshi K, **Sakai T**, Kadosawa T, Matsuda K.
J Vet Med Sci. 83:876-880.2021. doi: 10.1292/jvms.20-0518

The Journal of Veterinary Medical Science

NOTE

Surgery

Mid-to-caudal partial hemipelvectomy with limb preservation for ischial tumor in a dog

Yoshifumi ENDO[1,2], Toshikazu SAKAI[1]*, Sho FUKUI[1], Ai HORI[1], Ryosuke ECHIGO[2], Satoru MATSUNAGA[2] and Tsuyoshi KADOSAWA[1]

[1]School of Veterinary Medicine, The Rakuno Gakuen University, 582 Bunkyodai Midorimachi, Ebetsu-shi, Hokkaido 069-8501, Japan

[2]Japan Animal Referral Medical Center, 2-5-8 Kuji, Takatsu-ku, Kawasaki-shi, Kanagawa 213-0032, Japan

J. Vet. Med. Sci.
84(2): **–**, 2022
doi: 10.1292/jvms.21-0414

Received: 23 July 2021
Accepted: 28 November 2021
Advanced Epub:
13 December 2021

ABSTRACT. A 10-year-old spayed female Golden Retriever was referred for hindlimb lameness. A firm mass was palpated over the right caudal pelvis. Computed tomography revealed an osteolytic bone region and an associated periosteal reaction in the ischium, including the acetabulum. The histological diagnosis was sarcoma of unknown origin. A mid-to-caudal partial hemipelvectomy was performed to remove the mass. Femoral head and neck osteotomy was performed to allow hindlimb preservation. Following surgery, the dog regained satisfactory hindlimb use over time and was alive for 821 days with no recurrence or metastatic disease. This report indicates that mid-to-caudal partial hemipelvectomy with femoral head and neck osteotomy is technically feasible and allows for tumor control with preservation of the hindlimb and its function.

KEY WORDS: dog, femoral head and neck osteotomy, limb preservation, mid-to-caudal hemipelvectomy, pelvic tumor

出典　doi: 10.1292/jvms.21-0414
https://www.jstage.jst.go.jp/article/jvms/advpub/0/advpub_21-0414/_article

最終責任者　Toshikazu Sakai(Corresponding Author)

The Journal of Veterinary Medical Science

NOTE

Pathology

Mediastinal basaloid carcinoma arising from thymic cysts in two dogs

Yuto SANO[1)]*, Kanae SEKI[1)], Kenjirou MIYOSHI[2)], Toshikazu SAKAI[2)], Tsuyoshi KADOSAWA[2)] and Kazuya MATSUDA[1)]

[1)]Department of Veterinary Pathology, School of Veterinary Medicine, Rakuno Gakuen University, Ebetsu, Hokkaido 069-8501, Japan

[2)]Department of Small Animal Clinical Sciences, School of Veterinary Medicine, Rakuno Gakuen University, Ebetsu, Hokkaido 069-8501, Japan

J. Vet. Med. Sci.
83(5): 876–880, 2021
doi: 10.1292/jvms.20-0518

Received: 1 September 2020
Accepted: 24 March 2021
Advanced Epub:
5 April 2021

ABSTRACT. Mediastinal masses in dogs were diagnosed as basaloid carcinoma associated with multiple thymic cysts (MTCs). The masses were composed of MTCs and proliferating intracystic neoplastic basaloid cells, which immunohistochemically diffusely expressed p63 and cytokeratin 19. A gradual transition from the basal cell layers lining the cysts walls to the neoplastic cells was seen, and it was indicated that the neoplastic cells had originated from the basal cell layers of the cysts. To the best of our knowledge, this is the first report of basaloid carcinoma occurring in the mediastinal cavity in dogs. Although these tumors were demonstrated to be rare origins, basaloid carcinoma should be included in the differential diagnoses for canine mediastinal tumors.

KEY WORDS: basaloid carcinoma, dog, mediastinum, thymic branchial cyst, thymic cyst

出典　doi: 10.1292/jvms.20-0518
https://www.jstage.jst.go.jp/article/jvms/83/5/83_20-0518/_article

最終責任者　Kazuya Matsuda (Corresponding Author)

生産動物外科学（Farm Animal Surgery）

Ayano Sato

Assistant Professor

助教　佐藤　綾乃

Ⅰ．筆頭または責任著者　＜First or Corresponding Author＞

1）Comparison of distal forelimb conformations between Japanese Black and Holstein-Friesian newborn calves.
Sato A, Kato K, Tajima M.
J. Vet. Med. Sci. 83: 940-946. 2021. doi: 10.1292/jvms.20-0615

2）Use of antimicrobial agents on a dairy farm where cefazoline-low susceptible Mannheimia haemolytica serotype 1 was isolated
Akiyoshi M, Nouchi M, Sugiura K, Murata R, Abe N, **Sato A**, Kato T.
Jpn. J. Anim. Hyg. 47:85-90. 2021.

Ⅱ．その他＜Others＞

1) Effects of intra-articular inoculation with Mycoplasma bovis on immunological responses in calf joints.
Nishi K, Hirano Y, **Sato A**, Eguchi A, Matsuda K, Toda M, Watanabe T, Iwasaki T, Takahashi N, Hosotani M, Watanabe R, Kato T, Ohtsuka H, Gondaira S, Higuchi H.
Vet. Immunol. Immunopathol. Online ahead of print. doi: 10.1016/j.vetimm.2021.110364

The Journal of Veterinary Medical Science

FULL PAPER
Surgery

Comparison of distal forelimb conformations between Japanese Black and Holstein-Friesian newborn calves

Ayano SATO[1)], Toshihide KATO[1)] and Motoshi TAJIMA[1)]*

[1)]School of Veterinary Medicine, Rakuno Gakuen University, Ebetsu, Hokkaido 069-8501, Japan

ABSTRACT. Flexural and hyperextension deformities are congenital problems in calves. We, therefore, aimed to investigate the distal limb conformation in 1 day- and 28-day-old female Holstein-Friesian (HF) calves (n=21), male Japanese Black (JB) calves (n=15), and female JB calves (n=15). The claw angle of the forelimb dorsal claw wall in a standing position and recorded other parameters, including body weight, withers height, circumference of forelimbs, and flexor tendon thickness in the forelimbs, were measured and compared these between the three groups. At 1 day old, the mean claw angles were 51.1° in female HF calves, 47.0° in male JB calves, and 41.8° in female JB calves; the 95% confidence intervals (CIs) of the claw angles showed large distributions in all three groups. One female HF and one male JB calves showed mild flexural deformity, whereas four JB calves showed hyperextension deformity. At 28 days old, the mean claw angles were 51.7° in female HF calves, 51.2° in male JB calves, and 48.4° in female JB calves; the 95% CIs of the claw angles showed smaller distributions than those at 1 day old in all groups. For all groups, the limb deformities had improved without treatment at 28 days old. As a feature of the breed, female JB calves were apt to show hyperextended deformities inversely proportional to the body weight. These limb deformities healed spontaneously and were thought to be physiological.

KEY WORDS: breed, calf, conformation, forelimb

J. Vet. Med. Sci.
83(6): 940–946, 2021
doi: 10.1292/jvms.20-0615

Received: 21 October 2020
Accepted: 12 April 2021
Advanced Epub:
30 April 2021

出典　doi:10.1292/jvms.20-0615
https://www.jstage.jst.go.jp/article/jvms/83/6/83_20-0615/_article

筆頭著者　Ayano Sato (First Author)

Note

Use of antimicrobial agents on a dairy farm where cefazoline-low susceptible *Mannheimia haemolytica* serotype 1 was isolated

Misaki Akiyoshi[1], Minami Nouchi[1], Kazumi Sugiura[1], Ryo Murata[2], Noritsugu Abe[1], Ayano Sato[1]*, Toshihide Kato[1]

([1]) Division of Farm Animal Clinical Science, School of Veterinary Medicine, Rakuno Gakuen University, 582-1 Bunkyodai-midorimachi, Ebetsu, Hokkaido 069-8501, Japan
[2] Division of Pathobiology, School of Veterinary Medicine, Rakuno Gakuen University, 582-1 Bunkyodai-midorimachi, Ebetsu, Hokkaido 069-8501, Japan
* Corresponding Author: Ayano Sato (e-mail: ayanok@rakuno.ac.jp))
(Received 14. May. 2021／Accepted 29. Jul. 2021)

Summary

Mannheimia haemolytica serotype 1 was isolated from a dairy farm with frequent pneumonia in adult cattle. In order to investigate the cause of *M. haemolytica* serotype 1 strain showing low cefazolin (CEZ) susceptibility, the occurrence of mastitis prior to pneumonia and the use of antimicrobial agents were investigated and compared with a control farm in the same series with low pneumonia incidence. In addition, *M. haemolytica* isolates from the control farm were examined for drug susceptibilities. The annual incidence of mastitis was 1.29 and 0.55 in the study and control farms, respectively, and the incidence ratio between the two farms was 2.35, which was significantly higher in the study farm. The antimicrobial agents used for mastitis treatment at the study farm were cephalosporin-based, and consisted of 70.2 g of CEZ intramammary infusion and 129 g of CEZ systemic injection to the intramammary for off-label use. Only intramammary infusions were used on the control farm, and CEZ was administered at a dose of 12.9 g. Per head of the study farm enrollment, the amount of CEZ intramammary infusion and intramammary injectants used (4.6 g) was more than 5 times that of the control farm (0.89 g), and approximately 2.6 times the standard dosage of CEZ intramammary infusion for lactation (0.15 g/dose per container × 4 mammary glands × 3 days = 1.8 g) for cattle with 4 affected mammary glands. Also, the MIC values for CEZ of *M. haemolytica* isolated from the control farm were low. Thus, it can be inferred that excessive use of CEZ was one of the factors responsible for the decreased susceptibility of *M. haemolytica* in the study farm. Another factor could be the external invasion of CEZ low-susceptible *M. haemolytica*. However, it was inferred that it was unlikely to have been introduced from this farm, as only individuals raised on the control farm were introduced.

Key words : antimicrobial usage, drug susceptibility, *Mannheimia haemolytica*, intramammary therapy

Jpn. J. Anim. Hyg. 47, 85～90 (2021)

出典　http://www.kachiku-eisei.jp/
最終責任者　Ayano Sato (Corresponding Author)

Veterinary Immunology and Immunopathology 244 (2022) 110364

Contents lists available at ScienceDirect

Veterinary Immunology and Immunopathology

journal homepage: www.elsevier.com/locate/vetimm

Research paper

Effects of intra-articular inoculation with *Mycoplasma bovis* on immunological responses in calf joints

Koji Nishi [a,b], Yuki Hirano [a,c], Ayano Sato [d], Ayako Eguchi [a], Kazuya Matsuda [e], Miyuki Toda [e], Takafumi Watanabe [f], Tomohito Iwasaki [g], Naoki Takahashi [h], Marina Hosotani [f], Reina Watanabe [a], Toshihide Kato [d], Hiromichi Ohtsuka [d], Satoshi Gondaira [a,*], Hidetoshi Higuchi [a,*]

[a] Animal Health Laboratory, Department of Veterinary Science, School of Veterinary Medicine, Rakuno Gakuen University, Ebetsu, Hokkaido, Japan
[b] NOSAI Okhotsk Monbetsu Veterinary Clinic, Monbetsu, Hokkaido, Japan
[c] Animal Research Center, Agricultural Research Department, Hokkaido Research Organization, Shintoku, Hokkaido, Japan
[d] Large Animal Clinical Science, Department of Veterinary Science, School of Veterinary Medicine, Rakuno Gakuen University, Ebetsu, Hokkaido, Japan
[e] Department of Veterinary Pathology, Department of Veterinary Science, School of Veterinary Medicine, Rakuno Gakuen University, Ebetsu, Hokkaido 069-8501, Japan
[f] Laboratory of Veterinary Anatomy, School of Veterinary Medicine, Rakuno Gakuen University, Ebetsu, Hokkaido, Japan
[g] Department of Food Science and Human Wellness, College of Agriculture, Food and Environment Science, Rakuno Gakuen University, Hokkaido, Japan
[h] Department of Veterinary Anatomy, College of Bioresource Sciences, Nihon University, Fujisawa, Kanagawa, Japan

ARTICLE INFO

Keywords:
Arthritis
Inflammatory cytokines
Invasion
Matrix metalloproteinases
Mycoplasma bovis

ABSTRACT

Mycoplasma arthritis that caused by *Mycoplasma bovis* exhibit severe lameness. This disease is difficult to cure with antibiotics, but the detailed pathological mechanisms have not been fully clarified. In this study, we examined the effects of intra-articular inoculation with *M. bovis* on immunological responses in calf joints. We inoculated three calves each with *M. bovis* or phosphate buffer saline (control) into the right stifle joint and dissected them at 15 days postinoculation. *Mycoplasma bovis*–inoculated calves exhibited swelling of the stifle joint, increases in synovial fluid, fibrin deposition, and cartilage thinning. Intracellular *M. bovis* was detected in synovial tissues analyzed by immunohistochemistry and transmission electron microscopy. Messenger RNA expressions of interleukin (IL)-1β, IL-6, IL-8, IL-12p40, and IL-17A in synovial fluid cells and synovial tissues from *M. bovis*–inoculated calves were significantly higher than those from control calves. Protein levels of these cytokines in synovial fluid from *M. bovis*–inoculated calves were markedly higher than those from control calves. Our study clarified that inoculation with *M. bovis* into the stifle joint induced the production of inflammatory cytokines by synovial fluid cells and synovial tissues, causing a severe inflammatory response in joints. Additionally, *M. bovis* could invade cells in synovial tissues, which may have aided it in evading antibiotics and host immune surveillance.

出典　doi: org/10.1016/j.vetimm.2021.110364
https://www.sciencedirect.com/science/article/pii/S0165242721001823
最終責任者　Satoshi Gondaira and Hidetoshi Higucih (Corresponding Author)

動物生殖学（Theriogenology）

Tomochika Sugiura

Assistant Professor

助教　杉浦　智親

Ⅰ．筆頭または責任著者　＜First or Corresponding Author＞

Ⅱ．その他＜Others＞

1) Characterization of Reproductive Microbiota of Primiparous Cows During Early Postpartum Periods in the Presence and Absence of Endometritis.

Hayami Kudo, **Tomochika Sugiura**, Seiya Higashi, Kentaro Oka, Motomichi Takahashi, Shigeru Kamiya, Yutaka Tamura and Masaru Usui

Front. Vet. Sci., 18 October 2021.　doi: 10.3389/fvets.2021.736996

2) Blood haptoglobin measurement by Hemoglobin Binding Assay in cows with refractory mastitis.

Masaaki Nakamura, Yutaka Sawamukai, Gerry Amor Camer, Takeshi Koyama, Yoshitaka Matsui, **Tomochika Sugiura**, Hiroki Inoue, Masaharu Moriyoshi

Jpn. J. Anim. Hyg. 47, 105～110, 2021.　https://id.ndl.go.jp/bib/031847921

frontiers in Veterinary Science

ORIGINAL RESEARCH
published: 18 October 2021
doi: 10.3389/fvets.2021.736996

Characterization of Reproductive Microbiota of Primiparous Cows During Early Postpartum Periods in the Presence and Absence of Endometritis

Hayami Kudo[1,2], *Tomochika Sugiura*[3], *Seiya Higashi*[2], *Kentaro Oka*[2], *Motomichi Takahashi*[2], *Shigeru Kamiya*[2], *Yutaka Tamura*[1] *and Masaru Usui*[1]*

[1] Department of Health and Environmental Sciences, School of Veterinary Medicine, Rakuno Gakuen University, Hokkaido, Japan, [2] Research Department, R&D Division, Miyarisan Pharmaceutical Co., Ltd., Saitama, Japan, [3] Department of Large Animal Clinical Science, School of Veterinary Medicine, Rakuno Gakuen University, Hokkaido, Japan

OPEN ACCESS

Edited by:
Hasan Riaz,
COMSATS Institute of Information Technology, Pakistan

Reviewed by:
Ricardo Zanella,
The University of Passo Fundo, Brazil
Tara G. McDaneld,
Agricultural Research Service, United States Department of Agriculture (USDA), United States

***Correspondence:**
Masaru Usui
usuima@rakuno.ac.jp

Specialty section:
This article was submitted to Livestock Genomics, a section of the journal Frontiers in Veterinary Science

Received: *09 July 2021*
Accepted: *21 September 2021*
Published: *18 October 2021*

Citation:
Kudo H, Sugiura T, Higashi S, Oka K, Takahashi M, Kamiya S, Tamura Y and Usui M (2021) Characterization of Reproductive Microbiota of Primiparous Cows During Early Postpartum Periods in the Presence and Absence of Endometritis. Front. Vet. Sci. 8:736996. doi: 10.3389/fvets.2021.736996

Endometritis has a major impact on fertility in postpartum dairy cows. Since previous studies showed an association between reproductive microbiota and perinatal disease, we monitored both bovine uterine and vaginal microbiota in primiparous cows to elucidate the effect of early postpartum microbiota on endometritis. Uterine and vaginal samples were collected at time points from pre-calving to 35 days postpartum (DPP), and analyzed by 16S rRNA sequencing, combined with ancillary bacterial culture. A total of seven healthy cows and seven cows diagnosed with endometritis on 35 DPP were used in the current study. The uterine and vaginal microbiota showed a maximum of 20.1% shared amplicon sequence variants (ASVs) at linked time points. 16S rRNA based analysis and traditional culture methods revealed that *Trueperella* showed a higher abundance in both uterus and vagina of the endometritis group compared to the healthy group on 21 DPP (*U*-test $p < 0.05$). Differential abundance analysis of the uterine microbiota showed that *Enterococcus* and six bacterial genera including *Bifidobacterium* were unique to the healthy group on the day of calving (0 DPP) and 28 DPP, respectively. In contrast, *Histophilus* and *Mogibacteriaceae* were characteristic bacteria in the vagina pre-calving in cows that later developed endometritis, suggesting that these bacteria could be valuable to predict clinical outcomes. Comparing the abundances of bacterial genera in the uterine microbiota, a negative correlation was observed between *Trueperella* and several bacteria including *Lactobacillus*. These results suggest that building an environment where there is an increase in bacteria that are generally recognized as beneficial, such as *Lactobacillus*, may be one possible solution to reduce the abundance of *Trueperella* and control endometritis.

Keywords: endometritis, reproductive tract microbiota, *Trueperella pyogenes*, early postpartum periods, probiotics

出典　doi: 10.3389/fvets.2021.736996
https://doi.org/10.3389/fvets.2021.736996
最終責任者　Masaru Usui (Corresponding Author)

Note

Blood haptoglobin measurement by Hemoglobin Binding Assay in cows with refractory mastitis

Masaaki Nakamura [1)*], Yutaka Sawamukai [2)], Gerry Amor Camer [3)], Takeshi Koyama [4)], Yoshitaka Matsui [5)], Tomochika Sugiura [6)], Hiroki Inoue [6)], Masaharu Moriyoshi [6)]

Summary

Blood haptoglobin (Hp) is one of the major acute phase proteins in cows that is akin to C-reactive proteins as it is recognizably used in dogs and in humans. Hp as an inflammatory marker can be measured in veterinary laboratories using Hemoglobin Binding Assay (HBA) using methemoglobin reagent. In this study, Hp in 16 cattle but with only one mastitis-infected quarter were measured for eight serial days from initial diagnosis (Day 1) by HBA. Hp fluctuations or patterns after antibiotic treatments along with the somatic cell counts (SCC) in milk were measured on Day 1 and Day 8. Positive bacterial culture in milk on Day 8 (PO Group) with Hp median of ≥ 500 μg/ml was detected for 8 days of observation. Pathogenic bacteria remained in PO milk even at Day 8. The median Hp of cattle on Day 8 (NE Group), with negative bacterial culture in milk, that responded to antibiotic treatment showed downtrend fluctuations between 6 and 8 days of observation. This continued until it turned out negative for bacterial culture at Day 8. The Hp of PO was significantly higher than the NE from Day 7 and 8 ($P<0.01$ and <0.01). However, the SCC of both groups showed no significant difference at Days 1 and 8. Since blood Hp remains to be elevated even after antibiotic treatments in PO with an affected quarter, we suggest that bovine Hp measurements be considered as one of the alternative test items in detecting refractory mastitis that is showing resistance to antibiotic treatments.

Key words : Cow, Haptoglobin, Hemoglobin Binding Assay, refractory mastitis

Jpn. J. Anim. Hyg. 47, 105～110 (2021)

出典　https://id.ndl.go.jp/bib/031832233

最終責任者　Masaaki Nakamura (Corresponding Author)

獣医伴侶内科学（Companion Animal Internal Medicine）

Masahiro Tamura

Assistant Professor

助教　田村　昌大

Ⅰ．筆頭または責任著者　＜First or Corresponding Author＞

1）Extrahepatic biliary obstruction can interfere with hepatic fibrosis prediction using two-dimensional shear wave elastography in dogs.
Tamura M, Ohta H, Osuga, T, Sasaki N, Morishita K, Takiguchi M.
Veterinary Radiology and Ultrasound 62: 483−489. 2021.
doi:10.1111/vru.12969

Received: 7 June 2020 | Revised: 25 December 2020 | Accepted: 9 February 2021

DOI: 10.1111/vru.12969

Viruses 2019, 11, 613

WILEY

ORIGINAL INVESTIGATION

Extrahepatic biliary obstruction can interfere with hepatic fibrosis prediction using two-dimensional shear wave elastography in dogs

Masahiro Tamura[1] | **Hiroshi Ohta**[2] | **Tatsuyuki Osuga**[1] | **Noboru Sasaki**[2] | **Keitaro Morishita**[1] | **Mitsuyoshi Takiguchi**[2]

[1] Veterinary Teaching Hospital, Graduate school of Veterinary Medicine, Hokkaido University, Sapporo, Hokkaido, Japan

[2] Laboratory of Veterinary Internal Medicine, Department of Veterinary Clinical Sciences, Graduate School of Veterinary Medicine, Hokkaido University, Hokkaido, Japan

Correspondence
Mitsuyoshi Takiguchi, Laboratory of Veterinary Internal Medicine, Department of Veterinary Clinical Sciences, Graduate School of Veterinary Medicine, Hokkaido University, N18 W9, Sapporo, Hokkaido 060-0818, Japan.
Email: mtaki@vetmed.hokudai.ac.jp

Abstract

Two-dimensional shear wave elastography (2D-SWE) can be used to quantitatively evaluate the elastic modulus of the liver as shear wave velocity (SWV), which can noninvasively predict clinically relevant hepatic fibrosis in both dogs and humans. However, extrahepatic biliary obstruction (EHBO), regardless of the presence of clinically relevant hepatic fibrosis, can influence SWVs in humans and thus may interfere with hepatic fibrosis prediction using 2D-SWE in dogs. The aim of this prospective, observational, and one-group pretest–posttest study is to investigate whether SWV measured by 2D-SWE displays a difference between dogs with and without EHBO. A total of 20 dogs were included (7 with EHBO and 13 with gallbladder pathology but no EHBO) that underwent preoperative SWV measurement using 2D-SWE. In all dogs, stages of hepatic fibrosis were evaluated histopathologically using a scoring scheme. In addition, postoperative SWVs in dogs with EHBO relieved via laparotomy were also evaluated. The median (range) SWVs in the dogs with and without EHBO were 1.91 (1.81–2.54) m/s and 1.57 (1.37–1.64) m/s, respectively. Although there was no significant difference in the histopathological hepatic fibrosis stages between the dogs with and without EHBO, the preoperative SWVs in the dogs with EHBO were significantly higher than in dogs without EHBO ($P = .0004$), and SWVs were found to decrease significantly after surgery ($P = .0097$). This study demonstrates that EHBO can increase the SWV of dogs without clinically relevant hepatic fibrosis and can interfere with the prediction of noninvasive hepatic fibrosis using 2D-SWE.

KEYWORDS
acoustic radiation force impulse, canine, icterus, jaundice, viscosity

出典　doi: 10.1111/vru.12969
https://onlinelibrary.wiley.com/doi/10.1111/vru.12969

最終責任者　Mitsuyoshi Takiguchi (Corresponding Author)

獣医解剖学（Veterinary Anatomy）

Marina Hosotani

Assistant professor

助教　細谷　実里奈

Ⅰ．筆頭または責任著者　＜First or Corresponding Author＞

1) The unique physiological features of the broiler pectoralis major muscle as suggested by the three-dimensional ultrastructural study of mitochondria in type IIb muscle fibers.
Hosotani M, Kametani K, Ohno N, Hiramatsu K, Kawasaki T, Hasegawa Y, Iwasaki T, Watanabe T.
J Vet Med Sci. 83:1764-1771. 2021. doi: 10.1292/jvms.21-0408

2) Unique histological features of the tail skin of cotton rat (*Sigmodon hispidus*) related to caudal autotomy.
Hosotani M, Nakamura T, Ichii O, Irie T, Sunden Y, Elewa YHA, Watanabe T, Ueda H, Mishima T, Kon Y.
Biol Open. 10:bio058230. 2021. doi: 10.1242/bio.058230

Ⅱ．その他＜Others＞

1) Cotton rats (*Sigmodon hispidus*) with a high prevalence of hydrocephalus without clinical symptoms.
Kondoh D, Nakamura T, Tsuji E, **Hosotani M**, Ichii O, Irie T, Mishima T, Nagasaki K, Kon Y.
Neuropathology. 2021. doi: 10.1111/neup.12776

2) Effects of intra-articular inoculation with Mycoplasma bovis on immunological responses in calf joints.
Nishi K, Hirano Y, Sato A, Eguchi A, Matsuda K, Toda M, Watanabe T, Iwasaki T, Takahashi N, **Hosotani M**, Watanabe R, Kato T, Ohtsuka H, Gondaira S, Higuchi H.
Vet Immunol Immunopathol. 110364-110364. 2021. doi: 10.1016/j.vetimm.2021.110364

3) Close Association Between Altered Urine-urothelium Barrier and Tertiary Lymphoid Structure Formation in the Renal Pelvis During Nephritis.
Ichii O, **Hosotani M**, Masum MA, Horino T, Nakamura T, Namba T, Otani Y, Elewa YHA, Kon Y.
J Am Soc Nephrol. Online ahead of print. 2021. doi: 10.1681/ASN.2021040575.

4) Novel polychrome staining distinguishing osteochondral tissue and bone cells in decalcified paraffin sections.
Nakamura T, Sumi K, Tsuji E, **Hosotani M**, Namba T, Ichii O, Irie T, Nagasaki K, Kon Y, Mishima T, Yoshiyasu T.
Cell Tissue Res. 385:727-737. 2021. doi: 10.1007/s00441-021-03516-6.

5) Compartmentalization of interleukin 36 subfamily according to inducible and constitutive expression in the kidneys of a murine autoimmune nephritis model.
Namba T, Ichii O, Nakamura T, Masum MA, Otani Y, **Hosotani M**, Elewa YHA, Kon Y.
Cell Tissue Res. 386:59–77. 2021. doi: 10.1007/s00441-021-03495-8

J Vet Med Sci. 2021, 83:1764-1771

The Journal of Veterinary Medical Science

FULL PAPER

Anatomy

The unique physiological features of the broiler pectoralis major muscle as suggested by the three-dimensional ultrastructural study of mitochondria in type IIb muscle fibers

Marina HOSOTANI[1)], Kiyokazu KAMETANI[1)], Nobuhiko OHNO[2,3)], Kohzy HIRAMATSU[4)], Takeshi KAWASAKI[5)], Yasuhiro HASEGAWA[6)], Tomohito IWASAKI[6)]* and Takafumi WATANABE[1)]*

[1)]Department of Veterinary Anatomy, School of Veterinary Medicine, Rakuno Gakuen University, Ebetsu, Hokkaido 069-8501, Japan

[2)]Division of Ultrastructural Research, National Institute for Physiological Science, Okazaki, Aichi 444-8585, Japan

[3)]Division of Histology and Cell Biology, Department of Anatomy, Jichi Medical University, Shimotsuke, Tochigi 329-0498, Japan

[4)]Laboratory of Animal Functional Anatomy (LAFA), Faculty of Agriculture, Shinshu University, Kami-ina, Nagano 399-4598, Japan

[5)]Research Office Concerning the Health of Humans and Birds, Abashiri, Hokkaido 099-3119, Japan

[6)]Department of Food Science and Human Wellness, College of Agriculture, Food and Environment Science, Rakuno Gakuen University, Ebetsu, Hokkaido 069-8501, Japan

ABSTRACT. Typical skeletal muscles are composed of mixed muscle fiber types, which are classified as slow-twitch (type I) and fast-twitch (type II) fibers, whereas pectoralis major muscles (PMs) in broiler chickens are 100% composed of type IIb fast-twitch fibers. Since metabolic properties differ among muscle fiber types, the combination of muscle fiber types is involved in physiological functions and pathological conditions in skeletal muscles. In this study, using serial block-face scanning electron microscopy, we compared three-dimensional (3D) mitochondrial properties in type IIb fibers in broiler PMs and those in type I fibers of broiler gastrocnemius muscles (GMs) heterogeneously composed of slow- and fast-twitch muscle fibers. In type I fibers in the GMs, elongated mitochondria with numerous interconnections to form a substantial network among myofibrils were observed. Along with lipid droplets sandwiched by mitochondria, these features are an adaptation to effective oxidative respiration and constant oxidative damage in slow-twitch muscle fibers. In contrast, type IIb fibers in the PMs showed small and ellipsoid-shaped mitochondria with few interconnections and no lipid droplets, forming a sparse network. The mitochondrial spatial network comprises of active mitochondrial dynamics to reduce mitochondrial damage; therefore, type IIb fibers possess physiologically low capacity to maintain mitochondrial wellness due to static mitochondrial dynamics. Based on 3D mitochondrial properties, we discussed the contrasting physiological functions between type I and IIb fibers and proposed a high contractile power and low stress resistance as unique physiological properties of broiler PMs.

KEY WORDS: 3D reconstruction, mitochondria, slow-/fast-twitch muscle, ultrastructure, wooden breast syndrome

J. Vet. Med. Sci.
83(11): 1764–1771, 2021
doi: 10.1292/jvms.21-0408

Received: 21 July 2021
Accepted: 5 September 2021
Advanced Epub:
15 September 2021

出典　doi: 10.1292/jvms.21-0408
https://www.ncbi.nlm.nih.gov/pmc/articles/PMC8636870/

最終責任者　Tomohito Iwasaki and Takafumi Watanabe (Corresponding Author)

Biol Open. 2021, 10:bio058230.

© 2021. Published by The Company of Biologists Ltd | Biology Open (2021) 10, bio058230. doi:10.1242/bio.058230

RESEARCH ARTICLE

Unique histological features of the tail skin of cotton rat (*Sigmodon hispidus*) related to caudal autotomy

Marina Hosotani[1,*], Teppei Nakamura[2,3,*,‡], Osamu Ichii[2,4], Takao Irie[5,6], Yuji Sunden[7], Yaser Hosny Ali Elewa[2,8], Takafumi Watanabe[1], Hiromi Ueda[1], Takashi Mishima[3] and Yasuhiro Kon[2]

ABSTRACT

Caudal autotomy in rodents is an evolutionarily acquired phenomenon enabling escape from predators, by discarding the tail skin after traumatic injuries. The histological mechanisms underlying caudal autotomy seem to differ among species. Cotton rats (*Sigmodon hispidus*), which are important laboratory rodents for human infectious diseases, possess a fragile tail. In this study, we compared the tail histology of cotton rats with that of laboratory rats (*Rattus norvegicus*), which have no fragility on their tail, to elucidate the process of rodent caudal autotomy. First, the cotton rats developed a false autotomy characterized by loss of the tail sheath with the caudal vertebrae remaining without tail regeneration. Second, we found the fracture plane was continuous from the interscale of the tail epidermis to the dermis, which was lined with an alignment of E-cadherin$^+$ cells. Third, we found an obvious cleavage plane between the dermis and subjacent tissues of the cotton-rat tail, where the subcutis was composed of looser, finer, and fragmented collagen fibers compared with those of the rat. Additionally, the cotton-rat tail was easily torn, with minimum bleeding. The median coccygeal artery of the cotton rat had a thick smooth muscle layer, and its lumen was filled with the peeled intima with fibrin coagulation, which might be associated with reduced bleeding following caudal autotomy. Taken together, we reveal the unique histological features of the tail relating to the caudal autotomy process in the cotton rat, and provide novel insights to help clarify the rodent caudal autotomy mechanism.

KEY WORDS: Cotton rat, Rat, Caudal autotomy, Tail histology, Collagen

[1]Laboratory of Veterinary Anatomy, Department of Veterinary Medicine, School of Veterinary Medicine, Rakuno Gakuen University, Ebetsu, Hokkaido 069-8501, Japan. [2]Laboratory of Anatomy, Department of Basic Veterinary Science, Faculty of Veterinary Medicine, Hokkaido University, Sapporo, Hokkaido, Japan. [3]Department of Biological Safety Research, Chitose Laboratory, Japan Food Research Laboratories, Chitose, Hokkaido, Japan. [4]Laboratory of Agrobiomedical Science, Faculty of Agriculture, Hokkaido University, Sapporo, Hokkaido, Japan. [5]Medical Zoology Group, Department of Infectious Diseases, Hokkaido Institute of Public Health, Sapporo, Hokkaido, Japan. [6]Laboratory of Veterinary Parasitic Diseases, Department of Veterinary Sciences, Faculty of Agriculture, Center for Animal Disease Control, University of Miyazaki, Miyazaki, Japan. [7]Laboratory of Veterinary Pathology, Faculty of Agriculture, Tottori University, Tottori 680-8550, Japan. [8]Department of Histology and Cytology, Faculty of Veterinary Medicine, Zagazig University, Zagazig, Egypt.
*These authors contributed equally to this work

‡Author for correspondence (nakamurate@vetmed.hokudai.ac.jp)

M.H., 0000-0003-0360-3360; T.N., 0000-0003-3204-0245; O.I., 0000-0002-6643-1554; T.I., 0000-0002-8733-0832; Y.K., 0000-0002-6859-6122

This is an Open Access article distributed under the terms of the Creative Commons Attribution License (https://creativecommons.org/licenses/by/4.0), which permits unrestricted use, distribution and reproduction in any medium provided that the original work is properly attributed.

Received 27 November 2020; Accepted 15 January 2021

INTRODUCTION

Autotomy, the phenomenon of discarding or shedding a part of the body, is preserved in some animal species and is generally considered a self-defense mechanism to escape from predators (Emberts et al., 2019). In vertebrates, many lizards are well known as species that can undergo autotomy of the tail, which is followed by subsequent regeneration (Zani, 1996). In mammals, several species of rodents have been reported to possess autotomy of the tail related to predator avoidance as well (Shargal et al., 1999). For example, spiny mice (*Acomys cahirinus*), eastern chipmunks (*Tamias striatus*), and degu (*Octodon degus*) shed their tail skin easily in response to traumatic injuries (Shargal et al., 1999). In contrast with the true autotomy in reptiles, where the entire tail including the caudal vertebra is lost, most instances of autotomy in rodents have been considered a false autotomy, where the tail skin is lost but the vertebra remains (Dubost and Gasc, 1987).

Autotomy in rodents has been reported in five families and at least 27 species, although the precise histology related to the autotomy mechanism varies among species (Shargal et al., 1999). The autotomy process in rodents includes two stages: rupture, and healing of tissue. Specifically for the former, in spiny mice, greater space occupied by hair follicles in the dermis and less absolute connective tissue have been associated with decreased skin elasticity (Seifert et al., 2012). However, the autotomy mechanism has been poorly understood in rodents, except for the spiny mouse, which has been well investigated because of their unique systemic regenerative ability of the injured skin (Shargal et al., 1999; Seifert et al., 2012). In particular, the lack of histological observations on the tail skin in rodents has made it difficult to understand the rupture process of tissue and the variety and/or similarity of mechanisms underlying caudal autotomy among species.

The cotton rat (*Sigmodon hispidus*) is a rodent that is distributed over most of the southern USA. They are classified in the family Cricetidae (with hamsters and gerbils) and belong to a different family from the laboratory rat (*Rattus norvegicus*) and the laboratory mouse (*Mus musculus*), which are classified as Muridae (Coe and Prince, 1996). The cotton rat has been selected as a laboratory animal model in the field of infectious research because it can faithfully reproduce human infectious diseases (Boukhvalova et al., 2009). In addition to its utility in infectious disease research, to date we have reported interesting systemic pathological phenotypes of cotton rats, including chronic kidney disease, chronic anemia, and metabolic disorders (Ichii et al., 2016, 2018, 2020; Nakamura et al., 2019). In addition, the interesting characteristics of cotton rats include a fragile tail (i.e. autotomy); they therefore should not be captured by the tail, as they may spin and shed the tail skin to run away (Faith et al., 1977). Hence, cotton rats can be a useful laboratory animal not only to explore several human diseases but also to investigate the mechanisms underlying the expression of biological characteristics in animals, such as caudal autotomy.

出典　doi: 10.1242/bio.058230
https://journals.biologists.com/bio/article/10/2/bio058230/237276/Unique-histological-features-of-the-tail-skin-of

最終責任者　Teppei Nakamura (Corresponding Author)

NEUROPATHOLOGY

Neuropathology 2021 doi:10.1111/neup.12776

Original Article

Cotton rats (*Sigmodon hispidus*) with a high prevalence of hydrocephalus without clinical symptoms

Daisuke Kondoh,[1]* Teppei Nakamura,[2,3]* Erika Tsuji,[3] Marina Hosotani,[4] Osamu Ichii,[2,5] Takao Irie,[6,7] Takashi Mishima,[3] Ken-ichi Nagasaki[8] and Yasuhiro Kon[2]

[1]Laboratory of Veterinary Anatomy, Department of Veterinary Medicine, Obihiro University of Agriculture and Veterinary Medicine, Obihiro, Laboratory of [2]Anatomy, Department of Basic Veterinary Science, Faculty of Veterinary Medicine, [5]Agrobiomedical Science, Faculty of Agriculture, Hokkaido University, [6]Medical Zoology Group, Department of Infectious Diseases, Hokkaido Institute of Public Health, Sapporo, [3]Department of Biological Safety Research, Chitose Laboratory, Japan Food Research Laboratories, Chitose, [4]Laboratory of Veterinary Anatomy, Department of Veterinary Medicine, School of Veterinary Medicine, Rakuno Gakuen University, Ebetsu, [7]Laboratory of Veterinary Parasitic Diseases, Department of Veterinary Sciences, Faculty of Agriculture, University of Miyazaki, Miyazaki and [8]Department of Biological Safety Research, Tama Laboratory, Japan Food Research Laboratories, Tama, Japan

Normal-pressure hydrocephalus (NPH) is a condition in which the ventricle is enlarged without elevated cerebrospinal fluid pressure, and it generally develops in later life and progresses slowly. A complete animal model that mimics human idiopathic NPH has not yet been established, and the onset mechanisms and detailed pathomechanisms of NPH are not fully understood. Here, we demonstrate a high spontaneous prevalence (34.6%) of hydrocephalus without clinical symptoms in inbred cotton rats (*Sigmodon hispidus*). In all 46 hydrocephalic cotton rats, the severity was mild or moderate and not severe. The dilation was limited to the lateral ventricles, and none of the hemorrhage, ventriculitis, meningitis, or tumor formation was found in hydrocephalic cotton rats. These findings indicate that the type of hydrocephalus in cotton rats is similar to that of communicating idiopathic NPH. Histopathological examinations revealed that the inner granular and pyramidal layers (layers IV and V) of the neocortex became thinner in hydrocephalic brains. A small number of pyramidal cells were positive for Fluoro-Jade C (a degenerating neuron marker) and ionized calcium-binding adaptor molecule 1 (Iba1)-immunoreactive microglia were in contact with the degenerating neurons in the hydrocephalic neocortex, suggesting that hydrocephalic cotton rats are more or less impaired projections from the neocortex. This study highlights cotton rats as a candidate for novel models to elucidate the pathomechanism of idiopathic NPH. Additionally, cotton rats have some noticeable systemic pathological phenotypes, such as chronic kidney disease and metabolic disorders. Thus, this model might also be useful for researching the comorbidities of NPH to other diseases.

Key words: brain ventricle, ependymal cells, neocortex, pyramidal cells, rodents.

INTRODUCTION

Hydrocephalus is a clinical condition characterized by an increase in the volume of cerebrospinal fluid (CSF) within the cranial vault, which lowers the quality of life and can even be life-threatening. Isaacs *et al.* summarized 52 published studies from more than 170 million population; the incidence of hydrocephalus is 8.12/10 000 at birth, and the overall global prevalence is 8.47/10 000.[1] The prevalence of hydrocephalus in children (≤ 18 years), adults (19–64 years), and elderly (≥ 65 years) is 8.78/10 000, 1.09/10 000, and 17.48/10 000, respectively,[1] indicating that both congenital and acquired cases of hydrocephalus are critical. The onset mechanisms of hydrocephalus can be divided into obstructive and communicating forms. Ventricular obstruction is the most common mechanism of congenital hydrocephalus,[2] whereas acquired hydrocephalus is caused by both obstructive factors, namely, the mass effect of tumors, and communicating factors, such as dysfunctional subarachnoid space, CSF overproduction, CSF absorption failure, and decreased venous compliance.[2]

Correspondence: Teppei Nakamura, DVM, PhD, Laboratory of Anatomy, Department of Basic Veterinary Science, Faculty of Veterinary Medicine, Hokkaido University, Kita 18, Nishi 9, Kita-ku, Sapporo, Hokkaido 060-0818, Japan. Email: nakamurate@vetmed.hokudai.ac.jp

*These two authors equally contributed to this study.

Received 14 April 2021; revised and accepted 10 August 2021.

© 2021 Japanese Society of Neuropathology.

出典 doi: 10.1111/neup.12776

https://onlinelibrary.wiley.com/doi/10.1111/neup.12776

最終責任者 Teppei Nakamura (Corresponding Author)

Vet Immunol Immunopathol. 2021, 110364-110364.

Journal Pre-proof



Effects of intra-articular inoculation with *Mycoplasma bovis* on immunological responses in calf joints

Koji Nishi, Yuki Hirano, Ayano Sato, Ayako Eguchi, Kazuya Matsuda, Miyuki Toda, Takafumi Watanabe, Tomohito Iwasaki, Naoki Takahashi, Marina Hosotani, Reina Watanabe, Toshihide Kato, Hiromichi Ohtsuka, Satoshi Gondaira, Hidetoshi Higuchi

PII: S0165-2427(21)00182-3

DOI: https://doi.org/10.1016/j.vetimm.2021.110364

Reference: VETIMM 110364

To appear in: *Veterinary Immunology and Immunopathology*

Received Date: 8 June 2021

Revised Date: 27 November 2021

Accepted Date: 4 December 2021

Please cite this article as: { doi: https://doi.org/

This is a PDF file of an article that has undergone enhancements after acceptance, such as the addition of a cover page and metadata, and formatting for readability, but it is not yet the definitive version of record. This version will undergo additional copyediting, typesetting and review before it is published in its final form, but we are providing this version to give early visibility of the article. Please note that, during the production process, errors may be discovered which could affect the content, and all legal disclaimers that apply to the journal pertain.

© 2020 Published by Elsevier.

出典　doi: 10.1016/j.vetimm.2021.110364
https://www.sciencedirect.com/science/article/pii/S0165242721001823?via%3Dihub

最終責任者　Hidetoshi Higuchi (Corresponding Author)

Basic Research

Close Association between Altered Urine–Urothelium Barrier and Tertiary Lymphoid Structure Formation in the Renal Pelvis during Nephritis

Osamu Ichii, Marina Hosotani, Md. Abdul Masum, Taro Horino, Yuki Otani, Takashi Namba, Teppei Nakamura, Elewa Yaser Hosny Ali and Yasuhiro Kon

JASN December 2021, ASN.2021040575; DOI: https://doi.org/10.1681/ASN.2021040575

Add to Cart ($32)

Article | Figures & Data Supps | Info & Metrics | View PDF

This article requires a subscription to view the full text. If you have a subscription you may use the login form below to view the article. Access to this article can also be purchased.

Visual Abstract

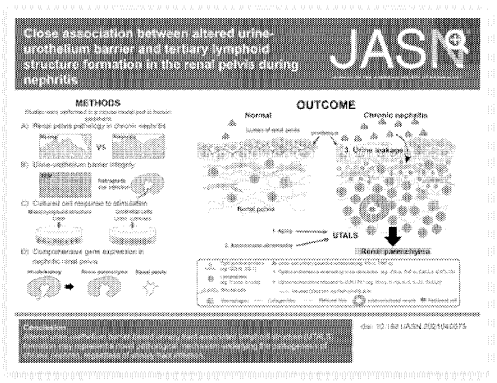

In this issue



Journal of the American Society of Nephrology
Vol. 32, Issue 12
December 2021
Table of Contents
Table of Contents (PDF)
About the Cover
Index by author

View Selected Citations (0)

Print
Download PDF
Sign up for Alerts
Email Article
Citation Tools
Request Permissions
Share

出典　doi: 10.1681/ASN.2021040575
https://jasn.asnjournals.org/content/early/2021/12/11/ASN.2021040575

最終責任者　Osamu Ichii (First and Corresponding Author)

Cell and Tissue Research (2021) 385:727–737
https://doi.org/10.1007/s00441-021-03516-6

REGULAR ARTICLE

Novel polychrome staining distinguishing osteochondral tissue and bone cells in decalcified paraffin sections

Teppei Nakamura[1,2] · Kanako Sumi[1] · Erika Tsuji[1] · Marina Hosotani[3] · Takashi Namba[2] · Osamu Ichii[2,4] · Takao Irie[5,6] · Ken-ichi Nagasaki[7] · Yasuhiro Kon[2] · Takashi Mishima[1] · Tomoji Yoshiyasu[1]

Received: 28 April 2021 / Accepted: 26 July 2021 / Published online: 19 August 2021
© The Author(s), under exclusive licence to Springer-Verlag GmbH Germany, part of Springer Nature 2021

Abstract

The bone is a dynamic and metabolically active organ in which growth and resorption of the osteochondral matrix is orchestrated by osteoblasts and osteoclasts. For decalcified paraffin-embedded specimens, decalcifying agents alter the staining intensity, and excess decalcification interferes with bone staining. Robust bone staining methods independent of the decalcification conditions and animal species are lacking. In this study, we have developed a novel polychrome staining method, named JFRL staining, which stains the components of osteochondral tissue in different colors. With this staining we could visualize the hyaline cartilage as blue by alcian blue, osteoid as red by picrosirius red, and mineralized bone as green by picro-light green SF or picro-naphthol green B and easily distinguished osteoblasts, osteocytes, and osteoclasts. In mineralized bone, this staining revealed the obvious lamellar structures and woven bone. Notably, this staining was independent of the decalcification conditions and experimental animal species examined. To verify the usefulness of JFRL staining, we observed cotton rat tail which has shorter length and shows a false autotomy. The caudal vertebrae were normally developed via endochondral ossification without a fracture plane. At 6 months of age, the number of chondrocytes declined and the hypertrophic zone was absent at the epiphyseal plate, which might reflect the shorter tail. In conclusion, JFRL staining is the first method to simultaneously distinguish osteochondral matrix and bone cells in one section regardless of decalcifying conditions. This robust staining will provide new information for a wide number of biomedical fields, including bone development, physiology, and pathology.

Keywords Osteoid · Mineralized bone · Cartilage · Bone cells · Osteochondral staining

Introduction

Bone is a dynamic and metabolically active organ in which simultaneous growth and resorption of the bone matrix is orchestrated by osteoblasts and osteoclasts under hormonal regulation. The bone is formed via two pathways: intramembranous ossification and endochondral ossification (Gilbert 2000). During development, flat bones are formed by intramembranous ossification, where osteoblasts differentiate directly from mesenchymal stem cells to form the bone matrix. In

✉ Teppei Nakamura
nakamurate@jfrl.or.jp

[1] Department of Biological Safety Research, Chitose Laboratory, Japan Food Research Laboratories, Hokkaido, Chitose 066-0052, Japan

[2] Laboratory of Anatomy, Department of Basic Veterinary Sciences, Faculty of Veterinary Medicine, Hokkaido University, Hokkaido, Sapporo 060-0818, Japan

[3] Laboratory of Veterinary Anatomy, Department of Veterinary Medicine, School of Veterinary Medicine, Rakuno Gakuen University, Ebetsu, Hokkaido 069-8501, Japan

[4] Laboratory of Agrobiomedical Science, Faculty of Agriculture, Hokkaido University, Sapporo, Hokkaido 060-0818, Japan

[5] Medical Zoology Group, Department of Infectious Diseases, Hokkaido Institute of Public Health, Sapporo, Hokkaido 060-0818, Japan

[6] Laboratory of Veterinary Parasitology, Faculty of Agriculture, University of Miyazaki, Miyazaki 889-2192, Japan

[7] Department of Biological Safety Research, Tama Laboratory, Japan Food Research Laboratories, Tokyo, Tama 206-0025, Japan

出典　doi: 10.1007/s00441-021-03516-6
https://link.springer.com/article/10.1007/s00441-021-03516-6
最終責任者　Teppei Nakamura (First and Corresponding Author)

Cell and Tissue Research (2021) 386:59–77
https://doi.org/10.1007/s00441-021-03495-8

REGULAR ARTICLE

Compartmentalization of interleukin 36 subfamily according to inducible and constitutive expression in the kidneys of a murine autoimmune nephritis model

Takashi Namba[1] · Osamu Ichii[1,2] · Teppei Nakamura[1,3] · Md. Abdul Masum[1,4] · Yuki Otani[1] · Marina Hosotani[5] · Yaser Hosny Ali Elewa[1,6] · Yasuhiro Kon[1]

Received: 19 January 2021 / Accepted: 21 June 2021 / Published online: 21 July 2021
© The Author(s), under exclusive licence to Springer-Verlag GmbH Germany, part of Springer Nature 2021

Abstract

The interleukin (IL) 36 subfamily belongs to the IL-1 family and is comprised of agonists (IL-36α, IL-36β, IL-36γ) and antagonists (IL-36Ra, IL-38). We previously reported IL-36α overexpression in renal tubules of chronic nephritis mice. To understand the localization status and biological relationships among each member of the IL-36 subfamily in the kidneys, MRL/MpJ-*Fas*$^{lpr/lpr}$ mice were investigated as autoimmune nephritis models using pathology-based techniques. MRL/MpJ-*Fas*$^{lpr/lpr}$ mice exhibited disease onset from 3 months and severe nephritis at 6–7 months (early and late stages, respectively). Briefly, IL-36γ and IL-36Ra were constitutively expressed in murine kidneys, while the expression of IL-36α, IL-36β, IL-36Ra, and IL-38 was induced in MRL/MpJ-*Fas*$^{lpr/lpr}$ mice. IL-36α expression was significantly increased and localized to injured tubular epithelial cells (TECs). CD44^{+}-activated parietal epithelial cells (PECs) also exhibited higher IL-36α-positive rates, particularly in males. IL-36β and IL-38 are expressed in interstitial plasma cells. Quantitative indices for IL-36α and IL-38 positively correlated with nephritis severity. Similar to IL-36α, IL-36Ra localized to TECs and PECs at the late stage; however, MRL/MpJ-*Fas*$^{lpr/lpr}$ and healthy MRL/MpJ mice possessed IL-36Ra^{+} smooth muscle cells in kidney arterial tunica media at both stages. IL-36γ was constitutively expressed in renal sympathetic axons regardless of strain and stage. IL-36 receptor gene was ubiquitously expressed in the kidneys and was induced proportional to disease severity. MRL/MpJ-*Fas*$^{lpr/lpr}$ mice kidneys possessed significantly upregulated IL-36 downstream candidates, including NF-κB- or MAPK-pathway organizing molecules. Thus, the IL-36 subfamily contributes to homeostasis and inflammation in the kidneys, and especially, an IL-36α-dominant imbalance could strongly impact nephritis deterioration.

Keywords Nephritis · Systemic autoimmune disease · Chronic kidney disease · Inflammatory cytokine · Interleukin 36

Abbreviations

Actb	Beta-actin
α-SMA	Alpha smooth muscle actin
BUN	Blood urea nitrogen
CKD	Chronic kidney disease
Cr	Creatinine
dsDNA	Double-stranded DNA
DT	Distal tubule
GO	Gene ontology
HNF-4α	Hepatic nuclear factor 4, alpha

✉ Osamu Ichii
ichi-o@vetmed.hokudai.ac.jp

[1] Laboratory of Anatomy, Department of Basic Veterinary Sciences, Faculty of Veterinary Medicine, Hokkaido University, Sapporo, Hokkaido 060-0818, Japan

[2] Laboratory of Agrobiomedical Science, Faculty of Agriculture, Hokkaido University, Sapporo, Hokkaido 060-8589, Japan

[3] Section of Biological Safety Research, Chitose Laboratory, Japan Food Research Laboratories, Chitose, Hokkaido 066-0052, Japan

[4] Department of Anatomy, Histology and Physiology, Faculty of Animal Science and Veterinary Medicine, Sher-E-Bangla Agricultural University, Dhaka 1207, Bangladesh

[5] Laboratory of Veterinary Anatomy, Department of Veterinary Medicine, Rakuno Gakuen University, Ebetsu, Hokkaido 069-8501, Japan

[6] Department of Histology and Cytology, Faculty of Veterinary Medicine, Zagazig University, Zigazig 44519, Egypt

出典　doi: 10.1007/s00441-021-03495-8
https://link.springer.com/article/10.1007%2Fs00441-021-03495-8
最終責任者　Osamu Ichii (Corresponding Author)

画像診断学（Veterinary Diagnostic Imaging）

Ai Hori

Assistant Professor

助教　堀　あい

Ⅰ．筆頭または責任著者　＜First or Corresponding Author＞

Ⅱ．その他＜Others＞

1）The effects of gel pad thickness on the evaluation of skin structures using ultrasonography in normal dogs
Sothavy Chhay, Kiwamu Hanazono, Jo Kitahara, **Ai Hori**, Kenjiro Miyoshi, Takaharu Itami, Daiji Endoh, Tetsuya Nakade.
J Vet Med Sci. 83:1472-1475. 2021. doi: 10.1292/jvms.21-0086

2）Effects of gel pad thickness on skin stiffness evaluation by ultrasonographic strain elastography in normal dogs
Sothavy Chhay, Kiwamu Hanazono, Jo Kitahara, **Ai Hori**, Kenjiro Miyoshi, Takaharu Itami, Daiji Endo, Tetsuya Nakade.
JJVR. 69: 125-134. 2021. doi: https://doi.org/10.14943/jjvr.69.2.125

The Journal of Veterinary Medical Science

NOTE

Internal Medicine

The effects of gel pad thickness on the evaluation of skin structures using ultrasonography in normal dogs

Sothavy CHHAY[1)], Kiwamu HANAZONO[1,2)*], Jo KITAHARA[1)], Ai HORI[2)], Kenjiro MIYOSHI[1,2)], Takaharu ITAMI[1,2)], Daiji ENDOH[1)] and Tetsuya NAKADE[1,2)]

[1)]School of Veterinary Medicine, Rakuno Gakuen University, 582 Bunkyodai Midorimach, Ebetsu, Hokkaido 069-8501, Japan

[2)]Animal Medical Center, Rakuno Gakuen University, 582 Bunkyodai Midorimach, Ebetsu, Hokkaido 069-8501, Japan

J. Vet. Med. Sci.
83(9): 1472–1475, 2021
doi: 10.1292/jvms.21-0086

Received: 15 February 2021
Accepted: 14 July 2021
Advanced Epub:
26 July 2021

ABSTRACT. Gel pads are commonly used in skin ultrasonography; however, the effects of their thickness are unknown. This study investigated the effects of pad thickness on measurements of skin thickness in 10 beagle dogs. Sonograms to measure neck skin thickness were captured without pads and using pads with thicknesses of 3, 5, 10, and 20 mm. Without pads, acoustic shading was observed due to air bubbles in the coupling gel. With 20-mm pads, echogenic artifacts were observed on the skin surface. Entry echo with 20-mm pads was significantly higher than with 3-mm pads. This suggests that visibility of the skin structure could be affected when a gel pad is not used or when a thick gel pad is selected.

KEY WORDS: artifact, gel pad, normal dog, skin thickness, skin ultrasonography

出典　doi:10.1292/jvms.21-0086
https://www.ncbi.nlm.nih.gov/pubmed/34305079

最終責任者　Kiwamu Hanazono (Corresponding Author)

Japanese Journal of Veterinary Research 69(2): 125-134, 2021

JJVR

REGULAR PAPER Experimental Research

Effects of gel pad thickness on skin stiffness evaluation by ultrasonographic strain elastography in normal dogs

Sothavy Chhay[1)], Kiwamu Hanazono[2,3,*)], Jo Kitahara[1)], Ai Hori[3)], Kenjiro Miyoshi[1,3)], Takaharu Itami[1,3)], Daiji Endoh[2)] and Tetsuya Nakade[1,3)]

[1)] Department of Small Animal Clinical Sciences, School of Veterinary Medicine, Rakuno Gakuen University, 582 Bunkyodai Midorimach, Ebetu-shi, Hokkaido 069-8501, Japan
[2)] Department of Biosciences, School of Veterinary Medicine, Rakuno Gakuen University, Ebetsu, Hokkaido 069-8501, Japan
[3)] Animal Medical Center, Rakuno Gakuen University, 582 Bunkyodai Midorimach, Ebetu-shi, Hokkaido 069-8501, Japan

Received for publication, November 8, 2020; accepted, February 25, 2021

Abstract

Gel pads are commonly used for skin ultrasound examination; however, the effect of their thickness on the measured values is unknown. We investigated the effect of pad thickness on skin stiffness measurement in healthy dogs. The skin stiffness of the dorsal neck was measured using a durometer. Ultrasonographic strain elastography was performed with 5-, 10-, and 20-mm-thick pads. Among the strain ratios, muscle/skin (5 mm) showed a significantly positive correlation with skin stiffness. In the strain histogram, AREA (20 mm), CONTRAST (20 mm), MEAN (5, 20 mm), and STANDARD DEVIATION (20 mm) were significantly correlated with skin stiffness. In conclusion, the thickness of the gel pad affects the measurements during skin ultrasonographic strain elastography.

Key Words: Gel pad, normal dog, skin ultrasonography, ultrasonographic strain elastography

出典 doi: 10.14943/jjvr.69.2.125
https://doi.org/10.14943/jjvr.69.2.125

最終責任者 Kiwamu Hanazono (Corresponding Author)

獣医生理学（Veterinary Physiology）

Taiki Moriya

Assistant professor

助教　守屋　大樹

Ⅰ．筆頭または責任著者　＜First or Corresponding Author＞

1）Immunogenic tumor cell death promotes dendritic cell migration and inhibits tumor growth via enhanced T cell immunity.
Moriya T, Kitagawa K, Hayakawa Y, Hemmi H, Kaisho T, Ueha S, Ikebuchi R, Yasuda I, Nakanishi Y, Honda T, Matsushima K, Kabashima K, Ueda M, Kusumoto Y, Chtanova T, Tomura M.
iScience 24(5):102424. 2021 doi: 10.1016/j.isci.2021.102424.

Ⅱ．その他＜Others＞

1) Gut microorganisms induce Peyer's patch-dependent maternal IgA production in milk.
Usami K, Niimi K, Matsuo A, Suyama Y, Sakai Y, Sato S, Fujihashi K, Kiyono H, Uchino S, Furukawa M, Islam J, **Moriya T**, Kusumoto Y, Tomura M, C. Hovey R, Sugawara J, Yoneyama H, Kitazawa H, Watanabe K, Aso H, Nochi T.
Cell Reports. 36(10):109655. 2021. doi: 10.1016/j.celrep.2021.109655.

2) Cutting Edge: Recruitment, Retention, and Migration Underpin Functional Phenotypic Heterogeneity of Regulatory T Cells in Tumors.
Ikebuchi R, **Moriya T**, Ueda M, Yasuda I, Kusumoto Y, Chtanova T, Tomura M.
Journal of Immunology. 207(3):771-776. 2021.
doi: 10.4049/jimmunol.2001083.

3) Tracking the fate and migration of cells in live animals with cell-cycle indicators and photoconvertible proteins.
Tomura M, Ikebuchi R, **Moriya T**, Kusumoto Y.
Journal of Neuroscience Methods. 355:109127. 2021.
doi: 10.1016/j.jneumeth.2021.109127.

iScience

CellPress
OPEN ACCESS

Article

Immunogenic tumor cell death promotes dendritic cell migration and inhibits tumor growth via enhanced T cell immunity

Taiki Moriya,[1] Kurumi Kitagawa,[1] Yuuki Hayakawa,[1] Hiroaki Hemmi,[2] Tsuneyasu Kaisho,[2] Satoshi Ueha,[3] Ryoyo Ikebuchi,[1,4] Ippei Yasuda,[1] Yasutaka Nakanishi,[1] Tetsuya Honda,[5] Koji Matsushima,[3] Kenji Kabashima,[5] Mizuki Ueda,[1] Yutaka Kusumoto,[1] Tatyana Chtanova,[6,7] and Michio Tomura[1,8,*]

SUMMARY

Immunogenic tumor cell death enhances anti-tumor immunity. However, the mechanisms underlying this effect are incompletely understood. We established a system to induce tumor cell death *in situ* and investigated its effect on dendritic cell (DC) migration and T cell responses using intravital photolabeling in mice expressing KikGR photoconvertible protein. We demonstrate that tumor cell death induces phagocytosis of tumor cells by tumor-infiltrating (Ti)-DCs, and HMGB1-TLR4 and ATP-P2X7 receptor signaling-dependent Ti-DC emigration to draining lymph nodes (dLNs). This led to an increase in anti-tumor $CD8^+$ T cells of memory precursor effector phenotype and secondary tumor growth inhibition in a $CD103^+$ DC-dependent manner. However, combining tumor cell death induction with lipopolysaccharide treatment stimulated Ti-DC maturation and emigration to dLNs but did not improve tumor immunity. Thus, immunogenic tumor cell death enhances tumor immunity by increasing Ti-DC migration to dLNs where they promote anti-tumor T cell responses and tumor growth inhibition.

出典　doi:10.1016/j.isci.2021.102424.
https://www.sciencedirect.com/science/article/pii/S2589004221003928?via%3Dihub 最終責任者　Michio Tomura (Corresponding Author)

Cell Reports

CellPress
OPEN ACCESS

Article

The gut microbiota induces Peyer's-patch-dependent secretion of maternal IgA into milk

Katsuki Usami,[1] Kanae Niimi,[1] Ayumi Matsuo,[1] Yoshihisa Suyama,[1] Yoshifumi Sakai,[1] Shintaro Sato,[2,3,4] Kohtaro Fujihashi,[4,5] Hiroshi Kiyono,[6,7,8] Saeka Uchino,[1] Mutsumi Furukawa,[1] Jahidul Islam,[1] Kaori Ito,[1] Taiki Moriya,[9] Yutaka Kusumoto,[9] Michio Tomura,[9] Russell C. Hovey,[10] Junichi Sugawara,[11] Hiroshi Yoneyama,[1] Haruki Kitazawa,[1] Kouichi Watanabe,[1] Hisashi Aso,[1] and Tomonori Nochi[1,12,13,*]

[1]International Education and Research Center for Food and Agricultural Immunology, Graduate School of Agricultural Science, Tohoku University, Miyagi 980-8572, Japan

[2]Mucosal Vaccine Project, BIKEN Innovative Vaccine Research Alliance Laboratories, Research Institute for Microbial Diseases, Osaka University, Osaka 565-0871, Japan

[3]Development of Immunology and Genomics, Graduate School of Medicine, Osaka City University, Osaka 545-8585, Japan

[4]Division of Clinical Vaccinology, International Research and Development Center for Mucosal Vaccines, The Institute of Medical Science, The University of Tokyo, Tokyo 108-8639, Japan

[5]Department of Pediatric Dentistry, The University of Alabama at Birmingham, Birmingham, AL 35294, USA

[6]IMSUT Distinguished Professor Unit, Division of Mucosal Immunology, The Institute of Medical Science, The University of Tokyo, Tokyo 108-8639, Japan

[7]Department of Immunology, Graduate School of Medicine, Chiba University, Chiba 260-8670, Japan

[8]Department of Medicine, School of Medicine and CU-UCSD Center for Mucosal Immunology, Allergy & Vaccines, University of California, San Diego, San Diego, CA 92093, USA

[9]Laboratory of Immunology, Faculty of Pharmacy, Osaka Ohtani University, Osaka 584-8540, Japan

[10]Department of Animal Science, University of California, Davis, Davis, CA 95616, USA

[11]Tohoku Medical Megabank Organization, Tohoku University, Miyagi 980-8573, Japan

[12]Division of Mucosal Vaccines, International Research and Development Center for Mucosal Vaccines, The Institute of Medical Science, The University of Tokyo, Tokyo 108-8639, Japan

[13]Lead contact

*Correspondence: nochi@tohoku.ac.jp

https://doi.org/10.1016/j.celrep.2021.109655

SUMMARY

The evolutionary strategy of transferring maternal antibodies via milk profoundly impacts the survival, lifelong health, and wellbeing of all neonates, including a pronounced impact on human breastfeeding success and infant development. While there has been increased recognition that interorgan connectivity influences the quality of a mother's milk, potentially to personalize it for her offspring, the underlying bases for these processes are incompletely resolved. Here, we define an essential role of Peyer's patches (PPs) for the generation of plasma cells that secrete maternal immunoglobulin A (IgA) into milk. Our metagenomic analysis reveals that the presence of certain residential microorganisms in the gastrointestinal (GI) tract, such as *Bacteroides acidifaciens* and *Prevotella buccalis*, is indispensable for the programming of maternal IgA synthesis prior to lactational transfer. Our data provide important insights into how the microbiome of the maternal GI environment, specifically through PPs, can be communicated to the next generation via milk.

出典　doi:10.1016/j.celrep.2021.109655.

https://www.sciencedirect.com/science/article/pii/S2211124721010986?via%3Dihub

最終責任者　Tomonori Nochi (Corresponding Author)

Cutting Edge

The Journal of Immunology

Cutting Edge: Recruitment, Retention, and Migration Underpin Functional Phenotypic Heterogeneity of Regulatory T Cells in Tumors

Ryoyo Ikebuchi,*,† Taiki Moriya,* Mizuki Ueda,* Ippei Yasuda,*,‡ Yutaka Kusumoto,* Tatyana Chtanova,§,¶ and Michio Tomura*

Tumor-infiltrating regulatory T cells (Tregs) have been extensively studied as therapeutic targets. However, not all infiltrating T cells exert their functions equally, presumably because of their heterogeneity and substantial turnover in tissues. In this study, we hypothesized that intertissue migration underlies the functional heterogeneity of Tregs. To test this, we applied in vivo photolabeling to examine single-cell diversity of immunosuppressive molecules in mouse Tregs migrating to, remaining in, and emigrating from MC38 tumors. Neuropilin-1 (Nrp1) expression was inversely correlated with that of six other molecules associated with Treg function. Unsupervised clustering analyses revealed that clusters containing Tregs that were retained in tumors expressed high levels of the six functional molecules but not of Nrp1. However, these clusters represented only half of the Tregs migrating to the tumor, suggesting evolving heterogeneity of tumor-infiltrating Tregs. Thus, we propose progressive pathways of Treg activation and migration between tumors and draining lymph nodes. *The Journal of Immunology*, 2021, 207: 771–776.

Regulatory T cells (Tregs) play essential roles in tissue homeostasis, autoimmunity control, chronic infection, and cancer (1). In lymphoid tissues, Tregs display well characterized immunoinhibitory mechanisms, whereas in nonlymphoid tissues, Tregs mediate tissue-specific immunoinhibition (2). For example, Treg-specific deletion of the immunosuppressive cytokine IL-10 or surface molecule CTL-associated protein 4 (CTLA-4) causes peripheral or systemic immune disorders (1). In several cancers, Tregs infiltrating tumors exhibit more suppressive signatures than Tregs in lymphoid tissues (3) and use more than 10 molecules to suppress immunity (2). However, single-cell functional diversity (4) complicates the investigation of Treg function in both lymphoid and nonlymphoid tissues.

Treg tissue tropism is well characterized. CCR4 mediates Treg recruitment to the tumor sites, lung tissue, and skin (5). In tumors and inflamed tissues, Tregs strongly express other migration molecules, such as CCR5, CCR8, and integrins β1 and αE (3, 6). Although previous reports focused on tissue-infiltrating Tregs, it is likely that only a proportion of them are retained in tissues to mediate immune regulation. Tissue adaptation through the expression of T helper–inducing POZ/Krüeppel–like factor (ThPOK) is required for Tregs to reside in their preferred microenvironments in the intestine (7). Furthermore, our established photoconvertible protein-expressing mice revealed rapid Treg replacement in the inflamed tissue and tumors via emigration to draining lymph nodes (dLNs) (8, 9).

In this study, we investigated Treg function and residence in nonlymphoid pathological tissues by focusing on single-cell Treg functional heterogeneity and intertissue migration between the dLN and tumor. We used mice expressing a photoconvertible protein, KikGR (10), to distinguish the Tregs migrating (Mig) to, remaining (Rem) in tumors, and emigrating (Emi) to dLNs. We identified partially overlapping functional heterogeneity between Treg subpopulations with specific migratory profiles and Treg clusters that were enriched in Rem Tregs and defined by distinct expression profiles of immunoinhibitory molecules.

Downloaded from http://www.jimmunol.org/ at Rakuno Gakuen University on December 23, 2021

出典　doi:10.4049/jimmunol.2001083.
https://www.jimmunol.org/content/207/3/771.long

最終責任者　Michio Tomura (Corresponding Author)

Journal of Neuroscience Methods
Volume 355, 1 May 2021, 109127

Tracking the fate and migration of cells in live animals with cell-cycle indicators and photoconvertible proteins

Michio Tomura [a] ✉, Ryoyo Ikebuchi [a, b, c], Taiki Moriya [a], Yutaka Kusumoto [a]

Show more
+ Add to Mendeley Share Cite

https://doi.org/10.1016/j.jneumeth.2021.109127
Get rights and content

Highlights

- Cell cycle visualization of living cells and animals by Fucci system.
- *In situ* cell labeling and tracking cell migration by photoactivatable proteins.
- Combines tracking information on inter-tissue cell migration and single cell analysis.

Abstract

Cell migration and cell proliferation are the basic principles that make up a living organism, and both biologically and medically. In order to understand living organism and biological phenomena, it is essential to track the migration, proliferation, and fate of cells in living cells and animals and to clarify the properties and molecular expression of cells. Recent developments in novel fluorescent proteins have made it possible to observe cell migration and proliferation as the cell cycle at the single-cell level in living individuals and tissues. Here, we introduce cell cycle visualization of living cells and animals by Fucci (Fluorescent Ubiquitination-based Cell Cycle Indicator) system and *in situ* cell labeling of cells and tracking cell migration by photoactivatable and photoconvertible proteins. In addition, we will present our established methods as an example of combines above tools with single-cell molecular expression analysis to reveal the fate of migrating cells at single cell level.

出典　doi:10.1016/j.jneumeth.2021.109127.
https://www.sciencedirect.com/science/article/abs/pii/S0165027021000625
最終責任者　Michio Tomura (First Author and Corresponding Author)

動物生命科学（Animal Life Science）

Takio Kitazawa

Professor

教授　北澤多喜雄

Ⅰ．筆頭または責任著者　＜First or Corresponding Author＞

1) **Kitazawa T**, Kaiya H. Motilin Comparative Study: Structure, Distribution, Receptors, and Gastrointestinal Motility. Front Endocrinol (Lausanne). 2021 Aug 23;12:700884. doi: 10.3389/fendo.2021.700884. eCollection 2021
2) Zhang S, Teraoka H, Kaiya H, **Kitazawa T.** Motilin- and ghrelin-induced contractions in isolated gastrointestinal strips from three species of frogs. Gen Comp Endocrinol. 2021 Jan 1;300:113649. doi: 10.1016/j.ygcen.2020.113649.
3) Yoshikawa K, Tsubakishita S, Sano T, Ino T, Miyasaka T, **Kitazawa T.** Functional assessment of the gluteus medius, cranial part of the biceps femoris, and vastus lateralis in Beagle dogs based on a novel gait phase classification. J Vet Med Sci. 2021 Jan 14;83(1):116-124. doi: 10.1292/jvms.20-0127. Epub 2020 Nov 23
4) Zhang S, Kaiya H, Teraoka H, **Kitazawa T.** Pheasant motilin, its distribution and gastrointestinal contractility-stimulating action in the pheasant. Gen Comp Endocrinol. 2021 Dec 1;314:113897. doi: 10.1016/j.ygcen.2021.113897. Epub 2021 Sep 8.

Ⅱ．その他＜Others＞

1) Tanahashi Y, Komori S, Matsuyama H, **Kitazawa T**, Unno T.　Functions of Muscarinic Receptor Subtypes in Gastrointestinal Smooth Muscle: A Review of Studies with Receptor-Knockout Mice. Int J Mol Sci. 2021 Jan 18;22:926. doi: 10.3390/ijms22020926.
2) Tanaka K, Adachi H, Akasaka H, Tamaoki J, Fuse Y, Kobayashi M, **Kitazawa T**, Teraoka H. Oxidative stress inducers potentiate 2,3,7,8-tetrachlorodibenzo-p-dioxin-mediated pre-cardiac edema in larval zebrafish. J Vet Med Sci. 2021 Jul 2;83:1050-1058. doi: 10.1292/jvms.21-0081. Epub 2021 May 24.
3) Alexander SP, Christopoulos A, Davenport AP, Kelly E, Mathie A, Peters JA,

Veale EL, Armstrong JF, Faccenda E, Harding SD, Pawson AJ, Southan C, Davies JA, Abbracchio MP, Alexander W, Al-Hosaini K, Bäck M, Barnes NM, Bathgate R, Beaulieu JM, Bernstein KE, Bettler B, Birdsall NJM, Blaho V, Boulay F, Bousquet C, Bräuner-Osborne H, Burnstock G, Caló G, Castaño JP, Catt KJ, Ceruti S, Chazot P, Chiang N, Chini B, Chun J, Cianciulli A, Civelli O, Clapp LH, Couture R, Csaba Z, Dahlgren C, Dent G, Singh KD, Douglas SD, Dournaud P, Eguchi S, Escher E, Filardo EJ, Fong T, Fumagalli M, Gainetdinov RR, Gasparo M, Gerard C, Gershengorn M, Gobeil F, Goodfriend TL, Goudet C, Gregory KJ, Gundlach AL, Hamann J, Hanson J, Hauger RL, Hay DL, Heinemann A, Hollenberg MD, Holliday ND, Horiuchi M, Hoyer D, Hunyady L, Husain A, IJzerman AP, Inagami T, Jacobson KA, Jensen RT, Jockers R, Jonnalagadda D, Karnik S, Kaupmann K, Kemp J, Kennedy C, Kihara Y, **Kitazawa T,** Kozielewicz P, Kreienkamp HJ, Kukkonen JP, Langenhan T, Leach K, Lecca D, Lee JD, Leeman SE, Leprince J, Li XX, Williams TL, Lolait SJ, Lupp A, Macrae R, Maguire J, Mazella J, McArdle CA, Melmed S, Michel MC, Miller LJ, Mitolo V, Mouillac B, Müller CE, Murphy P, Nahon JL, Ngo T, Norel X, Nyimanu D, O'Carroll AM, Offermanns S, Panaro MA, Parmentier M, Pertwee RG, Pin JP, Prossnitz ER, Quinn M, Ramachandran R, Ray M, Reinscheid RK, Rondard P, Rovati GE, Ruzza C, Sanger GJ, Schöneberg T, Schulte G, Schulz S, Segaloff DL, Serhan CN, Stoddart LA, Sugimoto Y, Summers R, Tan VP, Thal D, Thomas WW, Timmermans PBMWM, Tirupula K, Tulipano G, Unal H, Unger T, Valant C, Vanderheyden P, Vaudry D, Vaudry H, Vilardaga JP, Walker CS, Wang JM, Ward DT, Wester HJ, Willars GB, Woodruff TM, Yao C, Ye RD. THE CONCISE GUIDE TO PHARMACOLOGY 2021/22: G protein-coupled receptors. Br J Pharmacol. 2021 Oct;178 Suppl 1:S27-S156. doi: 10.1111/bph.15538.

frontiers in Endocrinology

REVIEW
published: 23 August 2021
doi: 10.3389/fendo.2021.700884

Motilin Comparative Study: Structure, Distribution, Receptors, and Gastrointestinal Motility

Takio Kitazawa[1*] *and Hiroyuki Kaiya*[2]

[1] *Comparative Animal Pharmacology, Department of Veterinary Science, Rakuno Gakuen University, Ebetsu, Japan,*
[2] *Department of Biochemistry, National Cerebral and Cardiovascular Center Research Institute, Suita, Japan*

Motilin, produced in endocrine cells in the mucosa of the upper intestine, is an important regulator of gastrointestinal (GI) motility and mediates the phase III of interdigestive migrating motor complex (MMC) in the stomach of humans, dogs and house musk shrews through the specific motilin receptor (MLN-R). Motilin-induced MMC contributes to the maintenance of normal GI functions and transmits a hunger signal from the stomach to the brain. Motilin has been identified in various mammals, but the physiological roles of motilin in regulating GI motility in these mammals are well not understood due to inconsistencies between studies conducted on different species using a range of experimental conditions. Motilin orthologs have been identified in non-mammalian vertebrates, and the sequence of avian motilin is relatively close to that of mammals, but reptile, amphibian and fish motilins show distinctive different sequences. The MLN-R has also been identified in mammals and non-mammalian vertebrates, and can be divided into two main groups: mammal/bird/reptile/amphibian clade and fish clade. Almost 50 years have passed since discovery of motilin, here we reviewed the structure, distribution, receptor and the GI motility regulatory function of motilin in vertebrates from fish to mammals.

Keywords: motilin, motilin receptor, gastrointestinal contractility, enteric nerves, smooth muscle, vagus afferent nerves, comparative biology

OPEN ACCESS

Edited by:
Masayasu Kojima,
Kurume University, Japan

Reviewed by:
Elisa L. Hill-Yardin,
RMIT University, Australia
Joao Carlos dos Reis Cardoso,
University of Algarve, Portugal

***Correspondence:**
Takio Kitazawa
tko-kita@rakuno.ac.jp

Specialty section:
This article was submitted to Neuroendocrine Science, a section of the journal Frontiers in Endocrinology

Received: *27 April 2021*
Accepted: *16 July 2021*
Published: *23 August 2021*

Citation:
Kitazawa T and Kaiya H (2021) Motilin Comparative Study: Structure, Distribution, Receptors, and Gastrointestinal Motility. Front. Endocrinol. 12:700884. doi: 10.3389/fendo.2021.700884

INTRODUCTION

Motilin was identified in the 1970s from the mucosa of the porcine upper intestine as a stimulant of gastric motility (1–3). Brown and colleagues examined the effects of duodenal alkalinization on pressure of the gastric pouch and found that alkalinization caused an increase in pressure of the pouch. Since the pouch was isolated from the autonomic nerves, it was thought that alkalinization induced the release of substances from the duodenal mucosa that stimulate motility. Duodenal extracts of pigs were examined for their gastric motor-stimulating activity, and motilin was separated as a distinct polypeptide. Porcine motilin was found to be a 22-amino acid peptide with a primary sequence of FVPIFTYGEL QRMQEKERNKGQ (1–3). Later, the presence of motilin was shown, and its sequence was determined in rabbits (*Leporinae Trouessart*), humans (*Homo sapiens*), dogs (*Canis lupus familiaris*), cats (*Felis silvestris catus*), cows (*Bos taurus*) and sheep (*Ovis aries*). Although there are some differences in amino acid sequence, the N-terminal sequences are

出典: doi: 10.3389/fendo.2021.700884. https://doi.org/10.3389/fendo.2021.700884
最終責任者: Kitazawa T（First and Corresponding Author）

General and Comparative Endocrinology 300 (2021) 113649

Contents lists available at ScienceDirect

General and Comparative Endocrinology

journal homepage: www.elsevier.com/locate/ygcen

Research paper

Motilin- and ghrelin-induced contractions in isolated gastrointestinal strips from three species of frogs

Shuangyi Zhang [a], Hiroki Teraoka [a], Hiroyuki Kaiya [b], Takio Kitazawa [a,*]

[a] School of Veterinary Medicine, Rakuno Gakuen University, Ebetsu, Hokkaido 069-8501, Japan
[b] Department of Biochemistry, National Cerebral and Cardiovascular Center Research Institute, Suita, Osaka 564-8565, Japan

ARTICLE INFO

Keywords:
Amphibians
Frogs
Gastrointestinal contraction
Motilin
Ghrelin

ABSTRACT

Ghrelin (GHRL) and motilin (MLN), gut peptides isolated from the mucosa of the stomach and duodenum, respectively, stimulate gastrointestinal (GI) motility in mammals and birds. However, the functions of MLN and GHRL in amphibian GI tracts have not been examined in detail. To clarify the regulation of GI motility by the two peptides, the effects of human MLN and rat GHRL on contractility of isolated GI strips from three species of frogs, the black-spotted pond frog (pond frog; *Pelophylax nigromaculata*), bullfrog (*Lithobates catesbeiana*) and Western clawed frog (Xenopus; *Xenopus tropicalis*), were examined in *in vitro* experiments. The GI tract of each frog was divided into the stomach, upper intestine, middle intestine and lower intestine. Human MLN caused contractions of the stomach in the pond frog and upper intestine in the bullfrog and Xenopus, but other GI regions were insensitive to human MLN. Erythromycin did not cause contraction of the upper intestine of the bullfrog and Xenopus. Rat GHRL did not cause contraction of the stomach and small intestines in the pond frog and bullfrog, but it caused a concentration-dependent contraction in the stomach and upper intestine of Xenopus, while desacyl rat GHRL did not cause any contraction of them. In conclusion, human MLN caused the contraction of the stomach or upper intestine in the three species of frogs, but GHRL was effective only in the stomach and upper intestine of Xenopus. On the basis of these data, MLN but not GHRL causes the GI region-dependent contractions in the frogs.

出典: doi: 10.1016/j.ygcen.2020.113649. https://doi.org/10.1016/j.ygcen.2020.113649

最終責任者: Kitazawa T（Corresponding Author）

The Journal of Veterinary Medical Science

FULL PAPER
Surgery

Functional assessment of the gluteus medius, cranial part of the biceps femoris, and vastus lateralis in Beagle dogs based on a novel gait phase classification

Kazuyuki YOSHIKAWA[1)], Sae TSUBAKISHITA[2)], Tadashi SANO[1,2)], Takumi INO[3)], Tomoya MIYASAKA[3)] and Takio KITAZAWA[1,2)]*

[1)]Graduate School of Veterinary Medicine, Rakuno Gakuen University, Hokkaido 069-8501, Japan
[2)]Department of Veterinary Sciences, School of Veterinary Medicine, Rakuno Gakuen University, Hokkaido 069-8501, Japan
[3)]Department of Physical Therapy, School of Health Sciences, Hokkaido University of Science, Hokkaido 006-8585, Japan

ABSTRACT. In humans, walking analysis based on the gait phase classification has been used for interpretation of functional roles of different movements occurring at individual joints, and it is useful for establishing a rehabilitation plan. However, there have been few reports on canine gait phase classification, and this is one of the reasons for preventing progress in canine rehabilitation. In this study, we determined phases of the canine gait cycle (GC) on the basis of the phase classification for human gait. The canine GC was able to be divided into initial contact (IC) and the following 5 phases: loading response (LR), middle stance (MidSt), pre-swing (PSw), early swing (ESw), and late swing (LSw). Next, the hind limb joint angles of the hip, stifle and tarsal joints and results of surface electromyography of the gluteus medius (GM), cranial part of the biceps femoris (CBF) and vastus lateralis (VL) muscles in relation to the gait phases were analyzed. The activities of three muscles showed similar changes during walking. The muscle activities were high in the LR phase and then declined and reached a minimum in the PSw phase, but they increased and reached a peak in the LSw phase, which was followed by the LR phase. In conclusion, the multiphasic canine GC was developed by modification of the human model, and the GC phase-related changes in the muscle activity and joint angles suggested the functions of GM, CBF and VL muscles in walking.

KEY WORDS: dog, gait analysis, gait phase classification, rehabilitation, surface electromyography

J. Vet. Med. Sci.
83(1): 116–124, 2021
doi: 10.1292/jvms.20-0127

Received: 6 March 2020
Accepted: 28 October 2020
Advanced Epub:
23 November 2020

出典：doi: 10.1292/jvms.20-0127. https://doi.org/10.1292/jvms.20-0127
最終責任者: Kitazawa T（Corresponding Author）

Contents lists available at ScienceDirect

General and Comparative Endocrinology

journal homepage: www.elsevier.com/locate/ygcen

Research paper

Pheasant motilin, its distribution and gastrointestinal contractility-stimulating action in the pheasant

Shuangyi Zhang [a], Hiroyuki Kaiya [b], Hiroki Teraoka [a], Takio Kitazawa [b,*]

[a] School of Veterinary Medicine, Rakuno Gakuen University, Ebetsu, Hokkaido 069-8501, Japan
[b] Department of Biochemistry, National Cerebral and Cardiovascular Center Research Institute, Suita, Osaka 565-8565, Japan

ARTICLE INFO

Keywords:
Pheasant
Motilin
Distribution
Gastrointestinal tract
Contraction

ABSTRACT

Previously, pheasant motilin was identified as a 22-amino acid peptide with a sequence of FVPFFTQSDI QKMQEKERIK GQ. In the present study, the distribution of pheasant motilin mRNA was determined and compared with that of ghrelin, a motilin-related peptide. The effects of pheasant motilin on the cognate gastrointestinal (GI) muscle strips were also examined in an *in vitro* contraction study. The expression of pheasant motilin mRNA was highest in the small intestine (duodenum, jejunum and ileum), moderate in the colon and very low in the brain, lung, heart, pancreas, esophagus, proventriculus, gizzard and caecum, and this distribution was in contrast with that of ghrelin mRNA. Pheasant motilin caused contraction of the cognate GI tract in a region-dependent manner, similar to chicken motilin. The contraction in the small intestine was large and was not affected by atropine. In contrast, contraction in the proventriculus was small and was decreased by atropine. The crop and colon were insensitive to pheasant motilin. Neither GM109 nor MA2029, mammalian motilin receptor antagonists inhibited the contractions of pheasant motilin. Erythromycin was ineffective in the pheasant ileum, although it caused contraction of the rabbit duodenum. These results indicate that pheasant motilin caused contraction through an action on smooth muscles in the small intestine and an action on enteric cholinergic nerves in the proventriculus. This high responsiveness of the small intestine suggests that motilin is a regulator of small intestinal motility in avians, and the characteristic of the motilin receptor in the pheasant might be different from that in mammals, as is that in chickens.

出典: doi: 10.1016/j.ygcen.2021.113897. https://doi.org/10.1016/j.ygcen.2021.113897
最終責任者: Kitazawa　T（Corresponding Author）

International Journal of
Molecular Sciences

MDPI

Review

Functions of Muscarinic Receptor Subtypes in Gastrointestinal Smooth Muscle: A Review of Studies with Receptor-Knockout Mice

Yasuyuki Tanahashi [1], Seiichi Komori [2], Hayato Matsuyama [2], Takio Kitazawa [3] and Toshihiro Unno [2,*]

[1] Department of Advanced Life Sciences, Faculty of Life Sciences, Kyoto Sangyo University, Kyoto 603-8555, Japan; ytanavet@cc.kyoto-su.ac.jp
[2] Laboratory of Veterinary Pharmacology, Department of Veterinary Medicine, Faculty of Applied Biological Sciences, Gifu University, 1-1 Yanagido, Gifu 501-1193, Japan; gkyakuri@yahoo.co.jp (S.K.); mhayato@gifu-u.ac.jp (H.M.); tunno@gifu-u.ac.jp (T.U.)
[3] Department of Veterinary Science, Rakuno Gakuen University, Ebetsu, Hokkaido 069-8501, Japan; tko-kita@rakuno.ac.jp
* Correspondence: tunno@gifu-u.ac.jp; Tel.: +81-(0)-58-293-2941

Abstract: Parasympathetic signalling via muscarinic acetylcholine receptors (mAChRs) regulates gastrointestinal smooth muscle function. In most instances, the mAChR population in smooth muscle consists mainly of M_2 and M_3 subtypes in a roughly 80% to 20% mixture. Stimulation of these mAChRs triggers a complex array of biochemical and electrical events in the cell via associated G proteins, leading to smooth muscle contraction and facilitating gastrointestinal motility. Major signalling events induced by mAChRs include adenylyl cyclase inhibition, phosphoinositide hydrolysis, intracellular Ca^{2+} mobilisation, myofilament Ca^{2+} sensitisation, generation of non-selective cationic and chloride currents, K^+ current modulation, inhibition or potentiation of voltage-dependent Ca^{2+} currents and membrane depolarisation. A lack of ligands with a high degree of receptor subtype selectivity and the frequent contribution of multiple receptor subtypes to responses in the same cell type have hampered studies on the signal transduction mechanisms and functions of individual mAChR subtypes. Therefore, novel strategies such as genetic manipulation are required to elucidate both the contributions of specific AChR subtypes to smooth muscle function and the underlying molecular mechanisms. In this article, we review recent studies on muscarinic function in gastrointestinal smooth muscle using mAChR subtype-knockout mice.

Keywords: muscarinic receptor subtypes; knockout mouse; smooth muscle; gastrointestinal tract; non-selective cationic channels; signal transduction pathways

Citation: Tanahashi, Y.; Komori, S.; Matsuyama, H.; Kitazawa, T.; Unno, T. Functions of Muscarinic Receptor Subtypes in Gastrointestinal Smooth Muscle: A Review of Studies with Receptor-Knockout Mice. *Int. J. Mol. Sci.* **2021**, *22*, 926. https://doi.org/10.3390/ijms22020926

Academic Editor: Toshio Takahashi

Received: 28 December 2020
Accepted: 14 January 2021
Published: 18 January 2021

出典：doi: 10.3390/ijms22020926. https://doi.org/10.3390/ijms22020926
最終責任者；Unno T (Corresponding Author)

The Journal of Veterinary Medical Science

FULL PAPER
Toxicology

Oxidative stress inducers potentiate 2,3,7,8-tetrachlorodibenzo-*p*-dioxin-mediated pre-cardiac edema in larval zebrafish

Katsuki TANAKA[1)], Hikaru ADACHI[1)], Hironobu AKASAKA[1)], Junya TAMAOKI[2)], Yuji FUSE[2)], Makoto KOBAYASHI[2)], Takio KITAZAWA[1)] and Hiroki TERAOKA[1)]*

[1)]School of Veterinary Medicine, Rakuno Gakuen University, Ebetsu, Hokkaido 069-8501, Japan
[2)]Department of Molecular and Developmental Biology, Faculty of Medicine, University of Tsukuba, Tsukuba, Ibaraki 305-8575, Japan

ABSTRACT. We reported the involvement of oxidative stress and prostaglandins including thromboxane and prostacyclin in pre-cardiac edema (early edema) caused by 2,3,7,8-tetrachlorodibenzo-*p*-dioxin (TCDD). While the involvement of oxidative stress in TCDD-induced toxicity has been frequently reported, the mechanism of its action is still unclear. In the present study, oxidative stress inducers including paraquat, hydrogen peroxide (H_2O_2) and rotenone augmented early edema (edema) induced by a low concentration of TCDD (0.1 ppb) at 55 hr post fertilization (hpf), while each of them alone did not cause edema. Edema caused by TCDD plus oxidative stress inducers was almost abolished by antioxidants, an antagonist for thromboxane receptor (ICI-192,605) and an agonist for prostacyclin receptor (beraprost), suggesting that the site of action of these inducers was in the regular signaling pathway after activation of aryl hydrocarbon receptor type 2 (AHR2) by TCDD. Oxidative stress inducers also enhanced edema caused by an agonist for the thromboxane receptor (U46619), and the enhancement was also inhibited by antioxidants. Sulforaphane and auranofin, activators of Nrf2 that is a master regulator of anti-oxidative response, did not affect U46619-evoked edema but almost abolished TCDD-induced edema and potentiation by paraquat in both TCDD- and U46619-induced edema. Taken together, the results suggest that oxidative stress augments pre-cardiac edema caused by TCDD via activation of thromboxane receptor-mediated signaling in developing zebrafish. As paraquat and other oxidative stress inducers used also are environmental pollutants, interaction between dioxin-like compounds and exogenous source of oxidative stress should also be considered.

KEY WORDS: dioxin, edema, oxidative stress, prostaglandin, zebrafish

J. Vet. Med. Sci.
83(7): 1050–1058, 2021
doi: 10.1292/jvms.21-0081

Received: 14 February 2021
Accepted: 10 May 2021
Advanced Epub:
24 May 2021

出典：doi: 10.1292/jvms.21-0081. https://doi.org/10.1292/jvms.21-0081
最終責任者: Teraoka H（Corresponding Author）

Br J Pharmacol. 2021 Oct;178 Suppl 1:S27-S156. doi: 10.1111/bph.15538.

THE CONCISE GUIDE TO PHARMACOLOGY 2021/22: G protein-coupled receptors

Abstract

The Concise Guide to PHARMACOLOGY 2021/22 is the fifth in this series of biennial publications. The Concise Guide provides concise overviews, mostly in tabular format, of the key properties of nearly 1900 human drug targets with an emphasis on selective pharmacology (where available), plus links to the open access knowledgebase source of drug targets and their ligands (www.guidetopharmacology.org), which provides more detailed views of target and ligand properties. Although the Concise Guide constitutes over 500 pages, the material presented is substantially reduced compared to information and links presented on the website. It provides a permanent, citable, point-in-time record that will survive database updates. The full contents of this section can be found at http://onlinelibrary.wiley.com/doi/bph.15538. G protein-coupled receptors are one of the six major pharmacological targets into which the Guide is divided, with the others being: ion channels, nuclear hormone receptors, catalytic receptors, enzymes and transporters. These are presented with nomenclature guidance and summary information on the best available pharmacological tools, alongside key references and suggestions for further reading. The landscape format of the Concise Guide is designed to facilitate comparison of related targets from material contemporary to mid-2021, and supersedes data presented in the 2019/20, 2017/18, 2015/16 and 2013/14 Concise Guides and previous Guides to Receptors and Channels. It is produced in close conjunction with the Nomenclature and Standards Committee of the International Union of Basic and Clinical Pharmacology (NC-IUPHAR), therefore, providing official IUPHAR classification and nomenclature for human drug targets, where appropriate.

© 2021 The Authors. British Journal of Pharmacology published by John Wiley & Sons Ltd on behalf of The British Pharmacological Society.

出典：doi:10.1111/bph.15538.　https://doi.org/10.1111/bph.15538

最終責任者：Motilin receptor の部分を Sanger G and Kitazawa T で共著

Hideaki Hayashi

Professor

教授　林　英明

Ⅰ．筆頭または責任著者　＜First or Corresponding Author＞

1) Effect of Growth and Parturition on Hair Cortisol in Holstein Cattle.
Hayashi H, Arai C, Ikeuchi Y, Yamanaka M, Hirayama T.
Anim Sci J. 92(1):e13518. 2021.
doi: 10.1111/asj.13518.

Ⅱ．その他＜Others＞

1) Forestomach developmental failure in an 11-month-old Japanese Black steer with severely retarded growth and chronic ruminal tympany.
Ono T, Hisaeda K, Inoue Y, Yamada Y, Shibano K, Mitsui I, Henmi C, Une Y, **Hayashi H**, Roh S, Nohara M, Uchida E, Nagahata H.
J Vet Med Sci. 83(2):220-225. 2021.
DOI: 10.1292/jvms.20-0448

2) Messenger RNA expression and localization of xenin in the gastrointestinal tract in sheep.
Onaga T, Sakai A, Kajita M, Fukuda H, Yasui Y, **Hayashi H**.
Domest Anim Endocrinol. 77: 106635. 2021.
DOI: 10.1016/j.domaniend.2020.106523

Received: 6 October 2020 | Revised: 18 December 2020 | Accepted: 6 January 2021

DOI: 10.1111/asj.13518

ORIGINAL ARTICLE

Animal Science Journal WILEY

Effect of growth and parturition on hair cortisol in Holstein cattle

Hideaki Hayashi[1] | Chigusa Arai[1] | Yurie Ikeuchi[1] | Maho Yamanaka[2] | Takuji Hirayama[2]

[1]Department of Veterinary Medicine, School of Veterinary Medicine, Rakuno Gakuen University, Ebetsu, Hokkaido, Japan

[2]School of Bioresources and Environmental Science, Ishikawa Prefectural University, Nonoichi City, Ishikawa, Japan

Correspondence
Hideaki Hayashi, Department of Veterinary Medicine, School of Veterinary Medicine, Rakuno Gakuen University, 582 Bunkyodai-Midorimachi, Ebetsu, Hokkaido 069-8501, Japan.
Email: hhayashi@rakuno.ac.jp

Funding information
JSPS KAKENHI, Grant/Award Number: JP15K21314; Northern Advancement Center for Science & Technology

Abstract

The effect of growth and parturition on hair cortisol concentrations of cattle was investigated. Plasma, saliva, and hair (black and white from the shoulders and hip) samples were collected from calves at 6 and 24 weeks old and from dairy cattle at the dry (1 and 2 months prepartum) and lactation (10, 50, 150, and 250 days postpartum) periods. Plasma and saliva cortisol concentrations were lower in 24-week-old calves than those of 6-week-old calves, and hair cortisol concentrations decreased regardless of color and position. In 6-week-old calves, hair cortisol concentrations differed between sampling positions, but this difference was not observed in 24-week-old calves. Plasma and saliva cortisol concentrations increased before parturition until 10 days postpartum then decreased until 50 days postpartum. The same trend was observed in the cortisol concentrations of white hair. Contrarily, cortisol concentrations in black hair remained unchanged and was lower than that in white hair. Hair cortisol concentration can vary greatly depending on the location on the body, hair color, cattle age, or parturition. When this method is used, all of the above factors must be considered.

KEYWORDS
cattle, cortisol, hair, parturition, stress

出典　doi: 10.1111/asj.13518.
https://onlinelibrary.wiley.com/doi/10.1111/asj.13518

最終責任者　Hideaki Hayashi (First Author and Corresponding Author)

The Journal of Veterinary Medical Science

NOTE

Internal Medicine

Forestomach developmental failure in an 11-month-old Japanese Black steer with severely retarded growth and chronic ruminal tympany

Tetsushi ONO[1], Keiichi HISAEDA[2], Yoichi INOUE[1], Yutaka YAMADA[1], Kenichi SHIBANO[1], Ikki MITSUI[3], Chizuka HENMI[3], Yumi UNE[3], Hideaki HAYASHI[4], Sanggun ROH[5], Masakatsu NOHARA[2], Eiji UCHIDA[2] and Hajime NAGAHATA[2]*

[1]Farm Animal Medicine, Faculty of Veterinary Medicine, Okayama University of Science, Ikoinooka 1-3, Imabari, Ehime 794-8555, Japan
[2]Department of Veterinary Associated Science, Faculty of Veterinary Medicine, Okayama University of Science, Ikoinooka 1-3, Imabari, Ehime 794-8555, Japan
[3]Veterinary Pathology, Faculty of Veterinary Medicine, Okayama University of Science, Ikoinooka 1-3, Imabari, Ehime 794-8555, Japan
[4]Veterinary Physiology, School of Veterinary Medicine, Rakuno Gakuen University, Bunkyodai-Midori 582, Ebetsu, Hokkaido 069-8501, Japan
[5]Laboratory of Animal Physiology, Graduate School of Agricultural Science, Tohoku University, Aoba, Sendai, Miyagi 980-8572, Japan

J. Vet. Med. Sci.
83(2): 220–225, 2021
doi: 10.1292/jvms.20-0448

Received: 27 July 2020
Accepted: 10 December 2020
Advanced Epub:
21 January 2021

ABSTRACT. This study reports findings from the pathological examination of the forestomach of an 11-month-old Japanese Black steer with severely retarded growth (41% of expected weight) and chronic ruminal tympany. The ruminal papillae were weakly formed (0.3–0.5 cm long) and unevenly distributed. The cellulae and cristae reticuli were underdeveloped; the cristae were 0.4–0.7 cm in height and milky white. The keratinized layer in the stratified squamous epithelium was thickened. Ruminal pH was 5.25, and ruminal volatile fatty acid concentration was 11.7 mM. The steer's severely retarded growth was considered to be caused by malnutrition due to developmental and functional failure of the forestomach.

KEY WORDS: chronic ruminal tympany, developmental failure, Japanese Black steer, ruminal papillae

出典　doi: 10.1292/jvms.20-0448.
http://jsvetsci.jp/jvms/vol-83-no-2-february-2021/

最終責任者　Hajime Nagahata (Corresponding Author)

Domestic Animal Endocrinology 74 (2021) 106523

Contents lists available at ScienceDirect

Domestic Animal Endocrinology

journal homepage: www.journals.elsevier.com/domestic-animal-endocrinology

Messenger RNA expression and localization of xenin in the gastrointestinal tract in sheep

T. Onaga[a,*], A. Sakai[a], M. Kajita[a], H. Fukuda[a], Y. Yasui[a], H. Hayashi[b]

[a] Laboratory of Veterinary Physiology and Nutrition, Division of Biosciences, Department of Veterinary Medicine, School of Veterinary Medicine, Rakuno Gakuen University, 582 Bunkyodai-Midorimachi, Ebetsu, Hokkaido, 069-8501, Japan
[b] Laboratory of Veterinary Physiology, Division of Biosciences, Department of Veterinary Medicine, School of Veterinary Medicine, Rakuno Gakuen University, 582 Bunkyodai-Midorimachi, Ebetsu, Hokkaido, 069-8501, Japan

ARTICLE INFO

Article history:
Received 9 March 2019
Received in revised form 27 April 2020
Accepted 10 July 2020

Keywords:
Sheep
Gastrointestinal tract
Endocrine cells
Colocalization
GIP

ABSTRACT

The present study aimed to determine the primary sequence of ovine xenin and clarify the mRNA expression and peptide localization of xenin in the gastrointestinal tract in sheep. The colocalization of xenin and glucose-dependent insulinotropic polypeptide was also compared in the antrum and duodenum. Analysis of the nucleotide sequence of ovine xenin revealed a high degree (97.9%) of sequence homology of the sequence between sheep and cattle, and the amino acids sequence determined for ovine xenin coincided (100%) with that of other mammalian species. Real-time quantitative PCR for ovine xenin did not show regional difference in the mRNA expression ratio of xenin. In contrast to the real-time quantitative PCR results, anti-xenin positive cells were abundantly localized in the abomasal antrum ($P < 0.01$) and at a lesser amount in the duodenum, but no antixenin positive cells were observed in the other regions. Anti-xenin single-positive cells were in a majority in the abomasal antrum, whereas anti-xenin single-positive cells, and anti-GIP single-positive cells, and double-positive cells were even colocalized in the duodenum. These results suggest that abomasal antrum is a major source of xenin in the ovine gastrointestinal tract.

© 2020 Elsevier Inc. All rights reserved.

出典　doi: 10.1016/j.domaniend.2020.106523.
https://www.sciencedirect.com/science/article/abs/pii/S0739724020300904?via%3Dihub

最終責任者　Takenori Onaga (First Author and Corresponding Author)

動物と人の関係学（Animal Human Relations）

Takanori Kooriyama

Associate Professor

准教授　郡山　尚紀

Ⅰ．筆頭または責任著者　＜First or Corresponding Author＞

1） Contour variations and acoustic characteristics of whistle sounds emitted by Pacific white-sided dolphins in shallow coastal waters of the Sea of Japan, Marin Matsushiro, Misato Nakamura, Yuko Cyayahara, **Takanori Kooriyama**, *Marine Mammal Science* 2021;1-17.

2） Salivary stress markers in dogs: Potential markers of acute stress, **Takanori Kooriyama**, Niwako Ogata, *Research in Veterinary Science* 2021 141 48-55.

3） Salivary chromogranin a (CgA) response to the noradrenaline transporter blocker atomoxetine in dogs, **Takanori Kooriyama**, Abhijit Mukhopadhyay, George E. Moore, Niwako Ogata, *Animals* 2021 11(10).

4） Cortisol Changes in Bottlenose Dolphins in the Dolphin Interactive Program, Marin MATSUSHIRO, Hirofumi KURONO, Keiko YAMAMOTO, **Takanori KOORIYAMA**, *Japanese Journal of Veterinary Research* 2021 69(2), 99-108.

5） Survey of ophthalmic disorders among captive pinnipeds in Japan. Misato Nakamura, Marin Matsushiro, Masatoshi Tsunokawa, Seiya Maehara, **Takanori Kooriyama**, *The Journal of veterinary medical science* 2021 83(7) 1075-1080.

Ⅱ．その他＜Others＞

1） Prevalence of antibodies against human respiratory viruses potentially involving anthropozoonoses in wild bonobos. Tomoyuki Yoshida, Hiroyuki Takemoto, Tetsuya Sakamaki, Nahoko Tokuyama, John Hart, Terese Hart, Jef Dupain, Amy Cobden, Mbangi Mulavwa, Chie Hashimoto, Mina Isaji, Akihisa Kaneko, Yuki Enomoto, Eiji Sato, **Takanori Kooriyama**, Takako Miyabe-Nishiwaki, Juri Suzuki, Akatsuki Saito, Takeshi Furuichi, Hirofumi Akari, *Primates* 2021 62:897-903.

2） Female chimpanzees giving first birth in their natal group in Mahale: Attention to incest between brothers and sisters, Takuya Matsumoto, Shunkichi

Hanamura, **Takanori Kooriyama**, Takashi Hayakawa", Eiji Inoue. *Primates* 2021 62(2) 279-287.

ARTICLE

Marine Mammal Science

Contour variations and acoustic characteristics of whistle sounds emitted by Pacific white-sided dolphins in shallow coastal waters of the Sea of Japan

Marin Matsushiro | Misato Nakamura | Yuko Chayahara | Takanori Kooriyama

Laboratory of Companion Animal Behavior and Wildlife Ecology, Department of Veterinary Science, School of Veterinary Medicine, Rakuno Gakuen University, 582, Bunkyodai-Midori, Ebetsu, Hokkaido, Japan

Correspondence
Takanori Kooriyama, Laboratory of Companion Animal Behavior and Wildlife Ecology, Department of Veterinary Science, School of Veterinary Medicine, Rakuno Gakuen University, 582, Bunkyodai-Midori, Ebetsu, Hokkaido, Japan.
Email: kooriyam@rakuno.ac.jp

Funding information
Sasakawa Scientific Research Grant, Grant/Award Number: 2019-4100

Abstract

Pacific white-sided dolphins, *Lagenorhynchus obliquidens* (PWSDs), migrate along the coast of Japan. PWSDs rarely emit whistles, instead utilizing pulses, unlike many other delphinid species that frequently emit whistle sounds. In the present study, we aimed to clarify the acoustic characteristics and repertoire of the whistle of PWSDs, which have not been reported so far. We analyzed PWSD whistle sound systems (e.g., acoustic parameters and contours) during boat surveys and using passive acoustic monitoring in shallow coastal waters in the northern Sea of Japan. PWSDs in Shakotan rarely emitted whistles, while the burst pulse frequently was as reported in previous studies in other waters. The PWSD whistle vocalization rates were higher during traveling than during foraging. The frequency and duration of their whistles did not appear to change between behaviors. Although complex multiloop whistles were not recorded, whistle contours were classified into seven types. Whistles are often recorded intensively in a short period as a sequence or bout. Considering the extremely low whistle vocalization rates, dolphins may choose whistles instead of pulsed sounds in limited contexts. Our results shed light on the differences in whistle sound usage within odontocete species.

出典　DOI: 10.1111/mms.12892　https://doi.org/10.1111/mms.12892
責任著者　Takanori Kooriyama (Corresponding Author)

Contents lists available at ScienceDirect

Research in Veterinary Science

journal homepage: www.elsevier.com/locate/rvsc

Salivary stress markers in dogs: Potential markers of acute stress

Takanori Kooriyama [a], Niwako Ogata [b,*]

[a] Department of Veterinary Science, School of Veterinary Medicine, Rakuno Gakuen University,Hokkaido, Japan
[b] Department of Veterinary Clinical Sciences, College of Veterinary Medicine, Purdue University, West Lafayette, IN, USA

ARTICLE INFO

Keywords:
Stress
Dogs
Biomarkers
Saliva
SAM axis

ABSTRACT

Along with the growing awareness of psychological stress in companion animals, several treatments have become available to address fear- and anxiety-related behaviors in dogs. To detect vulnerable individuals and apply effective treatments, reliable evaluations that can quantify individual stress responses are in high demand. To develop measurable variables that have clinical applications, more investigations are needed to increase our knowledge. When stress responses are activated by the sympathetic-adrenal-medullary (SAM) and hypothalamic-pituitary-adrenal (HPA) axes, the immune system is also activated. Although the peripheral cortisol level is commonly used as a stress biomarker, it primarily reflects the HPA axis response and does not sufficiently reflect the complexity of the stress response. Thus, this review primarily focuses on the available salivary biomarkers that mainly reflect the acute stress response through the activity of the SAM axis and the immune system in dogs. We hope that this review will promote the validation of these biomarkers in dogs and aid in the development of future studies to evaluate stress responses in dogs.

1. Introduction

In the last decade, psychological health in companion animals has gained growing attention from veterinary professions and pet owners. Survey-based studies in previous literature have shown the high prevalence of behavior problems in pet dogs, especially fear and anxiety-related problems. Although survey questions and categories varied between studies, the overall prevalence of fear and anxiety-related problems was within the range of 20–50% in dogs regardless of geographic location (e.g., Asia, Europe or the USA) (Tiira et al., 2016; Kuruchi et al., 2017; Dinwoodie et al., 2019; Salonen et al., 2020). Fear and anxiety-related problems are triggered by varied types of stressors (e.g., loud noises, veterinary clinic visits, or environmental stimuli), resulting in acute (within a single day) or chronic (across multiple days) stress responses in dogs (Beerda et al., 1999; Korpivaara et al., 2017; Riemer et al., 2021). Several treatment plans, including supplements and medications, are now available based on the types of stress responses (van Haaften et al., 2020). However, assessing the level of anxiety and the effective response of these treatment plans is still challenging, partially because gauging the individual response is not yet standardized. Quantitative data that allow us to evaluate the intensity of the individual stress response and to assess the treatment outcome remain scarce. Research that helps to develop measurable variables that have clinical applications is in high demand in relevant fields such as veterinary medicine and animal welfare in companion animals.

When an animal encounters stressors, the paraventricular nucleus of the hypothalamus (PVN) and the locus coeruleus (LC) are activated to generate the rapid sympathetic adrenomedullar system (SAM), which leads to the release of catecholamines from the adrenal medulla (e.g., noradrenaline and adrenaline), and sympathetic nerves are activated to prepare the body for fight or flight reactions. SAM also activates the immune system as a part of a defense mechanism against physical injury and pathogens under stress. The autonomic nervous response is immediate, as it acts as an alarm to the body; it will wane within 30–60 min, along with shifting the activation of the hypothalamus-pituitary-adrenal (HPA) axis, which results in an elevation of glucocorticoids. The stressor also activates the immune system by reducing the inhibitory effects of glucocorticoid actions or by stimulating the immune system via the HPA axis (Cohen et al., 2007; Wohleb et al., 2015). Therefore, while animals can usually recover from acute sickness or injury, when the stress becomes sustained, especially at low and mild levels, it causes chronic inflammatory disorders (Silverman and Sternberg, 2012). Thus, measuring markers of the immune system in peripheral samples is another way to assess the individual chronic stress response.

According to the literature regarding the stress response evaluation in dogs, behavioral observations, such as vocalization, elimination,

出典　Doi: 10.1016/j.rvsc.2021.10.009　https://doi.org/10.1016/j.rvsc.2021.10.009
筆頭著者　Takanori Kooriyam (First Author)

animals

MDPI

Article

Salivary Chromogranin A (CgA) Response to the Noradrenaline Transporter Blocker Atomoxetine in Dogs

Takanori Kooriyama [1,2], Abhijit Mukhopadhyay [2], George E. Moore [3] and Niwako Ogata [2,*]

[1] Department of Veterinary Science, School of Veterinary Medicine, Rakuno Gakuen University, Ebetsu 069-8501, Hokkaido, Japan; kooriyam@rakuno.ac.jp
[2] Department of Veterinary Clinical Sciences, College of Veterinary Medicine, Purdue University, West Lafayette, IN 47907, USA; mukhopad@purdue.edu
[3] Department of Veterinary Administration, College of Veterinary Medicine, Purdue University, West Lafayette, IN 47907, USA; gemoore@purdue.edu
* Correspondence: nogata@purdue.edu

Simple Summary: Cortisol in peripheral samples (e.g., blood, saliva or hair) is commonly used for the assessment of stress in dogs. It primarily reflects the hypothalamus–pituitary–adrenal (HPA) axis responses and serves as a marker to indicate the rapid response via the sympathetic adrenomedullar system (SAM), which has not yet been well studied in dogs. This study aimed to evaluate chromogranin A (CgA), a known SAM activation marker, in saliva samples from laboratory dogs when the SAM response was pharmacologically induced. A selective noradrenaline transporter blocker, atomoxetine, was orally administered without causing any adverse responses in dogs to see if it increases salivary CgA. Three treatment groups were designed to determine whether CgA was increased only in the treatment with atomoxetine compared to a placebo or with pre-administration of dexmedetomidine followed by atomoxetine. Dexmedetomidine was included in the study because it is a selective alpha-2 adrenoreceptor agonist that inhibits central noradrenaline activity. The results were found to be consistent with our hypothesis and suggest that salivary CgA correlates with central noradrenaline activity, indicating that it can be a useful marker to assess SAM activity in dogs.

Abstract: Since salivary chromogranin A (CgA) is one of the known sympathetic adrenomedullar system (SAM) stress markers in humans and pigs, this study aimed to investigate whether salivary CgA in dogs reflects SAM activation. Our hypothesis was that salivary CgA would increase when central noradrenaline was pharmacologically induced. A selective noradrenaline transporter blocker, atomoxetine, was orally administered without causing any aversive responses in nine laboratory dogs to see if it would increase salivary CgA. Three treatment groups (i.e., atomoxetine, placebo, and pre-administration of a selective alpha-2 adrenoreceptor agonist (dexmedetomidine) followed by atomoxetine) were prepared with a randomized crossover design. Saliva sample collection, heart rate measurement and behavior observation were performed at Time 0 (baseline) and at 30, 60, 90 and 150 min after each treatment administration. The results demonstrated that salivary CgA significantly increased at 90 min in the atomoxetine treatment ($p < 0.05$), whereas it was not observed in the other two treatments. The present study showed that salivary CgA was increased by atomoxetine-induced SAM activation. However, this increase was blocked if dexmedetomidine was pre-administered. Overall, the results indicate that salivary CgA is a potential candidate for SAM-mediated stress markers in dogs. Further study to determine the dynamics of salivary CgA will be helpful in its practical use.

Keywords: chromogranin A (CgA); cortisol; dog; hypothalamus–pituitary–adrenal (HPA); salivary stress marker; sympathetic adrenomedullar system (SAM)

check for updates

Citation: Kooriyama, T.; Mukhopadhyay, A.; Moore, G.E.; Ogata, N. Salivary Chromogranin A (CgA) Response to the Noradrenaline Transporter Blocker Atomoxetine in Dogs. *Animals* **2021**, *11*, 2844. https://doi.org/10.3390/ani11102844

Academic Editor: Mandy Paterson

Received: 31 August 2021
Accepted: 28 September 2021
Published: 29 September 2021

Publisher's Note: MDPI stays neutral with regard to jurisdictional claims in published maps and institutional affiliations.

Copyright: © 2021 by the authors. Licensee MDPI, Basel, Switzerland. This article is an open access article distributed under the terms and conditions of the Creative Commons Attribution (CC BY) license (https://creativecommons.org/licenses/by/4.0/).

出典　DOI: 10.3390/ani11102844　https://doi.org/10.3390/ani11102844

筆頭著者　Takanori Kooriyama (First Author)

Japanese Journal of Veterinary Research 69(2): 99-108, 2021

JJVR

REGULAR PAPER Regional Study

Cortisol changes in bottlenose dolphins in the dolphin interactive program

Marin Matsushiro[1)], Hirofumi Kurono[1)], Keiko Yamamoto[2)] and Takanori Kooriyama[1,*)]

[1)] Laboratory of Companion animal behavior and Wildlife ecology, Department of Veterinary Science, School of Veterinary Medicine, Rakuno Gakuen University, 582, Bunkyodai-Midori, Ebetsu, Hokkaido, 069-8501, Japan
[2)] Okinawa Marine Research Center, 3425-2, Yamada, Onna-son, Kunigami-gun, Okinawa 904-0416, Japan

Received for publication, October 22, 2020; accepted, January 7, 2021

Abstract

Several kinds of animals are utilized in animal-assisted interventions (AAIs) for humans, which release stress and/or provide motivation for muscle movement. It is important to monitor AAI animals' stress levels to ensure their welfare. In the present study, we analyzed blood cortisol levels to evaluate the stress levels of Common bottlenose dolphin (*Tursiops truncatus*) in a dolphin interactive program (DIP). We sampled nine female dolphins that were used in the DIP in Motobu Genki village, Okinawa, Japan. Plasma cortisol levels were measured by ELISA, and the data were analyzed by comparing differences between seasons and before and after the DIPs on a given day. The average plasma cortisol level was 8.7±5.0 ng/ml and ranged from 1.6–29.3 ng/ml. Comparing before and after the DIP sessions on a given day, the average cortisol level of five dolphins decreased significantly. In comparison among seasons, average cortisol levels were significantly higher in the high visitor season than in the rising transition season (between the low and high visitor seasons) in two out of three animals. Regarding the falling transition season (between the high and low visitor seasons), two out of three animals tended to remain high in cortisol levels. From these results, we conclude that DIP induced little acute stress on dolphins. On the other hand, we showed the possibility of chronic stress in DIP-participating dolphins in the high visitor season. Further studies are needed to elucidate whether dolphins experience chronic stress by combining cortisol sampling with stress behavior monitoring.

Key Words: bottlenose dolphin, cortisol, dolphin interactive program

出典 DOI: 10.14943/jjvr.69.2.99 http://hdl.handle.net/2115/81814

責任著者 Takanori Kooriyama (Corresponding Author)

The Journal of Veterinary Medical Science

FULL PAPER
Wildlife Science

Survey of ophthalmic disorders among captive pinnipeds in Japan

Misato NAKAMURA[1)], Marin MATSUSHIRO[1)], Masatoshi TSUNOKAWA[2)], Seiya MAEHARA[3)] and Takanori KOORIYAMA[1)]*

[1)]Laboratory of Companion animal behavior and Wildlife ecology, Department of Veterinary Science, School of Veterinary Medicine, Rakuno Gakuen University, 582 Bunkyodai-Midori, Ebetsu, Hokkaido 069-8501, Japan
[2)]Otaru aquarium, 3-303 Shukutsu, Otaru-shi, Hokkaido 047-0047, Japan
[3)]Veterinary Ophthalmology, Department of Veterinary Medicine, Rakuno Gakuen University, 582 Bunkyodai-Midori, Ebetsu, Hokkaido 069-8501, Japan

ABSTRACT. Pinnipeds have evolved enlarged ocular bulbs to catch fish in the dark. However, their large protruding eyes are easily damaged, which increases the risk of blindness and death in these animals. In captivity, ophthalmic disorders, manifested as keratitis and cataracts, are common among pinnipeds. In this study, we investigated symptoms of ophthalmic disorders in pinniped species using a questionnaire distributed to 32 zoos and aquariums throughout Japan. We conducted this study in cooperation with the Japanese Association of Zoos and Aquariums. The survey included 295 pinnipeds from four otariid species, five phocid species, and one odobenid species. Of these, 43.1% of the pinnipeds had diseases affecting the lens, cornea, and/or other eye parts. Age was positively associated with lens disorders in California sea lions, South American sea lions, and spotted seals. Conflicts and public appearances were also associated with corneal and/or lens disorders in California sea lions. Treatments were evaluated as effective for corneal disorders and conjunctivitis. The results of this study indicate that ophthalmic disorders in pinnipeds are related to the conditions of their captive environment. Aquariums and zoos should be encouraged to share information regarding optimal maintenance practices to improve the living conditions of pinnipeds.

KEY WORDS: aquarium, eye disease, pinniped, survey, zoo

J. Vet. Med. Sci.
83(7): 1075–1080, 2021
doi: 10.1292/jvms.20-0329

Received: 1 June 2020
Accepted: 29 April 2021
Advanced Epub:
17 May 2021

Pinnipeds, which include over 30 species of phocids, otariids, and odobenids, live in the water for feeding and come up onto land and water surfaces to rest. Pinnipeds dive to various water depths for feeding. The normal depth depends on the species; dives to depths of 75 m are normal for California sea lions, whereas 21-m depths are normal for Stellar sea lions, with greater depths possible [15]. The eye functionality of pinnipeds has evolved for feeding under low-light, cold-temperature conditions in the water; thus, eyeball size in pinnipeds is three-fold that of humans, allowing them to collect light more efficiently. In general, the eyes of onshore mammals cannot adapt to underwater use. The refractive indices of the cornea and water are almost the same, and the lens should be round and dense for normal underwater vision [9, 11]. However, an animal with an underwater-adapted eye lens likely experiences near-sightedness on land due to the higher refractive index of the lens. To prevent this issue, the pinniped eye has a specific corneal structure. The eyes of California sea lions have a flat surface on the nasal side of the cornea that adjusts the refractive index to land or underwater conditions [13]. In addition, pinnipeds have a thermal system to warm the eyeballs to minimize retinal light sensitivity [14]. Thus, pinnipeds retain a sophisticated vision system both on land and underwater [9, 11]. Ophthalmic disorders (OpDs) in pinnipeds increase their risk of death, due to the inability to adequately hunt for fish. In the wild, 4.3% of gray seals had eye disease-related conditions in a population of 4,000 seals in the Gulf of St. Lawrence [10]. Captive animals housed in artificial conditions different from those in the wild may also be affected by OpDs. Colitz *et al.* reported that eye disorders were prevalent in captive pinnipeds in the Bahamas and United States, as well as otariid keratitis in animals housed in captivity in North America, the Bahamas, and Germany [1, 2]. However, similar surveys have not been conducted in zoos and aquariums in Japan. We conducted a large-scale survey of OpDs in pinniped species using a questionnaire distributed to zoos and aquariums throughout Japan.

出典　DOI: 10.1292/jvms.20-0329　https://doi.org/10.1292/jvms.20-0329
責任著者　Takanori Kooriyama (Corresponding Author)

Primates (2021) 62:897–903
https://doi.org/10.1007/s10329-021-00935-5

ORIGINAL ARTICLE

Prevalence of antibodies against human respiratory viruses potentially involving anthropozoonoses in wild bonobos

Tomoyuki Yoshida[1] · Hiroyuki Takemoto[1] · Tetsuya Sakamaki[1] · Nahoko Tokuyama[1] · John Hart[2] · Terese Hart[2] · Jef Dupain[3] · Amy Cobden[4] · Mbangi Mulavwa[5] · Chie Hashimoto[1] · Mina Isaji[1] · Akihisa Kaneko[1] · Yuki Enomoto[1] · Eiji Sato[1] · Takanori Kooriyama[6] · Takako Miyabe-Nishiwaki[1] · Juri Suzuki[1] · Akatsuki Saito[1] · Takeshi Furuichi[1] · Hirofumi Akari[1,7]

Received: 11 February 2021 / Accepted: 19 July 2021 / Published online: 2 August 2021
© Japan Monkey Centre 2021

Abstract
One of the current threats to the bonobo (*Pan paniscus*), a highly endangered ape species only found in the Democratic Republic of the Congo, are anthropozoonoses caused by human respiratory viruses. To date, epidemiological information regarding respiratory viral infections in bonobos is limited. In this study, we examined fecal immunoglobulin A antibodies against human respiratory viruses in bonobos, which may help estimating the viral prevalence. A substantial proportion of bonobos were positive for the antiviral antibodies, including those against parainfluenza virus, respiratory syncytial virus, influenza virus, rhinovirus, and mumps virus. The prevalence of the antibodies was found to depend on the viral species and bonobo populations, suggesting that the bonobos had been exposed to these respiratory viruses. These results may indicate the need for an epidemiological evidence-based action plan for the protection of bonobos from anthropozoonoses.

Keywords Bonobos · Chimpanzees · Anthropozoonoses · Epidemiology · Immunoglobulin A · Feces

出典　DOI: 10.1007/s10329-021-00935-5　https://doi.org/10.1007/s10329-021-00935-5
共著者　Takanori Kooriyama (Co-author)

Primates (2021) 62:279–287
https://doi.org/10.1007/s10329-020-00886-3

ORIGINAL ARTICLE

Female chimpanzees giving first birth in their natal group in Mahale: attention to incest between brothers and sisters

Takuya Matsumoto[1,2] · Shunkichi Hanamura[3] · Takanori Kooriyama[4] · Takashi Hayakawa[5,6] · Eiji Inoue[7]

Received: 29 May 2020 / Accepted: 16 December 2020 / Published online: 14 January 2021
© Japan Monkey Centre and Springer Japan KK, part of Springer Nature 2021

Abstract
Chimpanzee societies generally show male philopatry and female dispersal. However, demographic data on wild chimpanzee societies from long-term study sites have revealed that some females give birth in their natal group (i.e., "remaining females"). Here, we report two remaining females in the M group in Mahale, Tanzania, and compare their cases with previous reports to explore the social and ecological factors that lead to females remaining in their natal group. The results revealed that neither the social traits of the remaining females nor the ecological factors they experienced showed a coherent trend. However, we found multiple, non-mutually exclusive potential factors that may influence the decision by females to remain in their natal group: a decrease in indirect feeding competition, support from mothers or allomothers in the care of offspring and in aggressive interactions with other individuals, close relationships with the other remaining females, and a short adolescent infertility period. Additionally, we observed a natal female copulating with her older brother, which was the first observation of brother–sister incest in Mahale. Although DNA analysis revealed that her infant was not a product of inbreeding, the pair copulated frequently in the latter half of her estrus period, suggesting that they did not avoid incest behaviorally to avoid inbreeding. Furthermore, there was no hard evidence that the remaining female avoided mating with her maternal brother, suggesting that incest avoidance may not be a proximate factor responsible for female dispersal.

Keywords Female dispersal pattern · Adolescent infertility · Incest breeding · Social structure · Paternity identification

出典　DOI: 10.1007/s1032 9-020-00886-3.　https://doi.org/10.1007/s10329-020-00886-3
共著者　Takanori Kooriyama (Co-author)

動物医療学（Animal Clinical Science）

Sae Tsubakishita

Associate Professor

准教授　椿下　早絵

Ⅰ．筆頭または責任著者　＜First or Corresponding Author＞

Ⅱ．その他＜Others＞

1）Functional assessment of the gluteus medius, cranial part of the biceps femoris, and vastus lateralis in Beagle dogs based on a novel gait phase classification.
Yoshikawa K, **Tsubakishita S**, Sano T, Ino T, Miyasaka T, Kitazawa T.
J. Vet. Med. Sci. 83(1): 116-124. 2021. doi: 10.1292/jvms.20-0127

The Journal of Veterinary Medical Science

FULL PAPER
Surgery

Functional assessment of the gluteus medius, cranial part of the biceps femoris, and vastus lateralis in Beagle dogs based on a novel gait phase classification

Kazuyuki YOSHIKAWA[1)], Sae TSUBAKISHITA[2)], Tadashi SANO[1,2)], Takumi INO[3)], Tomoya MIYASAKA[3)] and Takio KITAZAWA[1,2)]*

[1)]Graduate School of Veterinary Medicine, Rakuno Gakuen University, Hokkaido 069-8501, Japan
[2)]Department of Veterinary Sciences, School of Veterinary Medicine, Rakuno Gakuen University, Hokkaido 069-8501, Japan
[3)]Department of Physical Therapy, School of Health Sciences, Hokkaido University of Science, Hokkaido 006-8585, Japan

ABSTRACT. In humans, walking analysis based on the gait phase classification has been used for interpretation of functional roles of different movements occurring at individual joints, and it is useful for establishing a rehabilitation plan. However, there have been few reports on canine gait phase classification, and this is one of the reasons for preventing progress in canine rehabilitation. In this study, we determined phases of the canine gait cycle (GC) on the basis of the phase classification for human gait. The canine GC was able to be divided into initial contact (IC) and the following 5 phases: loading response (LR), middle stance (MidSt), pre-swing (PSw), early swing (ESw), and late swing (LSw). Next, the hind limb joint angles of the hip, stifle and tarsal joints and results of surface electromyography of the gluteus medius (GM), cranial part of the biceps femoris (CBF) and vastus lateralis (VL) muscles in relation to the gait phases were analyzed. The activities of three muscles showed similar changes during walking. The muscle activities were high in the LR phase and then declined and reached a minimum in the PSw phase, but they increased and reached a peak in the LSw phase, which was followed by the LR phase. In conclusion, the multiphasic canine GC was developed by modification of the human model, and the GC phase-related changes in the muscle activity and joint angles suggested the functions of GM, CBF and VL muscles in walking.

KEY WORDS: dog, gait analysis, gait phase classification, rehabilitation, surface electromyography

J. Vet. Med. Sci.
83(1): 116–124, 2021
doi: 10.1292/jvms.20-0127

Received: 6 March 2020
Accepted: 28 October 2020
Advanced Epub:
23 November 2020

出典　doi: 10.1292/jvms.20-0127.
https://www.jstage.jst.go.jp/article/jvms/advpub/0/advpub_20-0127/_article

最終責任者　Takio Kitazawa (Corresponding Author)

動物と人の関係学（Animal Human Relations）

Jun Noda

Associate Professor

准教授　能田　淳

Ⅰ．筆頭または責任著者　＜First or Corresponding Author＞

1）Air pollution and airborne infection with mycobacterial bioaerosols: a potential attribution of soot

Noda J, Tomizawa S, Takahashi K, Morimoto K, Mitarai, S.

Int J Environ Sci Technol. 1-10. 2021. doi:10.1007/s13762-021-03203-7.

Ⅱ．その他＜Others＞

1) Relationship between the Microbiome and Indoor Temperature/Humidity in a Traditional Japanese House with a Thatched Roof in Kyoto, Japan Japan.

Kokubo M, Fujiyoshi S, Ogura D, Nakajima M, Fujieda A, **Noda J**, Maruyama F.

Diversity. 13(10):475. 2021. doi:10.3390/d13100475.

2) Shape relatedness between geographic populations of Culex tritaeniorhynchus, the primary vector of Japanese encephalitis virus: A landmark study.

Morales Vargas R, Tsunoda T, Noda J, Bousses P, Nguyen TY, Hasebe F, Dujardin, JP.

Infect Genet Evol. 90:104764. 2021. doi: 10.1016/j.meegid.2021.104764.

International Journal of Environmental Science and Technology
https://doi.org/10.1007/s13762-021-03203-7

ORIGINAL PAPER

Air pollution and airborne infection with mycobacterial bioaerosols: a potential attribution of soot

J. Noda[1] · S. Tomizawa[1] · K. Takahashi[1] · K. Morimoto[2,3] · S. Mitarai[3]

Received: 30 May 2020 / Revised: 10 January 2021 / Accepted: 28 January 2021
© Islamic Azad University (IAU) 2021

Abstract
Atmospheric pollutants are hypothesized to enhance the viability of airborne microbes by preventing them from degradation processes, thereby enhancing their atmospheric survival. In this study, *Mycobacterium smegmatis* is used as a model airborne bacteria, and different amounts of soot particles are employed as model air pollutants. The toxic effects of soot on aerosolized *M. smegmatis* are first evaluated and excluded by introducing them separately into a chamber, being sampled on a filter, and then cultured and counted. Secondly, the bacteria–soot mixture is exposed to UV with different durations and then cultured for bacterial viability evaluations. The results show that under UV exposure, the survival rates of the low-, medium-, and high-soot groups are 1.1 (±0.8) %, 70.9 (±4.3) %, and 61.0 (±17.6) %, respectively. This evidence significantly enhanced survival rates by soot at all UV exposures, though the combinations of UV exposure and soot amounts revealed a changing pattern of survival rates. The possible influence by direct and indirect effects of UV-damaging mechanisms is proposed. This study indicates the soot-induced survival rate enhancements of *M. smegmatis* under UV stress conditions, representing the possible relations between air pollution and the extended pathogenic viability and, therefore, increased airborne infection probability.

Keywords Airborne pathogen · Combustion-related pollutants · Non-tuberculosis mycobacterium · Ultraviolet stress

出典　doi:10.1007/s13762-021-03203-7
https://link.springer.com/article/10.1007/s13762-021-03203-7
最終責任者 Jun Noda (Corresponding Author)

diversity

MDPI

Article

Relationship between the Microbiome and Indoor Temperature/Humidity in a Traditional Japanese House with a Thatched Roof in Kyoto, Japan

Makoto Kokubo [1,*], So Fujiyoshi [2,3,*], Daisuke Ogura [1,3,*], Makiko Nakajima [3,4], Ayako Fujieda [3,5], Jun Noda [3,6] and Fumito Maruyama [2,3,*]

[1] Department of Architecture and Architectural Engineering, Graduate School of Engineering, Kyoto University, Kyotodaigaku-Katsura, Nishikyo-ku, Kyoto 615-8540, Japan
[2] Office of Industry-Academia-Government and Community Collaboration, Hiroshima University, 1-3-2 Kagamiyama, Higashi-Hiroshima City, Hiroshima 739-8511, Japan
[3] Center for HOlobiome and Built Environment (CHOBE), Hiroshima University, Hiroshima 739-8511, Japan; m.nakajima.5k@cc.it-hiroshima.ac.jp (M.N.); afujieda@kyoto-seika.ac.jp (A.F.); jnoda@rakuno.ac.jp (J.N.)
[4] Department of Architectural Engineering, Faculty of Engineering, Hiroshima Institute of Technology, 2-1-1 Miyake, Saeki-ku, Hiroshima 731-5193, Japan
[5] Faculty of Global Culture, Kyoto Seika University, 137 Iwakura Kinocho, Sakyo-ku, Kyoto 606-8588, Japan
[6] Laboratory of Environmental Health Sciences, Department of Veterinary Science, School of Veterinary Medicine, Rakuno Gakuen University, Ebetsu, Hokkaido 069-8501, Japan
* Correspondence: kokubo.makoto.43w@st.kyoto-u.ac.jp (M.K.); fujiyoshi.so.62w@kyoto-u.jp (S.F.); ogurad@archi.kyoto-u.ac.jp (D.O.); fumito@hiroshima-u.ac.jp (F.M.); Tel.: +81-75-383-2918 (D.O.); +81-82-424-7048 (F.M.)

check for updates

Citation: Kokubo, M.; Fujiyoshi, S.; Ogura, D.; Nakajima, M.; Fujieda, A.; Noda, J.; Maruyama, F. Relationship between the Microbiome and Indoor Temperature/Humidity in a Traditional Japanese House with a Thatched Roof in Kyoto, Japan. *Diversity* **2021**, *13*, 475. https://doi.org/10.3390/d13100475

Academic Editor: Michael Wink

Received: 30 August 2021
Accepted: 24 September 2021
Published: 28 September 2021

Publisher's Note: MDPI stays neutral with regard to jurisdictional claims in published maps and institutional affiliations.

Abstract: In our living environment, there are various microorganisms that are thought to affect human health. It is expected that excessive microbial suppression can have a negative effect on human health and that the appropriate control of the microbiome is beneficial to health. To understand how the physical environment, such as temperature and relative humidity, or housing itself affects the microbiome in a rural house, we measured temperature and humidity and collected microbial samples in a traditional Japanese house with a thatched roof. The relative humidity of outdoor air was over 60% most of the day throughout the year. Indoor and outdoor air temperature and humidity were closer to each other in summer than in winter. The DNA concentration of indoor surfaces correlated with the relative humidity, especially with the lowest annual relative humidity. In the thatched roof, outside surface relative humidity often reached 100%, and the occurrence of condensation can affect the DNA concentrations. A high percentage of archaea were detected in the house, which is not a common characteristic in houses. In addition, the microbial community was similar outdoors and indoors or in each room. These characteristics reflect the occupants' behaviour, including opening the windows and partitions in summer. In the future, it will be necessary to conduct continuous surveys in various houses, including traditional and modern houses, in Japan.

Keywords: microbiome; relative humidity; temperature; building environment; indoor environment; thatched roof

出典　doi: 10.3390/d13100475
https://www.mdpi.com/1424-2818/13/10/475

最終責任者　Kokubo Makoto, Fujiyoshi So, Ogura Daisuke, and Maruyama Fumito (Corresponding Authors)

Infection, Genetics and Evolution 90 (2021) 104764

Contents lists available at ScienceDirect

Infection, Genetics and Evolution

journal homepage: www.elsevier.com/locate/meegid

Research paper

Shape relatedness between geographic populations of *Culex tritaeniorhynchus*, the primary vector of Japanese encephalitis virus: A landmark study

R. Morales Vargas [a], T. Tsunoda [b], J. Noda [c], P. Bousses [d], T.Y. Nguyen [e], F. Hasebe [f], J. P. Dujardin [g,*]

[a] Department of Medical Entomology, Faculty of Tropical Medicine, Mahidol University, Bangkok 10400, Thailand
[b] Laboratory of Medical Entomology, Department of Vector Ecology and Environment, Institute of Tropical Medicine, Nagasaki University, 1-12-4 Sakamoto, Nagasaki 852-8523, Japan
[c] Laboratory of Environmental Health Sciences, Division of Health and Environmental Sciences, School of Veterinary Medicine, Rakuno Gakuen University, Ebetsu, Hokkaido 069-8501, Japan
[d] IRD, UMR MIVEGEC IRD, CNRS, University of Montpellier, F-34398 Montpellier, France
[e] Department of Medical Entomology and Zoology, National Institute of Hygiene and Epidemiology, 1 Yersin street, Hai Ba Trung district, Hanoi, Viet Nam
[f] Vietnam Research Station, Institute of Tropical Medicine, Nagasaki University, 1-12-4 Sakamoto, Nagasaki 852-8523, Japan
[g] IRD, UMR INTERTRYP IRD, CIRAD, University of Montpellier, F-34398 Montpellier, France

ARTICLE INFO

Keywords:
Culex tritaeniorhynchus
Japan
Vietnam
Thailand
La Reunion
Geometric morphometrics
Winds

ABSTRACT

Background: Japanese encephalitis is a severe disease of acute encephalitis, with children and the elderly primarily affected, and with mortality rates reaching over 25%. The virus is transmitted mainly by species of the *Culex (Culex) vishnui* subgroup, primarily the widely spread *Cx. tritaeniorhynchus* Giles. The latter is known as a highly migratory mosquito which moves with airflow over large distances. We explored the geometric variation of the wing venation among distant areas of its geographic distribution. Our working hypothesis was that shape variation across geography could reveal known past and present migratory routes.

Materials methods: We compared the wing venation geometry of 236 female *Culex tritaeniorhynchus* from different locations in the Madagascan (La Reunion), Oriental (Thailand, Vietnam) and Palearctic (Japan) regions. To ascertain the taxonomic signal of the wing venation we also used two species as relative outgroups, *Cx. whitmorei* and *Cx. brevipalpis*.

Results: In spite of an increasing morphometric variation as expected with larger geographic dispersion, our *Cx. tritaeniorhynchus* samples were clustered as a single species when considered relative to other *Culex* species. The relationships between geographic sites of *Cx. tritaeniorhynchus* globally conformed with an isolation by distance model. The shape homogeneity of our Palearctic samples (Japan) contrasted with some heterogeneity observed in the Oriental region (Thailand, Vietnam), and could be related to the different regimes of wind trajectories in these regions.

Conclusion: The average shape variation of *Culex tritaeniorhynchus* disclosed a separation between Madagascan, Oriental and Palearctic regions in accordance with geography. The wing venation not only could reflect geography, it also contained a clear taxonomic signal separating three *Culex* species. Within *Cx. tritaeniorhynchus*, a contrasting pattern of shape variation between the Palearctic and the Oriental regions is tentatively explained by the influence of wind trajectories.

出典　doi: 10.1016/j.meegid.2021.104764.
https://www.sciencedirect.com/science/article/pii/S1567134821000617?via%3Dihub

最終責任者　Dujardin, Jean Pierre (Corresponding Author)

動物生命科学（Animal Life Science）

Taku Miyasho

Lecturer

講師　宮庄　拓

Ⅰ．筆頭または責任著者　＜First or Corresponding Author＞

1) Irisin/FNDC5: A participant in camel metabolism.
Kirat D, Hamada M, Moustafa A, **Miyasho T**.
Saudi J Biol Sci. 2021; **28**(1): 693-706.
doi: 10.1016/j.sjbs.2020.10.061.

Ⅱ．その他　＜Others＞

1) Validation Study of Fibrinogen and Albumin Score in Esophageal Cancer Patients Who Underwent Esophagectomy: Multicenter Prospective Cohort Study.
Matsuda S, Takeuchi H, Kawakubo H, Takemura R, Maeda Y, Hirata Y, Kaburagi T, Egawa T, Nishi T, Ogura M, **Miyasho T**, Okamura A, Mayanagi S, Fukuda K, Nakamura R, Irino T, Wada N, Kitagawa Y.
Ann Surg Oncol. 2021; **28**(2): 774-784.
doi: 10.1245/s10434-020-08958-w.

2) Monitoring the tissue perfusion during hemorrhagic shock and resuscitation: tissue-to-arterial carbon dioxide partial pressure gradient in a pig model.
Endo Y, Hirokawa T, **Miyasho T**, Takegawa R, Shinozaki K, Rolston DM, Becker LB, Hayashida K.
J Transl Med. 2021; **19**(1): 390.
doi: 10.1186/s12967-021-03060-5.

3) Testicular induced corticosterone synthesis in male rats under fasting stress.
Maeda N, Fujiki J, Hasegawa Y, Ieko T, **Miyasho T**, Iwasaki T, Yokota H.
Steroids. 2021; **177**: 108947.
doi: 10.1016/j.steroids.2021.108947.

Saudi Journal of Biological Sciences 28 (2021) 693–706

Contents lists available at ScienceDirect

Saudi Journal of Biological Sciences

journal homepage: www.sciencedirect.com

Original article

Irisin/FNDC5: A participant in camel metabolism

Doaa Kirat [a], Mohamed Hamada [a], Amira Moustafa [a], Taku Miyasho [b,*]

[a] Department of Physiology, Faculty of Veterinary Medicine, Zagazig University, Zagazig, Egypt
[b] Laboratory of Animal Biological Responses, Department of Veterinary Medicine, Rakuno Gakuen University, Ebetsu, Hokkaido, Japan

ARTICLE INFO

Article history:
Received 27 August 2020
Revised 26 October 2020
Accepted 27 October 2020
Available online 5 November 2020

Keywords:
PGC-1α
Glucose
Insulin
Leptin
Exercise

ABSTRACT

The quantification, localization, production, function, and regulation of irisin/FNDC5 in camel species have not been previously studied. The objective of this study was to detect the irisin content in Arabian camel blood and tissues and study the gene expression of FNDC5 and PGC-1α in camel skeletal muscles and white adipose tissue depots under basal conditions. To monitor if exercise influences blood and tissue irisin protein levels as well as FNDC5 and PGC-1α gene expression levels, we analyzed irisin concentrations in the serum, skeletal muscles (soleus and gastrocnemius), and white adipose tissues (hump, subcutaneous, visceral, epididymal, and perirenal) in both control (n = 6) and exercised group (n = 6) using ELISA and determined the cellular localization of irisin/FNDC5 and the mRNA levels of FNDC5 and PGC-1α in skeletal muscles and adipose tissues via immunohistochemistry and real-time PCR, respectively. The possible regulatory roles of exercise on some hormones and metabolites as well as the detection of links between serum irisin and other circulating hormones (insulin, leptin, and cortisol) and metabolites (glucose, free fatty acids, triglycerides, and ATP) were explored for the first time in camels. Our results indicated that exercise induces tissue-specific regulation of the camel irisin, FNDC5, and PGC-1α levels, which subsequently regulates the circulating irisin level. Significant associations were detected between the levels of irisin/FNDC5/PGC-1α in camels and the metabolic and hormonal responses to exercise. Our study suggested that irisin regulates, or is regulated by, glucose, FFA, insulin, leptin, and cortisol in camels. The novel results of the present study will serve as baseline data for camels.
© 2020 The Authors. Published by Elsevier B.V. on behalf of King Saud University. This is an open access article under the CC BY-NC-ND license (http://creativecommons.org/licenses/by-nc-nd/4.0/).

出典　doi: 10.1016/j.sjbs.2020.10.061.
https://www.sciencedirect.com/science/article/pii/S1319562X20305477?via%3Dihub
最終責任者　Taku Miyasho (Corresponding Author)

Ann Surg Oncol
https://doi.org/10.1245/s10434-020-08958-w

Annals of
SURGICAL ONCOLOGY
OFFICIAL JOURNAL OF THE SOCIETY OF SURGICAL ONCOLOGY

ORIGINAL ARTICLE – GASTROINTESTINAL ONCOLOGY

Validation Study of Fibrinogen and Albumin Score in Esophageal Cancer Patients Who Underwent Esophagectomy: Multicenter Prospective Cohort Study

Satoru Matsuda, MD, PhD[1], Hiroya Takeuchi, MD, PhD[1,2], Hirofumi Kawakubo, MD, PhD[1], Ryo Takemura, MD, PhD[3], Yusuke Maeda, MD[1], Yuki Hirata, MD[1,4], Takuji Kaburagi, MD, PhD[5], Tomohisa Egawa, MD, PhD[4], Tomohiko Nishi, MD, PhD[5], Masaharu Ogura, MD, PhD[6], Taku Miyasho, PhD[7], Akihiko Okamura, MD, PhD[1], Shuhei Mayanagi, MD, PhD[1], Kazumasa Fukuda, PhD[1], Rieko Nakamura, MD, PhD[1], Tomoyuki Irino, MD, PhD[1], Norihito Wada, MD, PhD[1], and Yuko Kitagawa, MD, PhD[1]

[1]Department of Surgery, Keio University School of Medicine, Tokyo, Japan; [2]Department of Surgery, Hamamatsu University School of Medicine, Shizuoka, Japan; [3]Biostatistics Unit, Clinical and Translational Research Center, Keio University Hospital, Tokyo, Japan; [4]Department of Surgery, Saiseikai Yokohamashi Tobu Hospital, Yokohama, Japan; [5]Department of Surgery, Keiyu Hospital, Yokohama, Japan; [6]Department of Surgery, Tokyo Dental College Ichikawa General Hospital, Ichikawa, Japan; [7]School of Veterinary Medicine, Rakuno Gakuen University, Ebetsu, Japan

ABSTRACT

Purpose. To arrange multidisciplinary treatment for esophageal cancer, a simple and accurate predictive marker for prognosis is required. The current multicenter prospective study aims to validate the prognostic significance of fibrinogen and albumin score (FA score) for esophageal cancer patients.

Patients and Methods. Patients who were planned to undergo surgical resection for esophageal cancer at four participating institutions were enrolled in this study. Patient background, clinicopathological factors, and blood concentration of plasma fibrinogen and albumin were collected. Patients with elevated fibrinogen and decreased albumin levels were allocated a score of 2; those with only one of these abnormalities were allocated a score of 1; and those with neither of these abnormalities were allocated a score of 0. Recurrence-free survival (RFS) and overall survival (OS) were evaluated as a primary endpoint.

Results. From four participating institutions, 133 patients were registered for the current analysis. The distribution of FA score of 0/1/2 was 84 (63%)/34 (26%)/15 (11%), respectively. In the analysis of primary endpoint, the preoperative FA score significantly classified RFS (FA score 1/2: HR 2.546, $p = 0.013/6.989$, $p < 0.001$) and OS (FA score 1/2: HR 2.756, $p = 0.010/6.970$, $p < 0.001$). We further evaluated the prognostic significance of FA score under stratification by pStage. As a result, with increasing FA score, RFS and OS were significantly worse in both pStage 0–I and II–IV groups.

Conclusions. The prognostic impact of preoperative FA score was confirmed for esophageal cancer patients in the current multicenter prospective trial. FA score can be considered to predict postoperative survival and rearrange the treatment strategy before esophagectomy.

Electronic supplementary material The online version of this article (https://doi.org/10.1245/s10434-020-08958-w) contains supplementary material, which is available to authorized users.

出典　doi: 10.1245/s10434-020-08958-w.
https://link.springer.com/article/10.1245%2Fs10434-020-08958-w

最終責任者　Hiroya Takeuchi (Corresponding Author)

Endo et al. J Transl Med (2021) 19:390
https://doi.org/10.1186/s12967-021-03060-5

Journal of Translational Medicine

RESEARCH Open Access

Monitoring the tissue perfusion during hemorrhagic shock and resuscitation: tissue-to-arterial carbon dioxide partial pressure gradient in a pig model

Yusuke Endo[1,2,3], Taku Hirokawa[2], Taku Miyasho[2], Ryosuke Takegawa[1,3], Koichiro Shinozaki[1,3,4], Daniel M. Rolston[3,4], Lance B. Becker[1,3,4] and Kei Hayashida[1,3*]

Abstract

Background: Despite much evidence supporting the monitoring of the divergence of transcutaneous partial pressure of carbon dioxide ($tcPCO_2$) from arterial partial pressure carbon dioxide ($artPCO_2$) as an indicator of the shock status, data are limited on the relationships of the gradient between $tcPCO_2$ and $artPCO_2$ ($tc\text{-}artPCO_2$) with the systemic oxygen metabolism and hemodynamic parameters. Our study aimed to test the hypothesis that $tc\text{-}artPCO_2$ can detect inadequate tissue perfusion during hemorrhagic shock and resuscitation.

Methods: This prospective animal study was performed using female pigs at a university-based experimental laboratory. Progressive massive hemorrhagic shock was induced in mechanically ventilated pigs by stepwise blood withdrawal. All animals were then resuscitated by transfusing the stored blood in stages. A transcutaneous monitor was attached to their ears to measure $tcPCO_2$. A pulmonary artery catheter (PAC) and pulse index continuous cardiac output (PICCO) were used to monitor cardiac output (CO) and several hemodynamic parameters. The relationships of $tc\text{-}artPCO_2$ with the study parameters and systemic oxygen delivery (DO_2) were analyzed.

Results: Hemorrhage and blood transfusion precisely impacted hemodynamic and laboratory data as expected. The $tc\text{-}artPCO_2$ level markedly increased as CO decreased. There were significant correlations of $tc\text{-}artPCO_2$ with DO_2 and COs (DO_2: $r = -0.83$, CO by PAC: $r = -0.79$; CO by PICCO: $r = -0.74$; all $P < 0.0001$). The critical level of oxygen delivery (DO_{2crit}) was 11.72 mL/kg/min according to transcutaneous partial pressure of oxygen (threshold of 30 mmHg). Receiver operating characteristic curve analyses revealed that the value of $tc\text{-}artPCO_2$ for discrimination of DO_{2crit} was highest with an area under the curve (AUC) of 0.94, followed by shock index (AUC = 0.78; $P < 0.04$ vs $tc\text{-}artPCO_2$), and lactate (AUC = 0.65; $P < 0.001$ vs $tc\text{-}artPCO_2$).

Conclusions: Our observations suggest the less-invasive $tc\text{-}artPCO_2$ monitoring can sensitively detect inadequate systemic oxygen supply during hemorrhagic shock. Further evaluations are required in different forms of shock in other large animal models and in humans to assess its usefulness, safety, and ability to predict outcomes in critical illnesses.

出典　doi: 10.1186/s12967-021-03060-5.
https://translational-medicine.biomedcentral.com/articles/10.1186/s12967-021-03060-5

最終責任者　Kei Hayashida (Corresponding Author)

Steroids 177 (2022) 108947

Contents lists available at ScienceDirect

Steroids

journal homepage: www.elsevier.com/locate/steroids

Testicular induced corticosterone synthesis in male rats under fasting stress

Naoyuki Maeda [a], Jumpei Fujiki [b], Yasuhiro Hasegawa [c], Takahiro Ieko [b], Taku Miyasho [d], Tomohito Iwasaki [c], Hiroshi Yokota [b,*]

[a] Laboratory of Meat Science and Technology, Department of Food Science and Human Wellness, Rakuno Gakuen University, Hokkaido 069-8501, Japan
[b] Laboratory of Veterinary Biochemistry, Department of Veterinary Medicine, Rakuno Gakuen University, Hokkaido 069-8501, Japan
[c] Laboratory of Applied Biochemistry, Department of Food Science and Human Wellness, Rakuno Gakuen University, Hokkaido 069-8501, Japan
[d] Laboratory of Animal Biological Responses, Department of Veterinary Science, Rakuno Gakuen University, Hokkaido 069-8501, Japan

ARTICLE INFO

Keywords:
Testicular steroidogenesis
Testosterone
Corticosterone
3β-hydroxysteroid dehydrogenase
Fasting stress

ABSTRACT

Testicular steroidogenesis is depressed by adrenal-secreted corticosterone (CORT) under stress. However, the mechanisms are not well understood. This study investigated the details of testicular steroidogenesis depression during fasting. Blood levels of adrenocorticotropic hormone secreted from the pituitary glands increased, but blood CORT was not changed in rats that fasted for 96 h, in spite of the rats being severely stressed. CORT in fasting adult male rats increased more than three times in the testis, but reduced testicular testosterone (T) and blood T levels to 5% and 2% of the control, respectively, was observed. The contents of T precursor (except PGN) were drastically reduced in the fasted-rat testes. Testicular CORT levels were elevated, but the enzymatic activity of cytochrome P45011β, which produces CORT, remained unchanged. The enzymatic activities of 3β-hydroxysteroid dehydrogenase (3β-HSD), mediating the conversion of pregnenolone to progesterone, decreased in the fasted-rat testes. Thus, fasting suppressed testicular steroidogenesis by affecting the enzyme activity of 3β-HSD in the testes and drastically reduced T and increased CORT synthesis. It can be considered that T synthesis involved in cell proliferation is suppressed due to lack of energy during fasting. Conversely, 11β-hydroxylase enzyme activity was induced and CORT synthesis is increased to cope with the fasting stress. Hence, it can be concluded that CORT synthesis in the testes plays a role in the local defense response.

出典　doi: 10.1016/j.steroids.2021.108947.
https://www.sciencedirect.com/science/article/abs/pii/S0039128X21001598?via%3Dihub

最終責任者　Hiroshi Yokota (Corresponding Author)

Published by Graduate School of Veterinary Medicine
Rakuno Gakuen University
582 Midorimachi - Bunkyodai
Ebetsu, Hokkaido 069-8501
Japan (**Not for Sale**)

March 2022

Tel.&Fax +81-11-388-4748
e-mail: r-kirisa@rakuno.ac.jp